

DOXYCYCLINE INDUCED TOXIC EPIDERMAL NECROLYSIS WITH A SINGLE DOSE: A CASE REPORT

Navin Patil,¹ Anjan Palikhey,¹ Chandra Mohan Sah,² Shanti Gurung,¹ Laxmi Shrestha,¹ Jharana Shrestha,³ Laxmi Pathak⁴

ABSTRACT

Toxic epidermal necrolysis (TEN) is a rare, life-threatening, severe epidermal necrolytic exanthematous vesicobullous usually drug-induced, mucocutaneous disease characterized by a widespread sloughing of the skin and mucosal surfaces. The most common drugs attributable to cause TEN are antibiotics, anti-inflammatory drugs, chemotherapeutic agents, antivirals, and anticonvulsants. The evolution is accompanied by local as well as general complications which can range from superinfections to multiple organ failure. It is of utmost importance that the treating physician promptly recognizes these conditions, withdraws the offending drug and follows the specific treatment protocol and guidelines (SCORTEN) which together would constitute for a better management and prognosis, with higher rates of survival, and a low prevalence of sequelae. We hereby report the first ever case in Nepal of doxycycline induced toxic epidermal necrolysis with a single dose at a tertiary care center.

KEYWORDS

Doxycycline, Toxic epidermal necrolysis (TEN), Vesicobullous.

1. Department of Pharmacology, Universal College of Medical Sciences, Bhairahawa
2. Department of Dermatology and Venereology, Universal College of Medical Sciences, Bhairahawa
3. Department of Biochemistry, Universal College of Medical Sciences, Bhairahawa
4. Department of Anesthesiology and Critical Care Medicine, Universal College of Medical Sciences, Bhairahawa

DOI: <https://doi.org/10.3126/jucms.v10i01.47251>

For Correspondence

Dr. Navin Patil
Department of Pharmacology
Universal College of Medical Sciences,
Bhairahawa, Nepal
Email: navin903@gmail.com

INTRODUCTION

Toxic epidermal necrolysis (TEN) is an acute-onset, potentially life-threatening, idiosyncratic mucocutaneous reaction, usually occurring with widespread full-thickness epidermal necrosis and sloughing of the skin and mucosa, involving internal and external surfaces.¹ A scald like appearance of the skin which usually affects the trunk, face and mucous membranes. Many different drugs can cause TEN, including anticonvulsants, nonsteroidal anti-inflammatory drugs, allopurinol, sulphonamides, and antibiotics.² It occurs sporadically, more commonly in adults. TEN is a fairly rare event with an average incidence proportion of one case per million populations/ year.³ An increased incidence has been observed in individuals with genetic variations, HLA-B 12.⁴

Controversy is part of the nature of art and creativity. Doxycycline has emerged as a very effective drug, especially for rickettsial infections, sexually transmitted infections, respiratory tract infections, specific bacterial infections, ophthalmic infections, anthrax, including inhalational anthrax (post-exposure), prophylaxis of malaria to name a few.⁵ However, doxycycline use has also sparked off a few controversies. Doxycycline has been found to be associated with a wide spectrum of adverse effects which include phototoxicity, hypersensitivity reactions, hemolytic anemia are the most common ones. Toxic epidermal necrolysis, on the other hand, is one of the rare presentations with doxycycline usage. Hence we hereby report the first ever case in Nepal of doxycycline induced TEN in a known allergic patient to tetracyclines with a single dose.

CASE REPORT

A 36-year-female hypertensive housewife presented to an emergency department of UCMS-TH on 30 July 2020 with chief complaints of fever and malaise for three days followed by itching and burning sensation and appearance of rashes and few fluid filled blisters mainly over trunk and limbs. She also noticed similar symptoms over genital area and lips.

A thorough history elicitation revealed that she was prescribed capsule doxycycline 100 mg which was given by a local medical practitioner for bleeding per rectum. She has been taking tablet amlodipine and atenolol combination for hypertension for the past two years for her hypertension.

Past history: A similar episode occurred a couple of years back after taking single dose of doxycycline. At that time diagnosis of severe toxic epidermal necrolysis was made and patient was managed conservatively at a tertiary level hospital in Kathmandu. Diagnosis was confirmed by histopathological examination report which revealed keratinocytes, necrosis in epidermis with vacuolar degeneration of basal cell and mild perivascular lymphocytes infiltrate in dermis. A brief investigation summary which were significant.

Table 1. Significant laboratory values

WBC	14400 / mm ³
CRP	+ ve
Serum procalcitonin	0.27 ng/ml (H)
URINE RE/ME	
Transparency	Turbid
Protein	++
Pus cells	6-8 / HPF
Epithelial cells	4-6 / HPF
Blood	++
Erythrocytes	165 (H)
STOOL	
Occult blood	+ ve

A final diagnosis was made which revealed toxic epidermal necrolysis was due to doxycycline. The patient was managed with IV fluids, antibiotics, analgesics, antihistamines, corticosteroids, vitamin supplements, albumin infusion was done during her hospital stay.

On local examination: At presentation there was dusky erythematous macules involving trunk, upper and lower limb, genitalia and lips. Some area showed scattered purpuric rash. Flaccid blisters were noted within large macules. Nikolsky sign was positive. Mucosal involvement of lips and genitalia was present. Vesicles continued developing within lesional skin. Approximately 40% of body surface area was involved.

Systemic examination

Vitals were stable. Cardiovascular and respiratory system examination was normal. On examination of gastrointestinal tract, hemorrhoids was detected. On blood investigation, full blood count revealed leukocytosis with neutrophilia. Other parameters were within normal limit. Histopathological examination was not done in view of previous report and clinical diagnosis. Patient was admitted with diagnosis of toxic epidermal necrolysis due to doxycycline with hypertension and was managed conservatively. Patient was discharged with good outcome on eighth day of admission with strict suggestion to avoid use of any drug in tetracycline group.

Table 2. Naranjo ADR probability scale⁶—items and score

Question	Yes	No	Don't know	
Are there previous conclusion reports on this reaction?	+1	0	0	+1
Did the adverse event appear after the suspect drug was administered?	+2	-1	0	+2
Did the AR improve when the drug was discontinued or a specific antagonist was administered?	+1	0	0	+1
Did the AR reappear when drug was re-administered?	+2	-1	0	0
Are there alternate causes [other than the drug] that could solely have caused the reaction?	-1	+2	0	+2
Did the reaction reappear when a placebo was given?	-1	+1	0	0
Was the drug detected in the blood [or other fluids] in a concentration known to be toxic?	+1	0	0	0
Was the reaction more severe when the dose was increased or less severe when the dose was decreased?	+1	0	0	0
Did the patient have a similar reaction to the same or similar drugs in any previous exposure?	+1	0	0	+1
Was the adverse event confirmed by objective evidence?	+1	0	0	+1
				8

Causality assessment was done using Naranjo's scale and a score of 8 indicates a probable causal relationship.

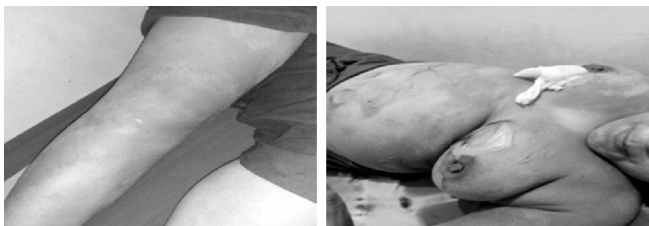


Fig1,2. Day of admission: Dusky erythema with some areas of blistering, sheet like erosions and positive nikolsky sign




Fig3,4. Day 2 pictures vesicobullous eruptions

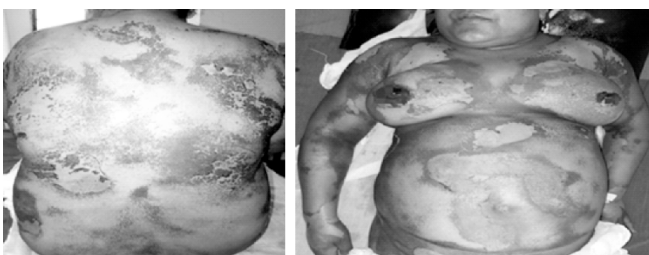

Fig5,6. Day 6: Granulation tissue as signs of healing after Doxycycline was stopped

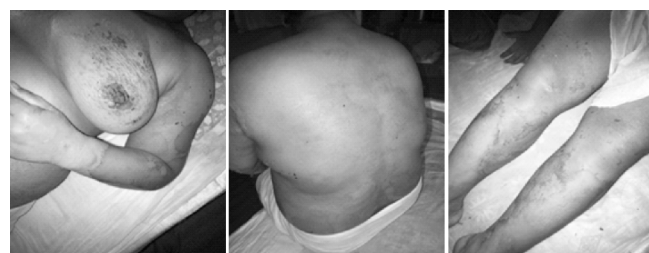

Fig7,8,9. Day 11, third day after discharge; signs of healing

DISCUSSION

The advent and the exposure to drugs has increased with demographic shifts associated with higher morbidity. TEN is one such rare, acute, and life threatening mucocutaneous disorder occurring with the usage of certain drugs which is a consequence of keratinocyte cell death that results in the separation of significant areas of skin at the dermal-epidermal junction with the production of bullae followed by swelling which can be associated with fever, asthenia, anxiety and moderate skin pain. The HLA status and phenotypes of metabolizing enzymes, drug prescriptions patterns, Genetic

background of the population, prevalence of infections, frequency of radiotherapy all are the key players which have an impact on the incidence of TEN.⁷

Based on the patient's medical history, percentage of the affected body surface area, skin detachment with the involvement of mucous membranes and early signs and symptoms, a final diagnosis of toxic epidermal necrolysis secondary to doxycycline was considered. Clinical and laboratory investigation report however show that the patient had history of allergy to doxycycline previously whilst ruling out the other causes. Similarly, the elevated serum procalcitonin level has been reported to be a valuable index in systemic bacterial infections and tissue injury in TEN patients.⁸ The patient improved as shown in the above pictures as soon as the offending drug was withdrawn.

The scortzen score was 1 based on the epidermal detachment and the causality assessment was done using Naranjo's scale⁶ and a probable causal relationship was established. Taking into account the above facts complemented with the low disease background incidence, a past allergic history to doxycycline and the plausible time to reaction onset, this case is possibly associated with doxycycline induced TEN. The patient was managed with IV fluids, antibiotics, analgesics, antihistamines, corticosteroids, vitamin supplements during her stay at the hospital.

There is usually a well-established, strong and direct association with the preceding drug ingestion and cutaneous manifestation resulting in TEN. Currently, three different hypothesis exist for the formation of an antigenic complex. Hapten/prohapten complex, noncovalent, direct interaction of the drug with a specific MHC class 1 allotype (p-i concept), altered peptide concept.⁹ The appearance of late-onset manifestations, one to three weeks after exposure to the triggering factor, is explained by the fact that in TEN, the pathogenic mechanism mimics a delayed hypersensitivity reaction at antigen primary exposure, but with extremely rapid and aggressive reaction at subsequent exposure.

Immunopathological changes incriminated in the pathogenetic mechanism of the disease involve activation of the Fas-FasL pathway with keratinocyte apoptosis,¹⁰ activation of the perforin-granzyme pathway by cytotoxic T lymphocyte, excess release of proinflammatory cytokines (IL, TNF, INF), and the excess synthesis of granulysin by the T lymphocyte and NK cells.

As a result, Fas-L-and granulysin-mediated apoptosis and annexin-dependent necroptosis of keratinocytes with subsequent epidermal necrosis and detachment develop. This indicates that the disturbance of balance between proinflammatory and immunomodulatory mechanisms which usually are critical to determine the clinical outcome in cutaneous inflammation.¹¹ The Nikolsky's sign (dermo-epidermal cleavage upon the friction in the periphery of the lesion) is positive, expressing the fact that the disease is active, in evolution.

CONCLUSION

The most fascinating part of this case is that in spite of being diagnosed as allergic to doxycycline two years back previously, the patient still failed to realise that the local medical practitioner prescribed her doxycycline and the patient consumed the same. So the question arises is it that the patient had to go through all this as the physician failed to elicit good history or is it the lack of knowledge and awareness of the patient in communicating to the doctor about her allergy status, the debate remains open to discussion.

CONFLICT OF INTEREST

None

REFERENCES

1. Bhandarkar AP, Kop PB, Pai V, Patil NA*. A report of five cases of fluoroquinolone-induced epidermal necrolysis at a tertiary care teaching hospital in northern Karnataka. *World J Pharm Res.* 2014;3(7):907-14.
2. Roujeau JC, Kelly JP, Naldi L, et al. Medication use and the risk of Stevens-Johnson syndrome or toxic epidermal necrolysis. *N Engl J Med.* 1995;333(24):1600-7.
3. Schopf E, Stuhmer A, Rzany B, Victor N, Zentgraf R et al. Toxic epidermal necrolysis and SJS. An epidemiologic study from west Germany. *Arch Dermatol.* 1991;127(6):839-42.
4. Yip VL, Alfirevic A, Pirmohamed M. Genetics of immune mediated adverse drug reactions: A comprehensive and clinical review. *Clin Rev Allergy Immunol.* 2015;48(2-3):165-75.
5. Friedman JM, Polifka JE. *Teratogenic Effects of Drugs. A Resource for Clinicians (TERIS).* Baltimore, MD: The Johns Hopkins University Press: 2000: 149-95.
6. Naranjo CA, Busto U, Sellers EM, Sandor P, Ruiz I, Roberts EA, et al. A method for estimating the probability of adverse drug reactions. *Clin Pharmacol Ther.* 1981;30(2):239-45.
7. Nunes JM, Santareno S, Guerreiro L, Margalho AF. Lyell's Syndrome and Antimalarials: A Case Report and Clinical Review. *J Glob Infect Dis.* 2017;9(1):23-30.
8. Wang Q, Tian XB, Liu W, Zhang LX. Procalcitonin as a diagnostic indicator for systemic bacterial infections in patients with Stevens-Johnson syndrome/toxic epidermal necrolysis. *The Journal of Dermatology.* 2018;45(8):989-93.
9. Revuz J, Penso D, Roujeau JC, et al. Toxic epidermal necrolysis. Clinical findings and prognostic factors in 87 patients. *Arch Dermatol.* 1987;123(9):1160-5.
10. Abe R, Shimizu T, Shibaki A, Nakamura H, Watanabe H, Shimizu H. Toxic epidermal necrolysis and Stevens-Johnson syndrome are induced by soluble Fas ligand. *Am J Pathol.* 2003;162(5):1515-20.
11. Nassif A, Moslehi H, Le Gouvello S, Bagot M, Lyonnet L, Michel L. Evaluation of the potential role of cytokines in toxic epidermal necrolysis. *J Invest Dermatol.* 2004;123(5):850-5.