

## PROFILE OF CLOSED GLOBE INJURY IN A SECONDARY EYE HOSPITAL

Manita Sunam Godar,<sup>1</sup> Sushila Patel,<sup>1</sup> Nita Sunam Gamal,<sup>2</sup> Laxmi Devi Manandhar<sup>1</sup>

### ABSTRACT

### INTRODUCTION

Closed globe injury of the eye is the type of injury in which the eyewall (sclera and cornea) is intact or only partial thickness wound is present. Studies focused only on closed globe injury of eye are limited. So the aim of the study was to analyse the demographic pattern, modes of trauma, place of trauma, agent of trauma and impact of trauma in different ocular structures and in vision.

### MATERIAL AND METHODS

It was a descriptive, cross-sectional study. Details of 167 patients with closed globe injury attending Dr. Binod Neeta Kandel Eye Hospital, Nawalparasi from Aug 2017 to July 2018 were recorded. Demographic profile, detailed history and examination findings were analysed.

### RESULTS

Closed globe injury was more common in males (61.7%) than females (38.3%). The mean age was  $30.76 \pm 16.58$  years, youngest being 3 years old whereas oldest 90 years old. Left eye was more involved. Domestic accident (38.92%) was the commonest. Conjunctival laceration (21.55%) and traumatic uveitis (21.55%) were the commonest sequelae of closed globe injury. Good vision (Visual acuity (VA) 6/6 -6/18) was seen in 79.64% cases whereas 7.78% cases were blind (VA less than 3/60).

### CONCLUSION

Closed globe injury can occur from different modes of trauma. Anterior segment of eye was more involved than the posterior segment. Even a trivial ocular trauma can have a sight threatening impact.

### KEYWORDS

Anterior segment, Closed globe injury, Posterior segment, Vision

1. Lumbini Eye Institute and Research Centre, Shree Rana Ambika Shah Eye Hospital, Bhairahawa, Rupandehi, Nepal.
2. Rapti Eye Hospital, Dang, Nepal.

<https://doi.org/10.3126/jucms.v10i02.51280>

#### For Correspondence

Dr. Manita Sunam Godar  
Lumbini Eye Institute and Research Centre  
Shree Rana Ambika Shah Eye Hospital and  
Research Centre  
Bhairahawa, Nepal.  
Email: manitagodar@gmail.com

## INTRODUCTION

Ocular trauma is one of the important causes of preventable ocular morbidity and blindness. Blindness due to ocular trauma was 2.4% according to Nepal Blindness Survey, 1981.<sup>1</sup> In Nepal corneal trauma and ulceration is the second most common cause of blindness after cataract. Bhaktapur Eye survey showed the prevalence of ocular trauma as 0.7%.<sup>2</sup> There is a cumulative risk of ocular trauma and visual loss during life, but the true incidence of accidents involving the eyes is not known.<sup>3</sup> Closed globe injury of the eye is the type of injury in which the eyewall (sclera and cornea) is intact or only partial thickness wound is present. Less studies have been done so far focusing on closed globe injury. Hence our study was conceptualized to know about the demographic pattern, different etiologies, common sites and common agents of closed globe injury and the different ocular impacts of closed globe injury.

## MATERIAL AND METHODS

This was a descriptive, cross sectional study conducted in Dr. Binod Neeta Kandel Eye Hospital, Nawalparasi, a secondary eye hospital of Lumbini Eye Institute and research centre, from august 1<sup>st</sup> 2017 to july 31<sup>st</sup> 2018. Ethical approval for the study was taken from the Institutional Review Committee of Lumbini Eye Institute and Research Centre. Detail history about demography, activity during injury, agent and place of injury were noted. Visual acuity was recorded using Snellen's chart for adults and co-operative children and CSM (Central, Steady, and Maintained) method for unco-operative children and graded according to the WHO grade. Detail ocular examination findings of anterior and posterior segment before and after mydriasis were noted. Intraocular pressure was taken with Goldmann applanation tonometer in adults and co-operative children. For unco-operative children digital tonometry findings were noted. Data were entered in the computer database and analysed with SPSS version 20.

## RESULTS

In this study, comprising of 167 patients, there was male preponderance (male 61.7% vs female 38.3%) (Figure 1). The mean age was  $30.76 \pm 16.58$  years, the youngest being 3 years of age whereas oldest, 90 years of age. Patients below 16 years accounted for 17.37% of study population (Table 1). Maximum patients were of age group 16-30 years (n=62, 37.13%). Patients above 60 years accounted for 5.99%.

In 44.9% (n 75) cases right eye was involved whereas 55.1% (n 92) cases had involvement of left eye (Figure 2).

The most common cause of injury was domestic accident (38.92%) followed by recreational activities (17.96%), work-related (14.97%), physical assault (12.57%), road traffic accident (8.98%) and outdoor accident (6.59%) (Table 2).

The most common place of injury was home (38.92%) followed by outdoor (35.93%), workplace (14.97%), road (8.98%) and school (1.20%) (Table 3).

Anterior segment of eye was involved in 86.4% and posterior segment was involved in 12.6%.

Conjunctival laceration (21.55%) and traumatic uveitis (21.55%) were the commonest followed by lid ecchymosis (18.7%). In posterior segment commotio retinae (5.69%) was the commonest. Raised intraocular pressure due to hyphema was recorded in only 3 patients (Table 4).

In our study, 79.64% had good vision VA (6/6-6/18) whereas 7.78% cases were blind (VA less than 3/60) (Figure 3). The commonest agent of injury was stick (16.77%) followed by stone (14.97%) (Table 5).

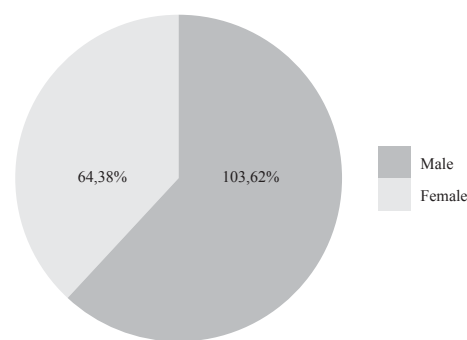


Figure 1. Gender distribution in closed globe injury

Table 1. Demographic characteristics

Age group	Number of cases
<16 yrs	29 (17.37%)
16-30 yrs	62 (37.13%)
31-45 yrs	48 (28.74 %)
46-60 yrs	18 (10.78%)
>60 yrs	10 (5.99%)

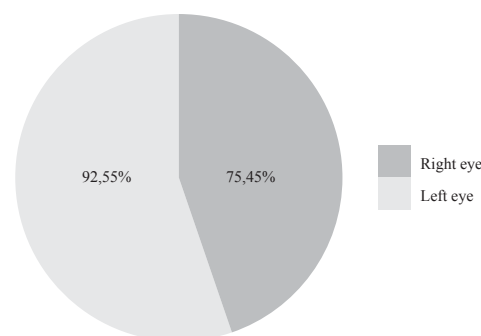


Figure 2. Pie chart showing eyes affected in closed globe injury

**Table 2.** Table showing cause of injury

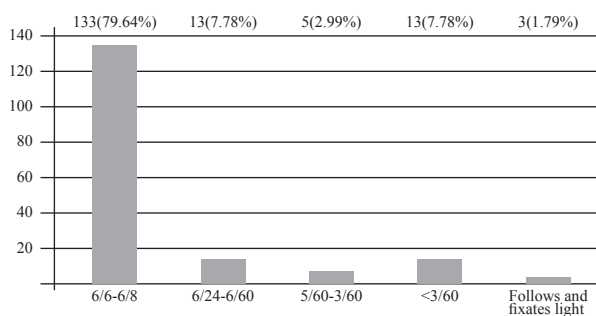
Cause of injury	No. of patients (%)
Domestic accident	65 (38.92%)
Play/ Recreational activities	30 (17.96%)
Work-related	25 (14.97%)
Physial assault	21(12.57%)
Road traffic accident	15 (8.98%)
Outdoor accident	11(6.59%)
<b>Total</b>	<b>167</b>

**Table 3.** Table showing place of injury

Cause of injury	No. of patients (%)
Home	65 (38.92%)
Outdoor	60 (35.93%)
Workplace	25 (14.97%)
Road/Highway	15 (8.98%)
School	2 (1.20%)
<b>Total</b>	<b>167</b>

**Table 4.** Table showing site of ocular involvement

Ocular structures involved	Clinical findings	No. of eys (%)	Ocular structures involved	Clinical findings	No. of eyes (%)
Lid	Lid ecchymosis	46 (18.7%)	Lens	Traumatic cataract	1 (0.41%)
	Lid laceration	12 (4.88%)		Subluxation of lens	2 (0.81%)
Conjunctiva	Subconjunctival haemorrhage	13 (5.28%)	Posterior segment	Dislocation of lens in vitreous	2 (0.81%)
	<b>Conjunctival laceration</b>	<b>53 (21.55%)</b>		Vitreous haemorrhage	7 (2.85%)
Cornea	Corneal abrasion	14 (5.69%)	<b>Comotio retinae</b>	Choroidal rupture	2 (0.81%)
	Corneal lamellar laceration	1 (0.41%)		<b>14 (5.69%)</b>	
Iris	Hyphaema	15 (6.1%)	Berlin's edema	3 (1.22%)	
	Traumatic mydriasis	2 (0.81%)	Macular hole	2 (0.81%)	
	<b>Traumatic uveitis</b>	<b>53 (21.55%)</b>	Retinal detachment	3 (1.22%)	
			Ocular norma	No pathology detected	1 (0.41%)

**Figure 3.** Bar diagram showing status of visual acuity in closed globe injury**Table 5.** Table showing agents causing closed globe injury

S.No	Agent	No.	Percentage%
1	Stick	28	16.77
2	Hand	15	8.98
3	Stone	25	14.97
4	Fist	13	7.78
5	Cricket Ball	11	6.59
6	Wood	7	4.19
7	Rope	6	3.59
8	Rubber tube	8	4.79
9	Animal horn/tail	8	4.79
10	Iron rod	5	2.99
11	Brick	8	4.79
12	Slipper	1	0.60
13	Pen/pencil	3	1.80
14	Bike/cycle	4	2.39
15	Catput	1	0.60
16	Door	2	1.20
17	Finger	2	1.20
18	Iron piece	2	1.20
19	Stem	1	0.60
20	Wire	1	0.60
21	Bamboo	1	0.60
22	Bottle lid	1	0.60
23	Mango	1	0.60
24	Desk edge	1	0.60
25	Elbow	1	0.60
26	Handpipe	1	0.60
27	Ladder	1	0.60
28	Mud	1	0.60
29	Nail	1	0.60
30	Plastic bottle	1	0.60
31	Toy	1	0.60
32	Cracker	4	2.40

## DISCUSSION

In our study, mean age was  $30.76 \pm 16.58$  yrs which was similar to studies by Godar ST et al ( $28.89 \pm 19.06$  yrs),<sup>4</sup> Kinderan VY et al ( $28.28 \pm 18.29$  yrs),<sup>5</sup> Islam QU et al ( $27.59 \pm 6.89$  yrs)<sup>6</sup> and Usharani et al (27 yrs).<sup>7</sup> So the burden of closed globe injury is more in the actively working age group which in turn can have an impact in economy of the family and society.

In our study, 17.3% belonged to pediatric age group similar to Godar et al (18.7%)<sup>4</sup> and Shah et al<sup>8</sup> (19%) which shows that children are also prone to closed globe injury. Ocular trauma in pediatric age group has specific challenges with regard to rehabilitation and amblyopia management. Besides visually handicapped children have more blind years to live hence ocular trauma in children has more economic burden to the society.

In our study, males were predominant similar to studies by Godar et al,<sup>4</sup> Kinderan VY et al,<sup>5</sup> Usharani et al<sup>7</sup> and Somen et al<sup>9</sup> most probably since males are more exposed to the outdoor activities, undertake high risk occupations and they are more adventurous, daring and aggressive with respect to the females.

In our study, left eye was more involved whereas in the study by Godar et al right eye was more involved.<sup>4</sup>

In our study domestic accident (38.92%) was the commonest similar to the study by Chinwe et al<sup>10</sup> whereas RTA was more common in study by Godar et al<sup>4</sup> and blast injury was more common in study by Islam QU et al,<sup>6</sup> in which study participants were military personnels. So it implies that ocular trauma can occur both with domestic works and outdoor activities so we need to be careful during all sorts of activities.

In our study home was the commonest place of injury similar to the study by Chinwe et al<sup>10</sup> and Sthapit et al,<sup>11</sup> whereas workplace injury was more common in studies by Godar et al<sup>4</sup> and Usharani et al.<sup>7</sup> It implies that accidental trauma to eyes can occur anywhere so we need to be careful everytime and everywhere.

The commonest sequelae following closed globe injury were traumatic uveitis (21.55%) and conjunctival laceration (21.55%) in our study whereas study by Godar et al showed subconjunctival haemorrhage,<sup>4</sup> Kinderan VY et al showed lid ecchymosis,<sup>5</sup> Islam QU et al showed vitreous haemorrhage<sup>5</sup> and Abha Shukla<sup>12</sup> showed lid injury as the commonest sequelae of closed globe injury. So any ocular structure can get involved in closed globe injury hence complete ocular examination is the most to rule out the effect of trauma in the eye.

Good vision (VA>6/18) was seen in 79.64% almost similar to studies by Godar et al<sup>4</sup> and Kinderan VY et al.<sup>5</sup> Poor vision VA <3/60 was seen in 7.78%. Most of the time the impact of closed globe injury is confined to the anterior segment so vision is not compromised. However, with greater impact of injury even the posterior segment of the eye can get involved with resultant visual impairment and sometimes even loss of vision.

Stick (16.77%) was the commonest agent of closed globe injury similar to the study by Godar et al,<sup>4</sup> and Sthapit et al.<sup>11</sup> But there could be myriad of agents that can be inflicted in closed globe injury.

## CONCLUSION

Closed globe injury was more common in males and actively working age group. Domestic accident was the commonest. Anterior segment was more involved than the posterior segment. Even a trivial closed globe injury can have a sight threatening impact. Loss of sight can have a huge impact on the daily life, the need for medical care, income generation and the cost of rehabilitation.

Community awareness on ocular trauma and preventive strategies are to be focused on the eye health education programmes.

## LIMITATIONS

Since it was the cross-sectional study, we have missed the final outcome of the injury. Besides the study was done in the secondary level hospital where the number of patients attending the hospital is lesser than a large tertiary centre. So in future prospective studies in larger centre on closed globe injury can unfold the important details if missed in this study.

## CONFLICTS OF INTEREST

None

## REFERENCES

1. Brilliant LB, Pokhrel RP, Grasset NC, et al. Epidemiology of blindness in Nepal. *Bulletin of the World Health Organization*. 1985; 63:375-86.
2. Upadhyay MP, Karmacharya P, Koirala S, et al. Bhaktapur Eye Study: Ocular trauma and antibiotic prophylaxis for the prevention of corneal ulceration in Nepal. *Br J Ophthalmol*. 2001; 85: 388-92.
3. Thylefors, World Health Organization, Geneva, Switzerland. Epidemiological patterns of ocular trauma. *Australian and New Zealand Journal of Ophthalmology*. 1992; 20(2):95-98.
4. Godar ST, Kaini KR, Amatya P, Joshi K, Singh L. Magnitude of ocular trauma in a tertiary care hospital of western Nepal. *Nepal Journal of Medical Sciences*. 2013;2(2):140-3.
5. Kinderan YV, Shrestha E, Maharjan IM, Karmacharya S. Pattern of ocular trauma in the Western Region of Nepal. *Nepal J Ophthalmol*. 2012;4(7):5-9.
6. Islam QU, Ishaq M, Yaqub A, Saeed MK. Functional and anatomical outcome in closed globe combat ocular injuries. *J Pak Med Assoc*. 2016 Dec; 66(12):1582-1586.
7. Laishram U, Yumnam CM, Gahlot A, Thoudam RS, Keisham SD. Epidemiological profile of ocular trauma in a tertiary care facility in Imphal. *J Med Soc*. 2016; 30:162-5.
8. Shreya M Shah, Mehul A Shah, Romi Singh, Chetan Rathod, and Ranuq Khanna. A prospective cohort study on the epidemiology of ocular trauma associated with closed-globe injuries in pediatric age group. *Indian J Ophthalmol*. 2020 Mar;68(3): 500–503.
9. Somen Misra, Rupali Nandwani, Pratik Gogri and Neeta Misra. Clinical profile and visual outcome of ocular injuries in a rural area of western India. *Australas Med J*. 2013;6(11): 560–564.
10. Chinwe Cynthia Jac-Okereke, Chukwunonso Azubuike Jac-Okereke, Ifeoma Regina Ezegwui, Rich Enujioko Umeh. Current pattern of ocular trauma as seen in tertiary institutions in south-eastern Nigeria. *BMC Ophthalmol*. 2021;21: 420.
11. Sthapit PR, Marasini S, Khoju U, Thapa G, Nepal BP. Ocular trauma in patients presenting to Dhulikhel Hospital. *Kathmandu Univ Med J*. 2011;33(1)54-7.
12. Shukla A, Singh M, Garg A. Epidemiological profiling of mechanical ocular trauma and analysis using proposed new classification for ocular adnexal injuries. *Beyoglu Eye Journal*. 2021;6(2):102.