

# Transverse Eponychial Flap For Nail Lengthening And Fingertip Reconstruction

Krishna Manandhar

## Abstract

**Introduction:** Fingertip injuries are frequented with loss of pulp and nail complex. Most reconstructive procedures provide either the soft tissue defect coverage or lengthen the nail.

**Methods:** Patients included were more than 10 years of age with fingertip injury of Allen type III and IV with intact eponychium. Transverse Eponychial Flap was used to lengthen the nail lost as well as provide defect coverage. Paired t test, chi square test and Pearson correlation and Mann Whitney test were used for statistical analysis.

**Results:** Seventeen digits were analyzed. The average lengthening of the nail achieved was 142.4%. The average nail length during follow up was 59.1% of contralateral, with average final nail lengthening achieved was 31%. Reconstruction with Transverse Eponychial flap alone was performed in 58.8% of digits. Four patients (23.52%) had complete near normal nail. Sixteen digits had satisfactory and higher results. With Transverse Eponychial Flap alone it was possible to completely cover 10 fingertips (58.8%), requiring local flaps or skin graft for the remaining cases. Obliquely orientated injuries (76.47%) were more likely to undergo the procedure.

**Conclusion:** The flap significantly lengthens the nail, and provides satisfactory results. We recommend the use of this flap in defects with Allen type III and IV fingertip injuries.

**Keywords:** Eponychial flap; Fingertip injury; Nail length.

### Author affiliations:

Absolute Aesthetics,  
Hospital for Advanced Medicine and  
Surgery (HAMS),  
Norvic International Hospital

### Correspondence:

Dr. Krishna Manandhar,  
Absolute Aesthetics,  
Maharajgunj Plaza 4th floor, Maharajgunj  
Kathmandu, Nepal.

**Email:** manandhar.k@hotmail.com

**ORCID:** <https://orcid.org/0000-0002-7886-1279>

### Disclosures:

**Ethical Clearance:** Taken

**Conflict of interest:** None

**Financial aid:** None

### Copyright information:



Authors retain copyright and grant the journal right of first publication with the work simultaneously licensed under Creative Commons Attribution License under CC-BY 4.0 that allows others to share the work with an acknowledgement of the works's authorship and initial publication of this journal.

### How to cite this article:

Manandhar K. Transverse eponychial flap for nail lengthening and fingertip reconstruction. J Soc Surg Nep. 2023; 26(1):3-10.

### DOI:

<https://doi.org/10.3126/jssn.v26i1.57347>

## Introduction

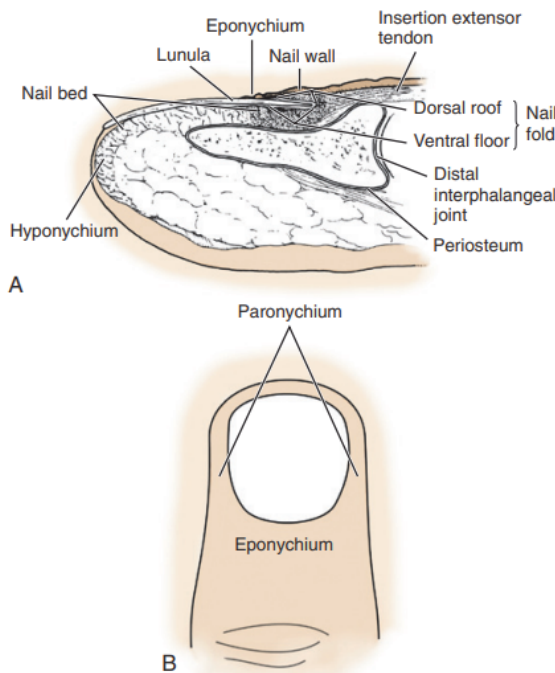
Fingertip injuries are the commonest among hand trauma. These injuries are frequently associated with injuries of the onychial complex in the form of lacerations and loss of nail and nail bed. The importance to reconstruct this small, conspicuous, yet important functional part of the digit has been emphasized frequently in the past.<sup>1-13</sup>

## Historical review

Techniques to provide length to the shortened nail bed are few. Some have used nail bed grafts<sup>14</sup> or excision of the scarred nail bed and allowing the normal nail to grow further<sup>15</sup>, while others have used the eponychium either by excising it<sup>12</sup> or creating different types of eponychial flaps.<sup>4,7,9,14</sup> The first to describe an eponychial flap was Bakhach in 1998.<sup>7</sup> Since then, three types of eponychial flaps have been described – reverse advancement, bipedicled, reverse placcation, whereas, Wang et al simply excised the eponychium to expose the hidden nail and nail bed.<sup>4, 7, 9, 12</sup>

## Anatomy

Zook has described the nail complex as shown in **Figure 1**.<sup>16</sup> The perionychium includes the nail bed, nail fold, with surrounding soft tissue referred to as eponychium, paronychium, and hyponychium. Paronychium refers to the skin on each side of the nail, and hyponychium refers to the skin distal to the nail bed. The eponychium is the skin proximal to the nail that covers the nail fold. Extending distally from the eponychium onto the nail is the nail vest or cuticle. The white arc of the nail just distal to the eponychium, known as the lunula, is the distal extent of the germinal matrix.



**Figure 1. The perionychial complex. A – longitudinal section; B – Illustration of relationship between paronychium and eponychium.**

Adani has described the eponychial cranio-caudal dimension of 5-6mm.<sup>10</sup> The lateral borders extend to the imaginary line as a cranial extension of the paronychial line, ulnarly and radially. The eponychium receives blood supply from the branches of digital artery.<sup>16, 17</sup>

## Transverse Eponychial Flap (TEF)

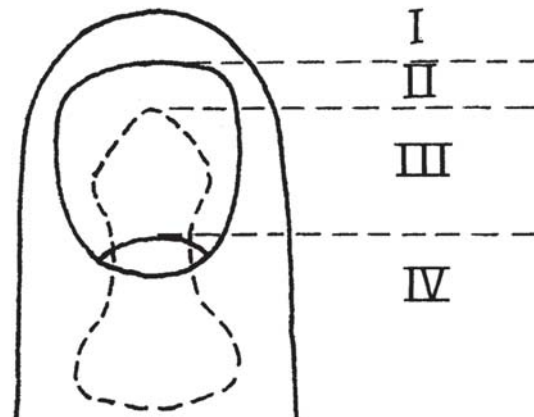
We propose a design of a flap based on the eponychial tissue. The eponychium is incised and based on radial or ulnar side and elevated interpolating to the distal fingertip defect. This exposes lunula and lengthens the nail bed as well as reconstructs the fingertip defect. The flap receives blood supply from the dorsal skin vessels through the proximal arcade of the dorsal subungual vascular network of the distal phalanx originating from the volar digital artery.<sup>16, 17</sup>

Hence, the aim of the study is to evaluate the Transverse Eponychial Flap's ability to fulfill its two proposed functions and analyze the resultant aesthetic and functional benefits.

## Methods

This is a retrospective case series study conducted in the Department of Plastic Surgery and Burns at Tribhuvan University Teaching Hospital and National Academy of Medical Sciences (National Trauma Center and Bir Hospital) in Kathmandu over a period of 5 years, from February 2017 to April 2022. All cases were result of trauma. The department clearance for the study has been obtained.

Patients in the emergency room were evaluated for eligibility based on Allen's classification as well as on orientation of the wound into volar or dorsal, transverse or oblique (radial/ulnar), and the combinations as shown in **Table 1** and **Figure 2**.<sup>18</sup> But mostly, these injuries occur in combined orientation. A combined but practical classification has been described in **Table 2**.



**Figure 2. Illustration of Allen's classification<sup>18</sup>**

**Table 1. Allen's classification of fingertip injury<sup>18</sup>**

Allen's classification	
Type I	Only pulp of the finger involved
Type II	Having pulp and nail loss
Type III	Partial loss of terminal phalanx plus corresponding loss of pulp and nail
Type IV	Lunula involved along with pulp and nail as well as partial loss of terminal phalanx

The inclusion criteria consisted of digital tip injuries involving loss of nail bed by more than half in transverse orientation, oblique orientation with loss of more than half on either radial or ulnar side, intact eponychium, intact remaining matrix, patients more than 10 years of age and without any life threatening comorbidities. Patients excluded were those less than 10 years of age, non-viable nail bed, complete distal phalangeal bone loss, amputated digit, and injury of the eponychium. Patients were counselled about the procedure and consent was taken.

A pro forma was designed. The following variables were noted as shown in **Figures 3 and 4**:

- Contralateral normal nail bed length (CN)
- Post-debridement length of remaining nail bed of injured digit (RN) (the length was measured from the midpoint of eponychium to the midpoint of the distal nail bed edge)
- X, percentage of remaining nail bed length (RN) with respect to the contralateral normal nail bed length (CN)  $\{RN/CN*100 = X\}$
- Dimensions of the defect and flap
- Immediate postoperative new nail bed length (NN)
- Immediate nail bed lengthening achieved (NN-RN = LA)
- Percentage of immediate nail bed lengthening achieved  $(LA/RN*100 = LA \%)$
- Y, percentage of new nail bed length (NN) with respect to normal contralateral nail bed length  $(NN/CN*100 = Y)$
- G, Immediate net gain in nail bed length  $(Y-X = G)$
- Final nail bed length (FN) (at the time of latest follow up)
- Z, final nail bed length with respect to normal contralateral nail bed length  $(FN/CN*100 = Z)$
- H = final net gain in nail bed length  $(H = Z-X)$
- Sensation of the digital tip
- Quality of nail (shape, surface, colour, lustre)
- Shape of pulp
- Eponychium during follow up
- Patient satisfaction rate
- Surgeon satisfaction rate

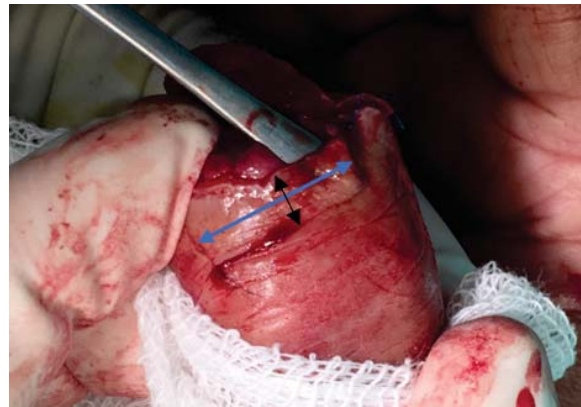### Surgical technique

Under local anaesthesia, the injured fingertip was debrided and classified according to Allen's description as shown in **Figure 2**. Preoperative measurements were taken. The

**Table 2. Combined classification of Allen and Orientation of fingertip injury**

Orientation Classification		Allen's Classification
Volar-Oblique	radial or ulnar	Type I / Type II / type III / type IV
Volar-Horizontal		Type I / Type II / type III/ Type IV
Dorsal-Oblique	radial or ulnar	Type I / Type II / type III/ Type IV
Dorsal-Horizontal		Type I / Type II / type III/ Type IV
True Transverse		Type I / Type II / type III/ Type IV

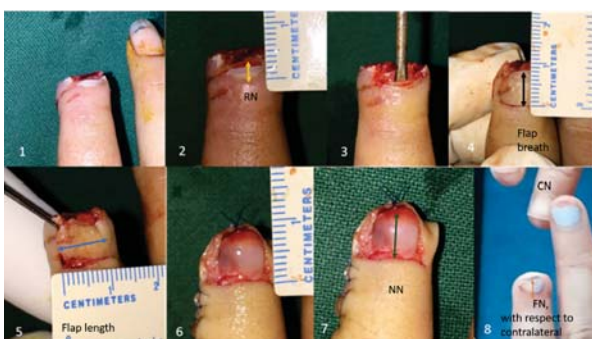eponychium was elevated with periosteal elevator and its cranio-caudal dimension corresponded to the breath of the flap. The ulnar-radial dimension corresponded to the flap length as shown in **Figure 3**.



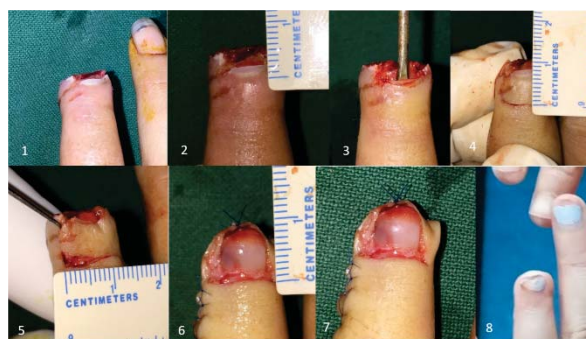**Figure 3. Demonstration of the procedure of elevation of the flap with the help of periosteal elevator. The elevator allowed to determine the cranio-caudal extent indicated by black arrow which corresponded to the breath of the flap and radio-ulnar dimension indicated by blue arrow which corresponded to the flap length.**

The decisions on which side to locate the base of the flap depends on the presence of amount of tissue left on either side of the wound. Base would be appropriate where the loss is more. In situations where the loss is at the level of lunula in a transverse loss either side can qualify for the base.

The borders of the flap were marked. The incision was first made at the tip side of the flap guided by the tip of the elevator. With the help of Gillies skin hook the flap was tented from the tip and with light traction applied incision was made along the cranial border of the flap towards the base. The incision was limited to the imaginary extension of paronychia line. In some instances, the cranial border could be extended further for few milliliters obliquely cranially. The dimensions of the flap are measured. The flap was then pivoted towards the hyponychium and its borders sutured to the distal defect by 6/0 round bodied polypropylene suture as shown in **Figure 5**. The flap interpolation lengthened the nail bed by exposing the proximal nail and / or nail



**Figure 4.** Demonstration of parameters used for pro forma. The whole procedure for descriptive purpose was divided into 8 stages. In stage 2, post-debridement length of the remaining nail bed (RN) was noted. In stage 4 and 5, the flap breath and length were determined. Stage 7 showed length of immediate new nail bed, whereas in stage 8, the final nail bed length at the time of latest follow up was measured and compared with respect to contralateral normal.



**Figure 5.** Surgical technique of Transverse Eponychial Flap. Case 1. Stage 1 - The eligible defect of the left ring finger was evaluated, classified and operation planned. Stage 2 - Dimensions of nail - nail bed complex was carried out. Stage 3 & 4 - eponychium was elevated until no further was possible corresponding to the borders of the flap which was marked. Stage 5 - Incision was given. Stage 6 & 7 - The flap was interpolated to the defect and sutured providing complete coverage as well as exposing the proximal most subeponychial nail bed resulting in longer new nail bed. The length of new nail was measured. Stage 8 - Nail after 4.8 years of operation indicated by black arrow.

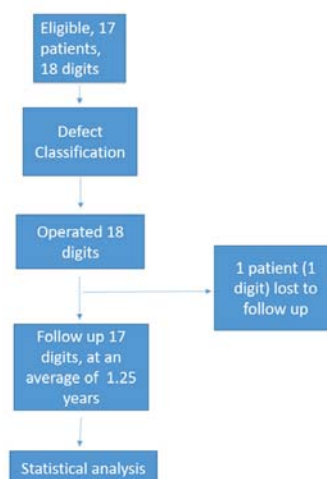
bed and also provided coverage of the defect, partially or completely. Partially covered defects were reconstructed with either other local, regional flaps or skin grafts. The digits were dressed and splinted.

All patients were requested to follow up on 4th, 9th and 14th postoperative days for dressing and suture removal. Final follow up was dated at one year or further. The final nail bed (FN) and its derivatives were measured at this time. Satisfaction rates were divided into four categories, unsatisfactory for 0 to 5, satisfactory for 6 to 7, good for 8 to 9, and excellent for 10.

Statistical analysis was performed with the help of SPSS version 16. Paired t test, chi square test and Pearson correlation and Mann Whitney test were used.

## Results

Seventeen patients with 18 digits were assessed for eligibility and proceeded for operation. One patient was lost to follow up. Results of remaining 17 digits were analyzed as shown in the figure 6. Table 3 shows the variables studied with the mean values. Majority patients were students (31.25%) followed by businessmen (18.75%). The mean age of patients was  $34.5 \pm 18$  years, where 82.4% were males. Digits of both hands were nearly equally injured, right and left, 52.9 % and 47.1%, respectively. Six (35.29%) of the injured digits were thumb, followed by index and long fingers, 23.5% each. Crush-avulsion was the mechanism of injury in all digits. Injuries were classified under Allen type III and type IV in 64.7% and 35.3%, respectively, while nine (52.94%) of injuries were of volar-oblique orientation with 29.4% on ulnar side and 23.5% on radial side. Thirteen (76.47%) injuries were of oblique orientation. The mean contralateral nail bed length (CN) was  $13.4 \pm 1.5$ .



**Figure 6.** Flow chart of process of eligibility, defect evaluation, classification, operation, follow up and statistical analysis

### Defect of injured digit

The mean area of the defect was  $189.2 \text{ mm}^2$ , ranging from 100 to  $288 \text{ mm}^2$ . Following debridement the mean length of the remaining nail bed (RN) of the injured digit was  $3.8 \pm 1.8 \text{ mm}$ , resulting of mean  $X = 28.1\% \pm 11.9$ , with significant p value of  $< 0.001$ .

### Transverse Eponychial Flap

The mean length, breath and area of the transverse eponychial flap was  $12.5 \text{ mm} \pm 2.2$ ,  $5.2 \text{ mm} \pm 0.8$  and  $64.6 \text{ mm}^2 \pm 13.3$ , respectively. Twelve flaps (70.58%) were based on the radial side and 29.4% on ulnar side. Complete coverage in 10 digits (58.82%) was achieved with the TEF alone, while 35.3% required local flaps, like V-Y advancement flap or volar transposition flap. Skin graft was used in one digit (5.9%).

**Table 3. Important variables with their mean values**

Variables of interest	Min-Max	Mean±SD
Age (years)	13-66	33.5 ±18.0
Contralateral nail (CN) (mm)	12-17	13.4 ±1.5
Remaining nail (RN) (mm)	2-8	3.8 ± 1.8
X	13.33-47.05	28.1 ±11.9
Defect Length (mm)	10-18	14.7 ±2.4
Defect Breath (mm)	10-16	12.8 ±1.9
Defect area (mm2)	100-288	189.2 ±50.7
TEF length	10-18	12.5 ±2.2
TEF breath	4-8	5.2 ±0.8
TEF area (mm2)	48-90	64.6 ±13.3
New Nail (NN) (mm)	5-15	8.4 ±2.5
LA	3-7	4.6 ±1.1
LA (%)	50-200	142.4 ±49.7
Y (%)	38.46-88.23	63.1 ±17.7
G (%)	20-50	35.0 ±8.3
FN (mm)	5-15	7.9 ±2.5
Z (%)	35.57-83.33	59.1 ±16.0
H (%)	13.33-46.16	31.0 ±7.5
Pain at rest	0-2	0.1 ±0.5
Pinch pain	0-5	1.1 ±1.5
Patient satisfaction	2-10	7.1 ±1.6
Surgeon satisfaction	2-8	6.2 ±1.5

X = RN/CN \* 100 (%); TEF = Transverse Eponychial Flap; LA = lengthening achieved; Y = NN/CN\*100; G = Y-X; FN = final nail bed length; Z = FN/CN\*100; H = Z-X

**New nail bed length (NN) and Final nail bed length (FN)**

Immediately following the operation the new nail bed length (NN) measured from 5 to 15mm with mean of 8.4mm±2.5 achieving lengthening of nail bed (LA) from mean RN of 3.8mm by 4.65mm, an increase by a mean of 142.4% (Y), with significant p value of <0.001. The immediate postoperative net gain in nail bed length was G = Y - X, i.e. 35%±8.3. In 15 digits (88.23%), the lengthening achieved was more than 100 percent, while in six (35.29%) digits LA was 200 percent.

The final nail bed length (FN), determined at the latest follow up, measured from 5 to 15mm with mean of 7.9mm±2.5, reaching a mean of 59.1%±16.0 of CN (Z), indicating final nail bed lengthening achieved from RN by 4.17mm, with significant p value of <0.001. This increase amounted to final nail bed length net gain (H = Z - X) of 31%±7.5, also with significant p value of <0.001.

**Sensation**

Sixteen patients had no pain at rest during the last follow up. Only in one digit (5.9%) the patient complained of pain at rest of 2 on a scale of 10, whereas seven digits (41.11%) patients complained of pain on pinch, ranging from five, three, two, one in one, two, three and one digits, respectively. Eleven digits (64.70%) presented with some form of combination of hyperesthesia, pain on pinch and

associated flaps as shown in **Table 4**. Nine digits (52.94%) had hyperesthesia which was decreasing in severity as per patients’ verbal assessment. Seven digits had associated flaps or skin graft performed. Three digits exhibited combinations of all three, seven of hyperesthesia and pain on pinch, three of pain on pinch and associated flaps whereas five of associated flaps and hyperesthesia. Chi square test reveals no association of associated flaps with any aspects of sensation with the p value of 0.433.

**Table 4. Follow up presentation of sensory perceptions in patients who underwent reconstruction of the fingertip defect with associated flaps**

Associated flaps	Hyperesthesia	Pain on pinch	Number of combinations
+	+	+	3
-	+	+	7
+	-	+	3
+	+	-	5

**Nail aesthetics**

Four nails (23.52%) were near normal, whereas 13 developed combination of near normal with single or multiple irregularities as shown in table 5. Nine digits (52.9%) had smooth nails and eight (47.1%) presented with near normal colour. Nine (52.9%) presented with abnormal colour. The growth of nail plate was proportional to nail bed in all digits. Only five digits (29.4%) attributed near normal lustre and eight (47.1%) developed near normal pulp shape. Although presence of associated flaps were noted in 3 cases of irregular nail shape, four cases of irregular nail surface, four cases of abnormal colour, and five cases of decreased nail lustre. Chi-square test showed no association between nail aesthetics and associated flaps with insignificant p-values.

Eponychium in all operated digits were less distinct than the normal contralateral as can be seen in stage 6 of figure 9 but that did not dissatisfy the patient. All patients were more concerned with the quality of new nail.

**Table 5. Aesthetic characteristics of the recovered nail. Most of them presented in some form of combination.**

	Nail shape	nail surface	nail colour	nail length	nail lustre	pulp shape
nn	11	9	8	-	5	8
i	6	8	-	-	-	9
ac	-	-	9	-	-	-
d	-	-	-	-	12	-
p	-	-	-	17	-	-

nn = near normal; I = irregular; s = smooth, is considered as normal; ac = abnormal colour; d = decreased; p = proportionate to nail bed, is considered as normal.

**Patient – Surgeon satisfaction**

Satisfaction score was rated by a scale from 0 to 10. Patient satisfaction ranged from 2 to 10, with a mean of 7.1. Surgeon satisfaction ranged from 2 to 8, with a mean

of 6.22. Pearson correlation coefficient between these two parameters was 0.797, with p value of <0.001 with strong correlation as shown in figure 7. In one, ten, five and one digits, patients expressed dissatisfaction, satisfactory, good and excellent results, respectively, whereas in three, twelve and two digits the surgeon was unsatisfied, satisfied and felt good, respectively. Sixteen cases were of satisfactory and higher results as shown in **Table 6**.

**Table 6. Distribution of satisfaction rate of the patient and the surgeon.**

	patient n(%)	surgeon n(%)
Unsatisfactory (0-5)	1 (5.88)	3 (17.64)
Satisfactory (6-7)	10 (58.82)	12 (70.58)
Good (8-9)	5 (29.41)	2 (11.76)
Excellent (10)	1 (5.88)	0 (0)

## Discussion

One of my patients said that “the nail is the jewel of the finger” when asked if the operation was justified in spite of having not the ideal result with surgeon’s satisfaction rate of seven and his satisfaction rate of 10. He said that he would not accept a finger without a nail. This does indicate the importance of nail not only as a functional organ but an aesthetic one, too.

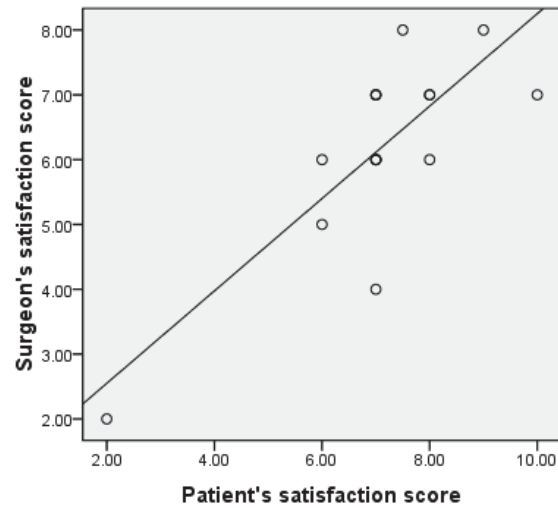
### The defect of the injured digit

Although defect presented in different sizes and orientations, with the TEF alone it was possible to completely reconstruct 10 digits (58.8%), requiring local flaps or skin graft for remaining cases. Oblique orientation (76.47%) of the defect were most to undergo the procedure. The inadequacy of the remaining nail was significant when compared with the normal contralateral nail. Comparing the lengthening of the nail following the operation, the difference between the preoperative and postoperative length was significant.

### Transverse Eponychial Flap

The flap had some advantages. Firstly, it was possible to raise the flap on either radial or ulnar side. Secondly, it significantly lengthened the nail. Thirdly, it was also possible to provide coverage of the defect, partial or complete. Fourthly, as it provided some coverage of the defect, it prevented extensive dissection of associated flaps. The eponychial flaps described by other authors made it possible to lengthen only the nail and had to use local flaps for pulp reconstruction.<sup>7, 10, 12</sup> In a study by Adani, eleven out of 12 patients required associated flaps for pulp reconstruction.<sup>1</sup>

In the initial phases of the study, the nail was dissected out to confirm the integrity of the nail bed, then later to suture it back for splinting, but this demanded care for long time increasing the risk to the bed. Therefore, we limited our procedure to just raising the flap excluding nail elevation reducing wound care to just about 2 weeks.



**Figure 7. Distribution of satisfaction score of patients and surgeon and their correlation**

### New Nail bed length (NN) and Final Nail bed length (FN)

The average lengthening of the nail bed achieved by Bakhach was 3.75mm, where as in our study was about 4.65mm.<sup>7</sup> This length was measured immediately after completion of the procedure (NN), but later on follow up, we found that the length (FN) had decreased to 4.17mm. This difference between the NN (Y) and FN (Z) was significant with p value of 0.004, which we assume owing to the reduction in swelling of the onychial-pulp complex. The percentage of restored nail bed length as compared to contralateral ranged from 84.6 to 108.3 percent, average of 96.3% as reported by Bakhach et al, whereas in our study, this percentage ranged from 35.5 to 83.33 percent, an average of 59.09 percent.<sup>7</sup> This is because of the indications in our study where our cases consisted of type III injury according to Allen’s classification where the average remaining length of the nail was just 3.8±1.8mm, otherwise only 28.1% of the contralateral nail length.

### Sensation

The combined occurrence of hypersensitivity and pain on pinch together with associated flaps up to a year in some cases, although decreasing in intensity, was alarming but no associations have been found. Hypersensitivity occurred in 9 cases out of which 5 had undergone associated flaps and four only TEF. Such a phenomena is possibly due to the magnitude of injury (all were crush-avulsion) and time required for the injury to heal in spite of flap coverage. Tupper et al reported hypersensitivity in 60% fingertip injury repaired cases, similar to our study, with an average follow up period of 5.9 years.<sup>19</sup>

### Nail aesthetics

Bakhach et al reported that their results ranged from very good to excellent, an almost normal appearance as compared to contralateral nail.<sup>7</sup> In our study, only 5 out of 17 (29.41%) had almost normal nail. All others had a

combination of some normal and some abnormal aesthetic features. Such a large percentage of combined aesthetic features probably can be explained by very small remaining nail (RN), dissection out of the nail during operation in cases during the initial stage and poor care of these exposed nail bed.

#### Patient – Surgeon satisfaction

The surgeon was more skeptical about the results than the patient owing to the fact that surgeon had more unsatisfactory and no excellent views than patients. Both expressed almost equal satisfactory-good, in 14 digits by surgeon and in 15 by patients which might have been the reason for strong correlation between them. Bakhach et al had all their results good to excellent.<sup>7)</sup>

#### Limitations

Despite the number of years of the study, the case numbers were relatively few. Follow up was inconsistent. Only few reported physically and others sent the photographs of their digits.

#### Examples of Transverse Eponychial Flap

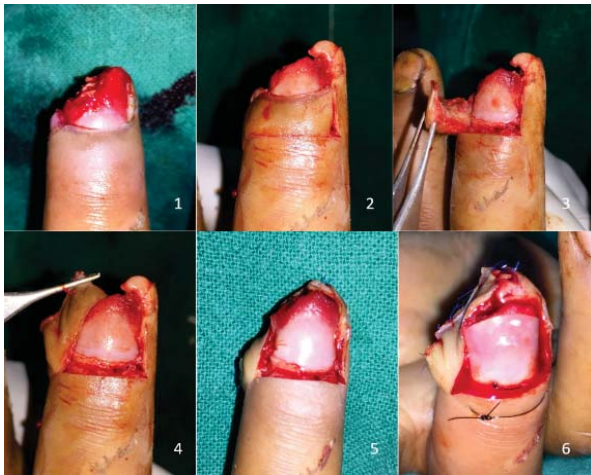

Figure 8. (Case 2) A teenage of 16 years had his right long fingertip crushed by machine belt. The injury was evaluated as Allen's type III with radial oblique dorsal injury after nail removal and debridement. A radially based transverse eponychial flap was raised and interpolated distally to the defect and sutured. A marked improvement in the length has been noticed. The nail is sutured back to provide splinting and protection.

#### Conclusion

In this study, Transverse Eponychial Flap, a modification of eponychial flap has been described. A dual effect of lengthening of the nail bed as well as providing reconstruction of fingertip defect in 58.82% of cases has been achieved. The method was simple and quick to perform. It was easy and less morbid to perform without removing the remaining nail. Both patient and the surgeon accepted results satisfactorily with more on patient side. The disadvantage that we have encountered was the presence of some type of abnormality in the final nail aesthetics in some cases. We recommend the use of this flap in defects with Allen type III and IV fingertip injuries.

#### Acknowledgment

I would like to express my gratitude to the faculties of Department of Plastic Surgery and Burns at Tribhuvan University Teaching Hospital and National Academy of Medical Sciences (National Trauma Center – Bir Hospital) and all the patients who participated.

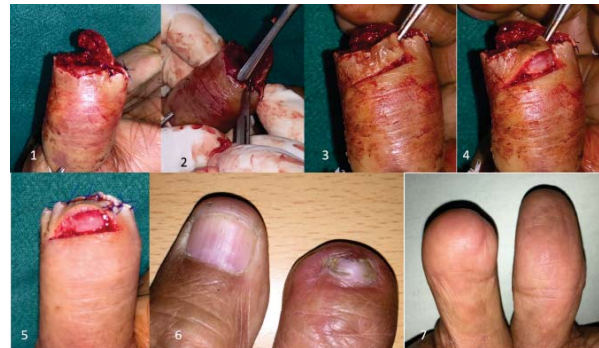

Figure 9. (Case 3) A gentleman of 60 years presented with fingertip crush-avulsion amputation at mid-shaft of distal phalangeal level with partial degloving of the pulp but surviving and nail avulsion. The injury was evaluated as Allen type III with horizontal volar orientation. Using periosteal elevator the eponychium was dissected from the nail bed and a radially based transverse eponychial flap was raised. Interpolating distally to the defect the subeponychial nail bed was exposed giving new length to the nail bed. The flap was sutured to the partially degloved pulp and the defect reconstructed.

#### References

1. Adani R, Leo G, Tarallo L. Nail salvage using the eponychial flap. *Tech Hand Up Extrem Surg.* 2006;10(4):255-8.
2. Rai A, Jha MK, Makhija LK, Bhattacharya S, Sethi N, Baranwal S. An algorithmic approach to posttraumatic nail deformities based on anatomical classification. *J Plast Reconstr Aesthet Surg.* 2014;67(4):540-7.

3. Champagne L, Hustedt JW, Walker R, Wiebelhaus J, Nystrom NA. Digital Tip Amputations from the Perspective of the Nail. *Adv Orthop.* 2016;2016:1967192.
4. Chen HY, Hsu CC, Lin YT, Yeh JT, Lin CH, Lin CH. Functional and aesthetic outcomes of the fingertips after nail lengthening using the eponychial flap. *J Plast Reconstr Aesthet Surg.* 2015;68(10):1438-46.
5. Fakin RM, Biraima A, Klein H, Giovanoli P, Calcagni M. Primary functional and aesthetic

- restoration of the fingernail in distal fingertip amputations with the eponychial flap. *J Hand Surg Eur Vol.* 2014;39(5):499-504.
6. Goutos I, Jennings CL, Pandya A. Reconstruction of the burnt perionychium: literature review and treatment algorithm. *J Burn Care Res.* 2011;32(4):451-7.
  7. Bakhach J, Demiri E, Guimberteau JC. Use of the eponychial flap to restore the length of a short nail: a review of 30 cases. *Plast Reconstr Surg.* 2005;116(2):478-83.
  8. Lemmon JA, Janis JE, Rohrich RJ. Soft-tissue injuries of the fingertip: methods of evaluation and treatment. An algorithmic approach. *Plast Reconstr Surg.* 2008;122(3):105e-17e.
  9. Merlino G, Carlucci S. A simple modification of the Bakhach's eponychial flap for nail lengthening after fingertip amputation. *J Plast Reconstr Aesthet Surg.* 2011;64(10):e265-6.
  10. Adani R, Marcoccio I, Tarallo L. Nail lengthening and fingertip amputations. *Plast Reconstr Surg.* 2003;112(5):1287-94.
  11. Turner A, Ragowansi R, Hanna J, Teo TC, Blair JW, Pickford MA. Microvascular soft tissue reconstruction of the digits. *J Plast Reconstr Aesthet Surg.* 2006;59(5):441-50.
  12. Wang L, Yuan SY. A simple and direct procedure for excision of peripheral skin above the nail root to enable nail lengthening after fingertip amputation. *J Plast Reconstr Aesthet Surg.* 2012;65(9):e265-6.
  13. Xing S, Shen Z, Jia W, Cai Y. Aesthetic and functional results from nailfold recession following fingertip amputations. *J Hand Surg Am.* 2015;40(1):1-7.
  14. Raja Sabapathy S, Venkatramani H, Bharathi R, Jayachandran S. Reconstruction of finger tip amputations with advancement flap and free nail bed graft. *J Hand Surg Br.* 2002;27(2):134-8.
  15. Lemperle G, Schwarz M, Lemperle SM. Nail regeneration by elongation of the partially destroyed nail bed. *Plast Reconstr Surg.* 2003;111(1):167-72; discussion 73.
  16. Zook EG, Guy RJ, Russell RC. A study of nail bed injuries: Causes, treatment, and prognosis. *The Journal of Hand Surgery.* 1984;9(2):247-52.
  17. Strauch B, de Moura W. Arterial system of the fingers. *J Hand Surg Am.* 1990;15(1):148-54.
  18. Allen MJ. Conservative Management of Finger Tip Injuries in Adults. *Hand.* 1980;os-12(3):257-65.
  19. Tupper J, Miller G. Sensitivity following volar V-Y plasty for fingertip amputations. *J Hand Surg Br.* 1985;10(2):183-4.