

# Rhomboid excision and Limberg flap operation for managing pilonidal sinus: our experience at Patan Hospital, Patan Academy of Health Sciences

Sanjaya Paudyal, Shanta Bir Maharjan, Niraj Giri, Samayukta K.C

Department of Surgery, Patan Hospital, Patan Academy of Health Sciences, Lalitpur, Nepal

**Correspondence:** Dr. Sanjaya Paudyal, Department of surgery, Patan Hospital, Patan Academy of Health Sciences, Lalitpur, Nepal

**Email:** sanpau3003@gmail.com

## Abstract

**Introduction:** Pilonidal sinus is a common disease. Various surgical techniques for management of sacrococcygeal pilonidal sinus have been described. Among them, the most commonly used is the rhomboid excision with the Limberg flap. With this technique of flattening the natal cleft and tension-free repair is made using a wide, well-vascularized flap. It is reported the best treatment methods, with 0-16 % of surgical area-related complications and a recurrence rate of 0-5 %. We conducted a study to evaluate the patient's profile and outcomes of the patients of pilonidal sinus treated with rhomboid excision and Limberg flap reconstruction at our center.

**Methods:** Data were recorded retrospectively by reviewing the charts of patients who underwent rhomboid excision and Limberg flap operation for sacrococcygeal pilonidal sinus from September 2015 to September 2019.

**Results:** Thirty-four patients were included in the study. Twenty-nine (85.4%) were males and 5 (14.7%) were females. The mean age was 25.29 years (range 17–40 years). Mean hospital stay was 4.5 days (range 3 – 7 days). Nine (26.5%) patients had surgical site infections. Two patients (5.9%) had a recurrence.

**Conclusion:** Limberg flap for reconstruction after rhomboid excision of pilonidal sinus is an effective and feasible technique with good outcome.

**Keywords:** Pilonidal Sinus; Limberg Flap; Sacrococcygeal Pilonidal Sinus

## Introduction

Pilonidal sinus is a common disease. It is usually found in the midline of the sacrococcygeal region of a young person who has an abundance of hair near natal cleft. It is an acquired condition with high morbidity and discomfort. The estimated incidence is 26 per 1,00,000 population.<sup>1,2</sup> It generally presents as a cyst, abscess or sinus tract with or without discharge.<sup>3</sup> Men affected more often than women.

Various surgical techniques for management of sacrococcygeal pilonidal sinus have been described which includes excision of the area and packing, excision and primary closure, marsupialization and flap techniques like

Limberg flap, modified Limberg transposition flap, elliptical rotation flap and rotation advancement fasciocutaneous flap.<sup>4-7</sup>

Among different surgical techniques for treatment of sacrococcygeal pilonidal sinus, flap reconstruction techniques eliminate the etiology by flattening the intergluteal sulcus with much less hairy fasciocutaneous flaps and less perspiration.<sup>8</sup> Among them, the most commonly used is the rhomboid excision with the Limberg flap. With this technique flattening the natal cleft and tension-free repair is made using a wide, well-vascularized flap. It is reported as one of the best treatment methods,

with a 0-16 % of surgical area-related complication and a recurrence rate of 0-5 %.<sup>9</sup>

Hence, we conducted a study to evaluate the patient's profile and outcomes of the patients of pilonidal sinus treated with rhomboid excision and Limberg flap reconstruction at our center.

## Methods

It is a retrospective study of patients who underwent rhomboid excision and Limberg flap operation for sacrococcygeal pilonidal sinus from September 2015 to September 2019. The medical record was retrieved by searching a hospital-based computer database using ICD 10 code "LO5". Data were recorded retrospectively by reviewing the charts. Patient demographics, duration of symptoms, presenting symptoms, previous incision and drainage of the pilonidal abscess, previous pilonidal surgery, hospital stay, the duration for final healing, surgical site infection (SSI), need for multiple dressing and second intervention like removal of suture and secondary suturing, follow up and recurrence were recorded.

SSI was recorded on the basis of follow up note stating erythematous wound, discharge of fluid from the wound, need for suture removal to drain the pus and need of repeated dressing.

Final healing was said when all the sutures were removed without any significant wound complications. (Fig 7)

Follow up note was reviewed at the time of suture removal and the last follow up date was recorded. Healing, wound complication and recurrence were recorded at last follow up.

Data were analyzed using SPSS 20. Continuous data were presented as mean with range and categorical data were presented as a percentage. Approval was taken from institutional review board.

## Procedure

The procedure was done under spinal anesthesia. The preoperative marking of the surgical site was done as shown in Figure 1.

The patient was put in a prone position with buttocks strapped apart by adhesive tapes and anchored to the side of the operating table. Figure 1

A line AC (C towards anal region) was drawn covering all midline pits. Another line BD (60% of the length of AC) was drawn at midpoint of AC at 90 degrees keeping both

sides equal in length. All points ABCD were joined to each other. By this method rhombic area is created in which one angle is 60 degree and another is 120 degrees. D-E is a direct continuation of the line B-D and is of equal length to the incision B-A, to which it will be sutured after rotation. E-F is parallel to D-C and of equal length. After rotation, it will be sutured to A-D. Fig 1.

Methylene blue was injected in the sinus tract with help of feeding tube to stain all the sinus tracts to avoid leaving behind of tract during excision. Figure 2.

The skin and subcutaneous tissue were incised by deepening along the marked lines down to the deep fascia. Rhomboid area of excised specimen included pilonidal sinus and it's all extensions. Fig 3. Then the flap is raised so that it includes skin, subcutaneous fat and the fascia overlying gluteus maximus, rotated to cover midline rhomboid defect. Figures 3 and 4. Deep absorbable sutures to include fascia and fat are placed over a vacuum drain, and then finally the skin is closed in interrupted sutures. Figure 5.

The operation produces a tension-free flap of unscarred skin in the midline. Figure 6. Injection cloxacillin was given to cover staphylococcus aureus as prophylaxis and from the next day continued in oral form for 7 days. The suction drain removed when drain output was minimal < 10 ml/day. Suture removal was on follow up based on the discretion of the operating surgeon. The patient was advised not to lie on his back until the wound acceptably healed.

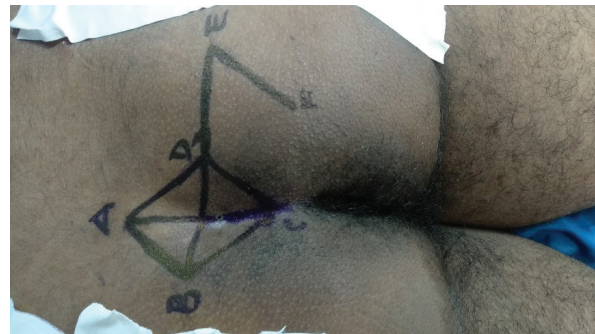

Figure 1: The preoperative marking of the surgical site

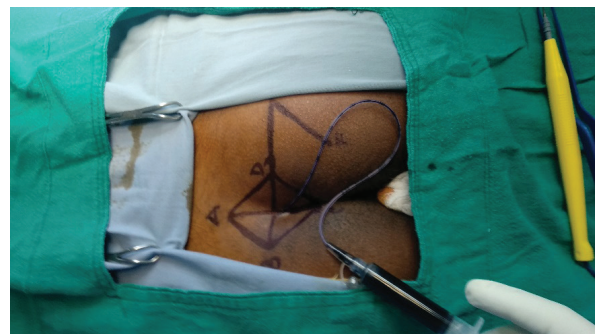
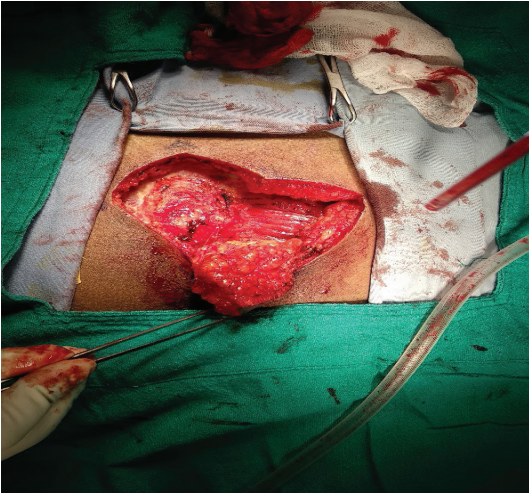
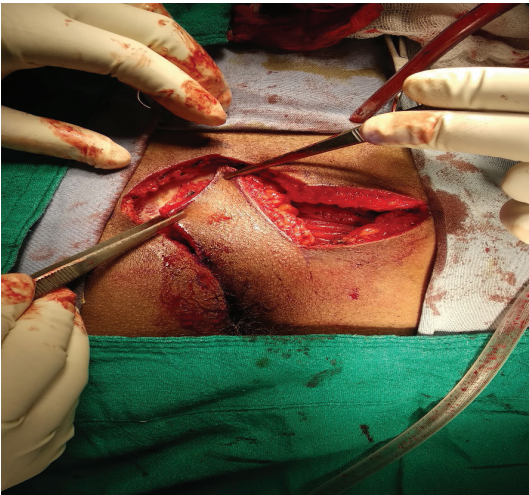


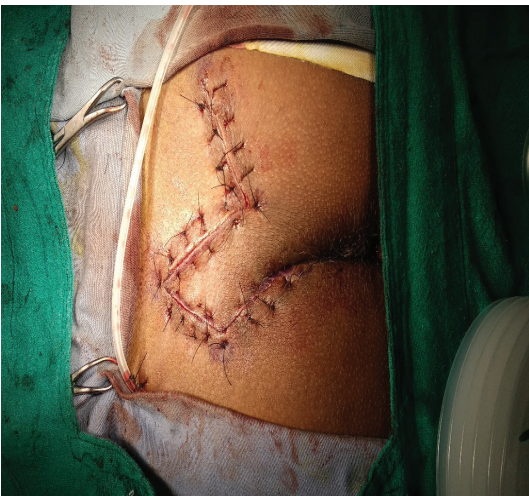Figure 2: Methylene blue injected in the sinus tract



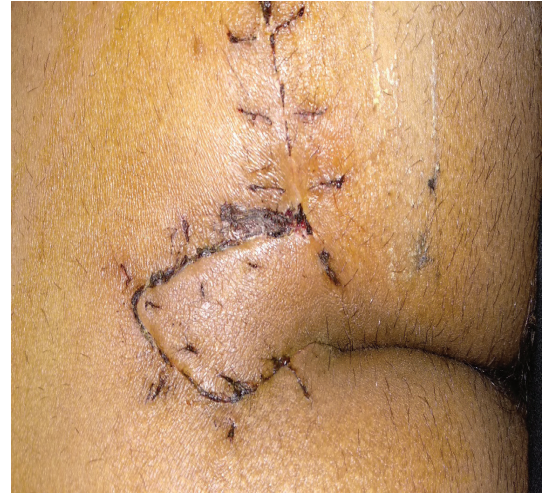**Figure 3: The flap is raised**



**Figure 4 : The flap is rotated to cover midline rhomboid defect**



**Figure 5: the skin is closed in interrupted sutures**



**Figure 6: Tension-free flap of unscarred skin in the midline**

## Results

Thirty-four patients were included in the study. Among them 29 (85.4%) were males and 5 (14.7%) were females. The mean age was 25.29 years (range 17–40 years). Of the 34 patients, 33 had a primary disease and one patient had recurrent disease. However, 13(38.2%) patients had a history of previous incision and drainage for abscess.

The most common presentation was discharging wounds in natal cleft seen in 17(50%) of patients. Table 1.

Mean hospital stay was 4.5 days (range 3 – 7 days). The mean duration for complete wound healing was 13.41 days (range 11- 21). Nine (26.5%) patients had surgical site infections. Four patients had early suture removal to drain the pus. These patients had repeated dressing changes until complete wound healing by secondary intention. None of the patients required delayed wound suturing.

Two patients (5.9%) had recurrence on the basis of continued discharge from small areas of wound even after healing of most areas of the wound. These two patients were lost to follow up.

**Table 1: Presenting symptoms**

Symptoms	Frequency	Percent
Swelling	2	5.9
Discharge	17	50.0
Pain + Swelling	1	2.9
Pain + Discharge	6	17.6
Swelling + Discharge	5	14.7
Pain, swelling, and discharge	3	8.8
Total	34	100.0

## Discussion

Pilonidal sinus is common in hirsute men. The presence of hair in the gluteal cleft seems to play a significant role in the pathogenesis of this disease. A deep natal cleft is a favorable environment for sweating, maceration, bacterial contamination and penetration of hairs. Other risk factors include obesity, local trauma or irritation, sedentary lifestyle, family history, and poor hygiene. It is widely accepted that a pilonidal sinus results from the penetration of shed hair shafts through the skin. This ultimately leads to an acute or chronically infected site.<sup>10</sup> Diagnosis is made by a clinical examination which reveals multiple pits in natal clefts and sinus in the various position.

Among various surgical operations, rhomboid excision and Limberg flap operation is a popular operation in recent years. This has several advantages as well as lower complications and recurrence rates. It is easy to perform and the natal cleft is flattened using the local vascularized flap. This flap operation avoids midline scar as compared to a procedure like simple excision and closure and marsupialization.<sup>11,12</sup>

Several series which reported about this technique for pilonidal sinus have been comparable with our series in terms of complications and recurrences. We had 26 % wound complications and a 5.9 % recurrence rate. Katsoulis did a study on 25 patients, with 4(16%) of them having complications with no recurrences.<sup>13</sup> Aslam reported 110 patients, with 5 of them having complications and 1 recurrence.<sup>14</sup> Mentis and Urhan reported 3% and 5 % recurrence respectively with good outcomes in all healed patients.<sup>15,16</sup>

There was a prominent male predominance in our study. Out of a total of 34 patients, 85% were male. Similar gender distributions are described in other studies. Surrel in 1994 reported male predominance by 3:1 and Can MF in 2010 reported 143 male vs 2 female in his RCT.<sup>10,17</sup> We had 26 % SSI, most of them only required local treatment with dressing and removal of sutures which ultimately healed without significant morbidity. Since this wound falls under contaminated to dirty wound and considering SSI rate of 17% for contaminated, and over 27% for dirty wound our wound infection rate is comparable.<sup>18,19</sup> However, Can MF reported 13% wound-related complications and A. Cihan in 2006 reported 22% wound infection in a classic rhomboid flap as compared to 26% SSI in our study.<sup>5,17</sup>

We had 2 (5.9%) recurrence at the follow up of 56 and 90 days. The patient could not be traced after this follow up and we were unable to gather information on their further treatment.

We changed our practice of managing Pilonidal sinus using this method in recent years. As per our experience, it is easy to manage a sutured wound than the open wound in other methods. Overall reduced healing time, reduced number of dressing change and fewer complication makes patient compliant to this procedure. This procedure is standardized and easy to teach and learn. The results are consistent with the different operating surgeons in our general surgical unit by following the same method by all the surgeons.

This study has certain limitations inherent in retrospective studies.

## Conclusion

Limberg flap for reconstruction after rhomboid excision of pilonidal sinus is an effective and feasible technique with good outcome.

## References

1. Humphries AE, Duncan JE. Evaluation and management of pilonidal disease. *Surg Clin North Am.* 2010 Feb;90(1):113-24.
2. Søndena K, Andersen E, Nesvik I, Søreide JA. Patient characteristics and symptoms in chronic pilonidal sinus disease. *Int J Colorectal Dis.* 1995;10(1):39-42.
3. Singh PK, Gohil RK, Saxena N. Limberg flap procedure for sacrococcygeal pilonidal sinus : a prospective study. *Int Surg J.* 2017 Jul;4(7):2238-42.
4. Eryilmaz R, Sahin M, Alimoglu O, Dasiran F. Surgical treatment of sacrococcygeal pilonidal sinus with the Limberg transposition flap. *Surgery.* 2003 Nov;134(5):745-9.
5. Cihan A, Ucan BH, Comert M, Cesur A, Cakmak GK, Tascilar O. Superiority of asymmetric modified Limberg flap for surgical treatment of pilonidal disease. *Dis Colon Rectum.* 2006 Feb;49(2):244-9.
6. Neşşar G, Kayaalp C, Seven C. Elliptical rotation flap for pilonidal sinus. *Am J Surg.* 2004 Feb;187(2):300-3.
7. Schoeller T, Wechselberger G, Otto A, Papp C. Definite surgical treatment of complicated recurrent pilonidal disease with a modified fasciocutaneous V-Y advancement flap. *Surgery.* 1997 Mar;121(3):258-63.
8. Khatri VP, Espinosa MH, Amin AK. Management of recurrent pilonidal sinus by simple V-Y fasciocutaneous flap. *Dis Colon Rectum.* 1994 Dec;37(12):1232-5.

9. Topgül K. Surgical treatment of sacrococcygeal pilonidal sinus with rhomboid flap. *J Eur Acad Dermatology Venereol.* 2010 Sep;24(1):7–12.
10. Surrell JA. Pilonidal disease. *Surg Clin North Am.* 1994 Dec;74(6):1309-15.
11. Akca T, Colak T, Ustunsoy B, Kanik A, Aydin S. Randomized clinical trial comparing primary closure with the Limberg flap in the treatment of primary sacrococcygeal pilonidal disease. *Br J Surg.* 2005 Sep;92(9):1081-4.
12. Azab ASG, Kamal MS, Saad RA, Abou Al Atta KA, Ali NA. Radical cure of pilonidal sinus by a transposition rhomboid flap. *Br J Surg.* 1984 Feb;71(2):154–5.
13. Katsoulis IE, Hibberts F, Carapeti EA. Outcome of treatment of primary and recurrent pilonidal sinuses with the Limberg flap. *Surgeon.* 2006 Feb;4(1):7–10, 62.
14. Aslam MN, Shoaib S, Choudhry AM. Use of Limberg flap for pilonidal sinus--a viable option. *J Ayub Med Coll Abbottabad.* 2009 Oct;21(4):31–3.
15. Mentés O, Bağcı M, Bilgin T, Özgül O, Özdemir M. Limberg flap procedure for pilonidal sinus disease: Results of 353 patients. *Langenbeck's Arch Surg.* 2008 Mar;393(2):185–9.
16. Urhan MK, Küçükkel F, Topgul K, Özer İ, Sari S. Rhomboid Excision and Limberg Flap for Managing Pilonidal Sinus. *Dis Colon Rectum.* 2002 May;45(5):656–9.
17. Can MF, Sevinc MM, Hancerliogullari O, Yilmaz M, Yagci G. Multicenter prospective randomized trial comparing modified Limberg flap transposition and Karydakís flap reconstruction in patients with sacrococcygeal pilonidal disease. *Am J Surg.* 2010 Sep;200(3):318–27.
18. Garner JS. CDC guideline for prevention of surgical wound infections, 1985. Supersedes guideline for prevention of surgical wound infections published in 1982. (Originally published in November 1985). Revised. *Infect Control.* 1986 Mar;7(3):193–200.
19. Mioton LM, Jordan SW, Hanwright PJ, Bilimoria KY, Kim JYS. The relationship between preoperative wound classification and postoperative infection: A multi-institutional analysis of 15,289 patients. *Arch Plast Surg.* 2013;40(5):522–9.