



Original Article

# Mucinous Lesions of the Appendix: A Histopathological Study

Oshan Shrestha<sup>1</sup>, Reetu Sharma Baral<sup>1</sup>

<sup>1</sup>Department of Pathology, Nobel Medical College and Teaching Hospital, Biratnagar, Nepal

## Keywords:

Appendix;  
Mucinous neoplasm;  
Neoplastic mimics;

## ABSTRACT

**Background:** Mucinous lesions of the appendix are frequently misinterpreted in histopathological examination due to their relative rarity. Our study focuses on interpreting the histopathological spectrum of such lesions and understanding the disease burden of appendiceal mucinous lesions in a tertiary centre.

**Materials and Methods:** This was a retrospective cross-sectional study conducted in the Department of Pathology. Gross and microscopic findings of appendectomy specimens with mucinous lesions were analysed and classified according to the latest WHO 2019 recommendation.

**Results:** Seven hundred and forty appendectomy specimens were received during the study period out of which nine appendix (1.2%) had mucinous lesions. Five (55.6%) of these lesions had a mucinous neoplasm while four of them (44.4%) were non-neoplastic. The most common lesion was low-grade appendiceal mucinous neoplasm (n=4; 44.4%). Two cases (22.2%) were retention cysts and there was one case each of mucinous adenocarcinoma, appendiceal diverticulosis, and endometriosis-associated mucinous metaplasia of the appendix. The mucinous neoplasms were significantly more common in females (80%). High-grade appendiceal mucinous neoplasms and serrated lesions or polyps weren't seen in our study.

**Conclusion:** Mucinous lesions of the appendix are often incidental findings in patients operated for symptoms of acute appendicitis. Low-grade appendiceal mucinous neoplasms are the most common among them. Thorough knowledge of the neoplastic mimics and careful gross, as well as microscopic examination, is a must for proper diagnosis and staging since it has a significant impact on further patient management and prognostication.

## Correspondence:

Dr. Oshan Shrestha, MD

Lecturer, Department of Pathology,  
Nobel Medical College and Teaching Hospital,  
Kathmandu University, Biratnagar, Nepal.

ORCID Id: 0000-0003-1654-6107

Email: oshanpgi@gmail.com



Received : August 24<sup>th</sup> 2021 ; Accepted : March 25<sup>th</sup> 2022

**Citation:** Shrestha O, Baral R. Mucinous Lesions of the Appendix: A Histopathological Study. J Pathol Nep 2022;12(1):1893-99. DOI: 10.3126/jpn.v12i1.39338

**Copyright:** This is an open-access article distributed under the terms of the Creative Commons Attribution 4.0 International License, which permits unrestricted use, distribution, and reproduction in any medium, provided the original author and source are credited.

## INTRODUCTION

Mucinous lesions of the appendix are rare, usually incidental entities identified in appendectomy specimens. These lesions can range from simple mucocoeles (retention cysts) to various neoplastic lesions.<sup>1-6</sup> According to the WHO 5th edition (2019), low-grade appendiceal mucinous neoplasms (LAMN), high grade appendiceal mucinous neoplasms (HAMN), and mucinous adenocarcinoma of the appendix comprise the neoplastic spectrum.<sup>7</sup> Retention cysts, appendiceal endometriosis with intestinal metaplasia, and diverticulosis associated mucinous metaplasia of the appendix are amongst the non-neoplastic mucinous lesions and can mimic a mucinous neoplasm, particularly LAMN.<sup>8-11</sup>

The mucinous appendiceal lesions do not have a specific clinical or imaging presentation and the patients are frequently operated on for symptoms resembling acute appendicitis.<sup>12</sup> Categorisation of the mucinous neoplasm with attention to extent of mucin and neoplastic cells in the appendectomy specimen is crucial to stage the disease as well as assess the risk of pseudomyxoma peritonei (PMP), a dreaded complication with poor prognosis.<sup>13,14</sup>

Thorough knowledge of the mimics of mucinous neoplasm of the appendix with detailed gross and microscopic examination is thus essential. The present study is undertaken to study the disease burden of the mucinous lesions amongst appendectomy specimens with detailed documentation of the gross and histological findings of all the cases, thus offering a specific diagnosis and staging them accordingly. This will have a major role in better understanding these relatively unrecognized lesions, managing them as well as predicting their future course.

## MATERIAL AND METHODS

This was a retrospective cross-sectional study performed in the Department of Pathology at Nobel Medical College, Biratnagar, Nepal. This study was conducted in the appendectomy specimens received over a period of two years from April 2019 to April 2021. All surgically managed appendicular lesions demonstrating a mucinous lesion in histopathological examination during the study period were included in the study while appendectomy specimens without such mucinous lining were excluded.

The specimens were fixed in 10% neutral buffered formalin. Gross details for the presence of mucin in the lumen and its extension to the wall or outside the appendix were done. The gross and microscopic findings were reviewed by two Pathologists. The diagnoses were revised if needed. Histologic categorization and staging was done according to World Health Organization (WHO 5th edition, 2019) guidelines and recommendation in the American Joint Committee on Cancer (AJCC) 8th edition.<sup>15</sup>

## RESULTS

Mucinous lesions of the appendix comprised only 1.2% (9/740) of the appendectomy specimens examined. The mucinous neoplasm was identified in five cases (55.6%) while four (44.4%) were non-neoplastic. The mucinous neoplasms were more common in females (80%). Seven of the nine cases of mucinous lesions presented with symptoms of abdominal pain. Non-neoplastic lesions were identified in the younger age group (mean 51.2 years) as compared to the neoplastic cases (mean 65.4 years).

Among the four non-neoplastic cases, two (22.2%) were retention cysts, one was appendiceal diverticulosis and

the other was appendiceal endometriosis with intestinal metaplasia. Both cases of retention cysts, including the single case of appendiceal diverticulosis, were identified, presented with symptoms of acute appendicitis, and showed dilated mucin-filled lumen. A case of endometriosis-associated intestinal metaplasia was also seen and it presented with an obliterated lumen (fig. 1).

Low grade appendiceal mucinous neoplasm was the most common mucinous lesion with four cases (44.4%) and in all of them, the mucin was confined to the muscularis propria thus staged as Tis according to the AJCC 8th edition (fig. 2). One of these four LAMN cases presented with intussusception with the base of the dilated appendix being the intussusceptum. Two of them were reported as mucocoeles in ultrasound examination and the last remaining case was suspected as acute appendicitis.

There was one case of grade 2 mucinous adenocarcinoma, stage pT3 and it presented with severe anaemia and appendicular mass in imaging with a clinical query of appendiceal mucinous adenocarcinoma. Solid nodular luminal mass and traversing mucin was identified in this case (fig. 3).

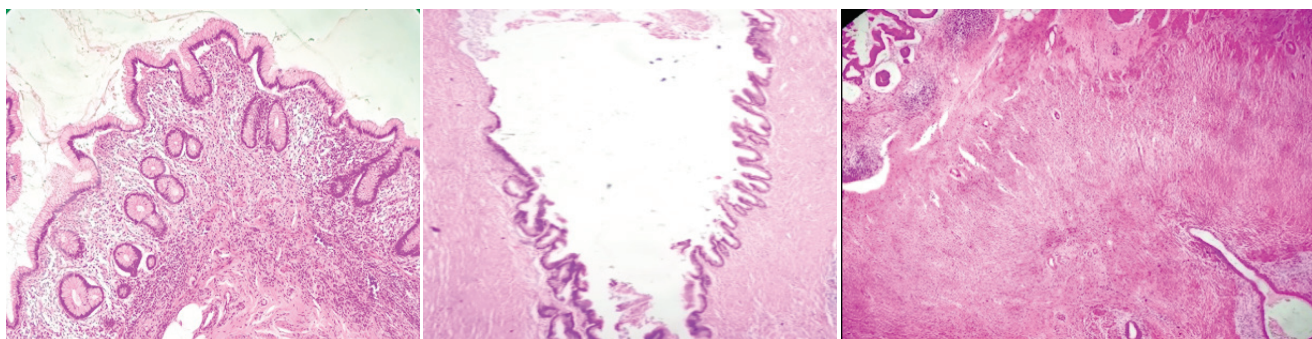
High grade appendiceal mucinous neoplasms and serrated lesions or polyps weren't seen in our study. None of the patients presented with PMP. All the mucinous lesions observed are summarized in Table 1.

## DISCUSSION

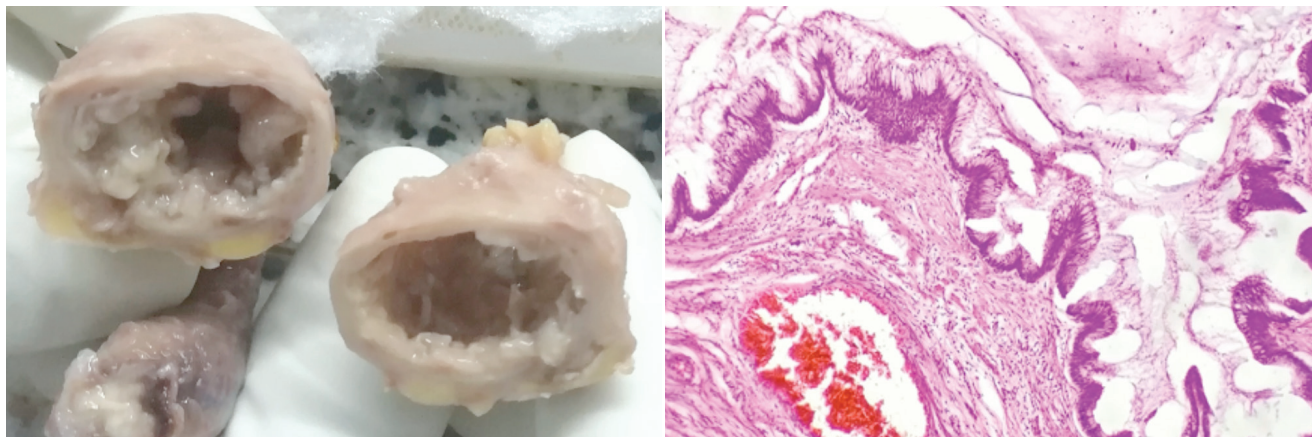
Mucocoeles denote grossly dilated mucus-filled appendix and can result from obstruction of appendiceal ostium due to mucus, mucous hyperplasia, benign and malignant lesions. It isn't pathological terminology and the definite diagnosis can range from a simple retention cyst to a mucinous neoplasm of the appendix. Various conditions involving the appendix like diverticulosis, endometriosis, and retention cysts are identified in our study and can pose a diagnostic challenge since they closely mimic a mucinous neoplasm for inexperienced eyes.

Mucinous lesions accounted for 1.2% of cases in our study which is in accordance with other studies where they comprised 0.2 to 0.8% of appendectomy specimens.<sup>1-6</sup> There was a significant female predominance in our study with male to female ratio being 1:2. This finding is also similar to other studies performed.<sup>6,16</sup> A study by Carr et al however had a male to female ratio of 5:2 in their study.<sup>17</sup> Neoplastic lesions occurred in older age group than non-neoplastic ones as also observed in another study.<sup>6</sup>

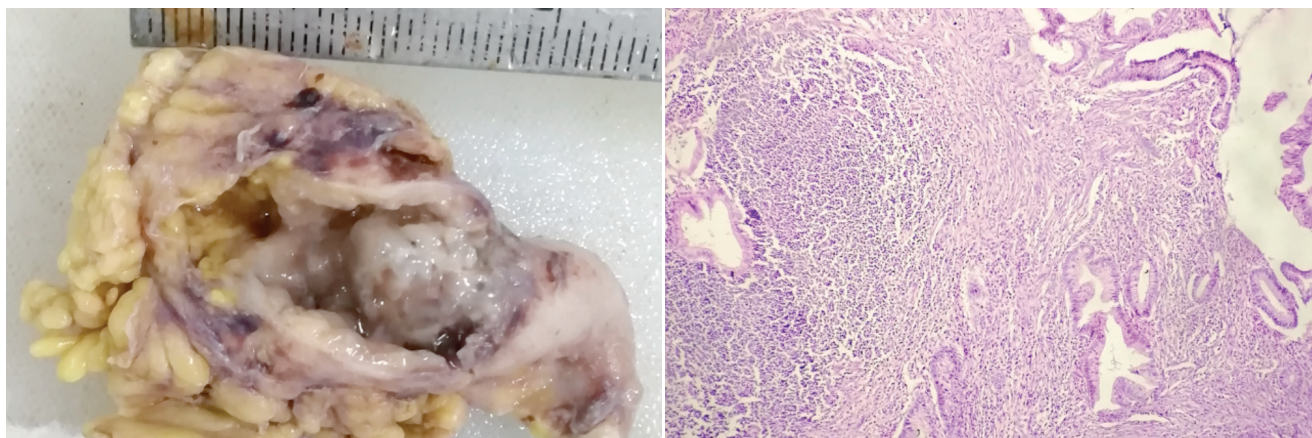
Patients with appendiceal mucinous lesions can present with non-specific clinical symptoms.<sup>12</sup> The most common clinical presentation was abdominal pain with a pre-



**Figure 1:** (A) Retention cyst showing mucinous epithelium and preserved lamina propria with crypts; (B) Appendiceal diverticulosis with mucinous lining; (C) endometriosis-associated mucinous metaplasia with two endometriotic foci at lower right and metaplastic mucinous epithelium at upper left (H and E stain, 4x)



**Figure 2:** LAMN: Dilated appendiceal lumen with mucinous contents in lumen (A); undulating intestinal-type mucinous appendiceal lining with mucin in the luminal aspect and loss of lamina propria (B)



**Figure 3:** Mucinous adenocarcinoma, grade 2: Grossly dilated appendix with solid nodular mucinous growth in the lumen (A); microscopy showing irregular invasive complex glands with hyperchromatic atypical mucinous lining epithelium and surrounding desmoplasia (B)

operative diagnosis of acute appendicitis in six cases (66.7%). A similar observation was noted in other studies.<sup>6,18</sup> Abdominal mass, intussusception was also a pre-operative diagnosis in one case each that turned out to be endometriosis-associated neoplasia and LAMN, stage Tis respectively. Thus, the clinical presentation in the mucinous lesions appeared to be non-specific in our study making pre-operative diagnosis difficult in these cases. CT scan was obtained from one of the cases where a pre-operative

diagnosis of mucinous adenocarcinoma was in agreement with the histopathological diagnosis too.

The most common non-neoplastic entity in our study was a simple retention cyst that showed flattened mucinous lining epithelium with no atypia. They were detected in ultrasonography as well and the histology showed preserved lamina propria and normal crypt architecture with no other abnormalities. Appendicectomy is curative and there are no

**Table 1: Summary of appendiceal mucinous lesions in the study**

Age (years)	Sex	Clinical diagnosis	Gross findings	Microscopy
48	F	Ileocecal mass	Obliterated appendix, fibrofatty ileocaecal lump	Endometriosis associated mucinous metaplasia
70	F	Mucocele	Fragmented, dilated appendix	Appendiceal diverticulosis
52	M	Acute appendicitis	Dilated appendix with luminal mucin	Retention cyst
35	M	Acute appendicitis	Dilated appendix with luminal mucin	Retention cyst
73	F	Mucocele	Dilated appendix with luminal mucin	LAMN, stage Tis
54	F	Mucocele	Dilated appendix with luminal mucin	LAMN, stage Tis
52	F	Acute appendicitis	Dilated appendix with luminal mucin	LAMN, stage Tis
76	M	Intussusception / ? Carcinoma	Dilated appendix with luminal mucin, base as an intussusceptum	LAMN, stage Tis
72	F	Mucinous adenocarcinoma	Dilated appendix with mural nodule, ulcerated mucosa and traversing mucin	Grade 2 mucinous adenocarcinoma, stage pT3

recurrences or progression of the disease.<sup>19</sup>

Endometriosis was observed in only one case (0.13%) and presented as an ileocaecal mass. A study by Yantis et al and Emre et al also found the incidence of endometriosis to be 0.36% and 0.61% respectively.<sup>20,21</sup> Recognising this entity is necessary because of the potential for misdiagnosing it as a LAMN which it mimics clinically as well as histologically.<sup>8</sup> Tipps et al have also observed the presence of intestinal metaplasia in a focus of endometriosis can be mistaken for mucinous adenocarcinoma histologically.<sup>9</sup> There have been reports demonstrating the co-existence of intestinal-type metaplasia and LAMN 22 and thus the possible correlation between these two entities needs further studies.

Appendiceal diverticulosis is also a mimicker of LAMN and was seen in one of our nine cases. Features like retention of the normal lamina propria in the herniated mucosa, maintained crypt architecture, epithelial hyperplasia and lack of nuclear abnormalities favour a non-neoplastic entity.<sup>23,24</sup> This is important to distinguish as there is no risk of intraperitoneal dissemination with PMP in diverticulosis, unlike LAMNs which might need further interventions according to the extent of disease.<sup>25</sup> Valasek et al<sup>10</sup> and Arnold et al<sup>11</sup> have found that there is a high degree of misdiagnosis of these lesions as LAMN by the referring pathologists.

LAMNs comprised 0.5% (4/740) of the appendicectomy specimens which is similar to the incidence of ~0.3% in other studies.<sup>13,14</sup> Three of the four LAMN cases in our study (75%) were in females. Intussusception with small bowel obstruction, volvulus, ureteral obstruction, and pseudomyxoma peritonei are known possible complications of LAMN.<sup>13,14</sup> Except for a case of intussusception, none of our LAMN cases had complications.

All the LAMN cases showed grossly dilated appendiceal lumen filled with mucin and thinned out the wall. The

microscopy showed circumferential involvement of the appendix by flat or undulating mucinous epithelial cells with low-grade dysplasia. Pushing type of invasion into the muscularis propria was seen in two cases. There was a complete absence of normal crypts and obliteration of lamina propria thus qualifying for LAMN.<sup>26-35</sup> All the LAMN cases showed the mucinous epithelium and/or mucin limited to the muscularis propria and were staged as Tis. The prognosis of stage Tis LAMN is excellent while those with peritoneal dissemination have a variable prognosis<sup>29,33,35</sup> depending on the extent of disease, grade of the mucinous epithelium, and response to therapy.<sup>36,37</sup> Owing to the prognostic significance, it is necessary to distinguish extra-appendiceal mucin from artifact due to contamination by gross manipulation. The presence of tissue reactions like capillary and granulation tissue in-growth, mesothelial hyperplasia, and dystrophic calcifications around the mucin distinguishes it from an artifact.<sup>30,34</sup> Moreover, Young et al have found that the presence or absence of neoplastic cells in the peritoneal mucinous deposits co-relates strongly with tumor recurrence. Only 20% of cases with acellular peritoneal mucin developed recurrence while 66.7% cases with cellular peritoneal mucin developed tumor recurrence in their study.<sup>38</sup>

HAMNs are similar to LAMNs except for the high-grade atypia as defined by loss of polarity, high nuclear: cytoplasmic ratio, glandular complexity, prominent nucleoli, and/or increased mitotic figures.<sup>33</sup> HAMNs are rare and no cases were identified in our study. Owing to limited data, their behaviour when confined to the appendix is uncertain.

A single case of grade 2 mucinous adenocarcinoma was identified amounting to 0.1% (1/740) of the appendicectomy specimens. Collins et al also reported the incidence to be 0.082% in their study where they examined 50,000 appendices.<sup>39</sup> Studies show that these malignancies arise commonly in the 5<sup>th</sup> to 7<sup>th</sup> decades 33 with more incidence

in males.<sup>41</sup> However, one other study showed a female predominance.<sup>42</sup> Our only case presented at 72 years of age and was a female. The histology showed irregular angulated complex glands lined by columnar cells with atypical hyperchromatic nuclei as well as single cells that were infiltrating the underlying wall and exhibiting a surrounding desmoplastic response. These fare a dismal prognosis with 5 years survival rate from 19% to 55%.<sup>42,43</sup>

## CONCLUSIONS

Mucinous lesions of the appendix are rare but important entities due to the neoplastic potential of some. They are more common in females and range from simple retention cysts to mucinous adenocarcinomas. Pre-operative diagnosis is difficult in most cases. A gross examination can provide a clue while a definite diagnosis requires meticulous histopathological interpretation. Sound knowledge of the mucin artifacts and various non-neoplastic mimics is essential to prevent overdiagnosis as a mucinous neoplasm. Proper histological staging, especially of the LAMNs, plays a crucial role in prognostication and guiding further management.

## Acknowledgement

Authors would like to thank Mrs. Lata Bishwas and Mrs. Srijana Tabdar for her help during sample collection.

**Conflict of interest:** None

## REFERENCES

- Higa E, Rosai J, Pizzimbono CA, Wise L. Mucosal hyperplasia, mucinous cystadenoma, and mucinous cystadenocarcinoma of the appendix. A re-evaluation of appendiceal 'mucocele'. *Cancer*. 1973;32(6):1525–41. [Crossref](#)
- Marudanayagam R, Williams GT, Rees BI. Review of the pathological results of 2660 appendectomy specimens. *J Gastroenterol*. 2006;41(8):745–9. [Crossref](#)
- Ruiz-Tovar J, Teruel DG, Castiñeiras VM, Dehesa AS, Quindós PL, Molina EM. Mucocele of the appendix. *World J Surg*. 2007;31(3):542–8. [Crossref](#)
- Smeenk RM, van Velthuysen MLF, Verwaal VJ, Zoetmulder F a. N. Appendiceal neoplasms and pseudomyxoma peritonei: a population based study. *Eur J Surg Oncol J Eur Soc Surg Oncol Br Assoc Surg Oncol*. 2008;34(2):196–201. [Crossref](#)
- Yakan S, Caliskan C, Uguz A, Korkut M, Çoker A, Uguz A, et al. A Retrospective Study on Mucocele of the Appendix Presented with Acute Abdomen or Acute Appendicitis. *Hong Kong J Emerg Med*. 2011;18. [Crossref](#)
- Geetha C, Farheen A, Deshpande AK. Histopathologic study of Mucinous lesions of the appendix. *IP Arch Cytol Histopathol Res*. 5(1):41. [Crossref](#)
- Board WC of TE. Digestive System Tumours [Internet]. [cited 2021 Jun 19]. [Website](#)
- Misdraji J, Lauwers GY, Irving JA, Batts KP, Young RH. Appendiceal or cecal endometriosis with intestinal metaplasia: a potential mimic of appendiceal mucinous neoplasms. *Am J SurgPathol*. 2014;38(5):698–705. [Crossref](#)
- Tipps AMP, Weidner N. Colonization of intestinal endometriosis by benign colonic mucosa: a pattern potentially misdiagnosed as invasive mucinous carcinoma. *Int J SurgPathol*. 2011;19(2):259–62. [Crossref](#)
- Valasek MA, Thung I, Gollapalle E, Hodkoff AA, Kelly KJ, Baumgartner JM, et al. Overinterpretation is common in pathological diagnosis of appendix cancer during patient referral for oncologic care. *PLoS ONE*. 2017 7;12(6):e0179216. [Crossref](#)
- Arnold CA, Graham RP, Jain D, Kakar S, Lam-Himlin DM, Naini BV, et al. Knowledge gaps in the appendix: a multi-institutional study from seven academic centers. *Mod Pathol Off J U S Can AcadPathol Inc*. 2019;32(7):988–96. [Crossref](#)
- Sugarbaker PH. New standard of care for appendiceal epithelial neoplasms and pseudomyxoma peritonei syndrome? *Lancet Oncol*. 2006;7(1):69–76. [Crossref](#)
- Ramaswamy V. Pathology of Mucinous Appendiceal Tumors and Pseudomyxoma Peritonei. *Indian J SurgOncol*. 2016;7(2):258–67. [Crossref](#)
- Padmanaban V, Morano WF, Gleeson E, Aggarwal A, Mapow BL, Stein DE, et al. Incidentally discovered low-grade appendiceal mucinous neoplasm: a precursor to pseudomyxoma peritonei. *Clin Case Rep*. 2016;4(12):1112–6. [Crossref](#)
- Amin MB, Edge S, Greene F, Byrd DR, Brookland RK, Washington MK, et al., editors. *AJCC Cancer Staging Manual* [Internet]. 8th ed. Springer International Publishing; 2017 [cited 2021 Jun 20]. [Crossref](#)
- Pickhardt PJ, Levy AD, Rohrmann CA, Kende AI. Primary neoplasms of the appendix: radiologic spectrum of disease with pathologic correlation. *Radiogr Rev PublRadiolSoc N Am Inc*. 2003;23(3):645–62. [Crossref](#)
- Carr NJ, McCarthy WF, Sobin LH. Epithelial noncarcinoid tumors and tumor-like lesions of the appendix. A clinicopathologic study of 184 patients with a multivariate analysis of prognostic factors. *Cancer*. 1995 1;75(3):757–68. [Crossref](#)
- Emre A, Sertkaya M, Kale İT. Clinicopathological analysis of appendiceal mucinous tumors: A single-center experience. *Turk J Surg*. 2017;33(4):274–8. [Crossref](#)

19. Rabie ME, Al Shraim M, Al Skaini MS, Alqahtani S, El Hakeem I, Al Qahtani AS, et al. Mucus Containing Cystic Lesions “Mucocele” of the Appendix: The Unresolved Issues. *Int J Surg Oncol*. 2015;2015:e139461. [Crossref](#)
20. Yantiss RK, Clement PB, Young RH. Endometriosis of the intestinal tract: a study of 44 cases of a disease that may cause diverse challenges in clinical and pathologic evaluation. *Am J Surg Pathol*. 2001;25(4):445–54. [Crossref](#)
21. Emre A, Akbulut S, Bozdag Z, Yilmaz M, Kanlioz M, Emre R, et al. Routine histopathologic examination of appendectomy specimens: retrospective analysis of 1255 patients. *Int Surg*. 2013;98(4):354–62. [Crossref](#)
22. Libbrecht L, Snauwaert C, De Vos M, Geboes K, Cuvelier C, Ferdinande L. Intestinal metaplasia and colonization of endometriosis in a case of an appendiceal mucinous neoplasm. *Virchows Arch Int J Pathol*. 2012;461(2):227–9. [Crossref](#)
23. Lowes H, Rowaiye B, Carr NJ, Shepherd NA. Complicated appendiceal diverticulosis versus low-grade appendiceal mucinous neoplasms: a major diagnostic dilemma. *Histopathology*. 2019;75(4):478–85. [Crossref](#)
24. Hissong E, Goncharuk T, Song W, Yantiss RK. Post-inflammatory mucosal hyperplasia and appendiceal diverticula simulate features of low-grade appendiceal mucinous neoplasms. *Mod Pathol Off J U S Can Acad Pathol Inc*. 2020 May;33(5):953–61. [Crossref](#)
25. Hsu M, Young RH, Misdraji J. Ruptured appendiceal diverticula mimicking low-grade appendiceal mucinous neoplasms. *Am J Surg Pathol*. 2009;33(10):1515–21. [Crossref](#)
26. Carr NJ, Bibeau F, Bradley RF, Dartigues P, Feakins RM, Geisinger KR, et al. The histopathological classification, diagnosis and differential diagnosis of mucinous appendiceal neoplasms, appendiceal adenocarcinomas and pseudomyxoma peritonei. *Histopathology*. 2017;71(6):847–58. [Crossref](#)
27. Misdraji J. Mucinous epithelial neoplasms of the appendix and pseudomyxoma peritonei. *Mod Pathol Off J U S Can Acad Pathol Inc*. 2015;28Suppl 1:S67-79. [Crossref](#)
28. Misdraji J, Yantiss RK, Graeme-Cook FM, Balis UJ, Young RH. Appendiceal mucinous neoplasms: a clinicopathologic analysis of 107 cases. *Am J Surg Pathol*. 2003;27(8):1089–103. [Crossref](#)
29. Pai RK, Beck AH, Norton JA, Longacre TA. Appendiceal mucinous neoplasms: clinicopathologic study of 116 cases with analysis of factors predicting recurrence. *Am J Surg Pathol*. 2009;33(10):1425–39. [Crossref](#)
30. Valasek MA, Pai RK. An Update on the Diagnosis, Grading, and Staging of Appendiceal Mucinous Neoplasms. *Adv Anat Pathol*. 2018;25(1):38–60. [Crossref](#)
31. Bellizzi AM, Rock J, Marsh WL, Frankel WL. Serrated lesions of the appendix: a morphologic and immunohistochemical appraisal. *Am J Clin Pathol*. 2010;133(4):623–32. [Crossref](#)
32. Yantiss RK, Panczykowski A, Misdraji J, Hahn HP, Odze RD, Rennert H, et al. A comprehensive study of nondysplastic and dysplastic serrated polyps of the vermiform appendix. *Am J Surg Pathol*. 2007;31(11):1742–53. [Crossref](#)
33. Carr NJ, Cecil TD, Mohamed F, Sobin LH, Sugarbaker PH, González-Moreno S, Taflampas P, Chapman S, Moran BJ, Peritoneal Surface Oncology Group International. A Consensus for Classification and Pathologic Reporting of Pseudomyxoma Peritonei and Associated Appendiceal Neoplasia: The Results of the Peritoneal Surface Oncology Group International (PSOGI) Modified Delphi Process. *Am J Surg Pathol*. 2016;40(1):14-26. [Website](#)
34. Umetsu SE, Shafizadeh N, Kakar S. Grading and staging mucinous neoplasms of the appendix: a case series and review of the literature. *Hum Pathol*. 2017;69:81–9. [Crossref](#)
35. Yantiss RK, Shia J, Klimstra DS, Hahn HP, Odze RD, Misdraji J. Prognostic significance of localized extra-appendiceal mucin deposition in appendiceal mucinous neoplasms. *Am J Surg Pathol*. 2009;33(2):248-55. [Crossref](#)
36. Ronnett BM, Yan H, Kurman RJ, Shmookler BM, Wu L, Sugarbaker PH. Patients with pseudomyxoma peritonei associated with disseminated peritoneal adenomucinosis have a significantly more favorable prognosis than patients with peritoneal mucinous carcinomatosis. *Cancer*. 2001;92(1):85–91. [Crossref](#)
37. Bradley RF, Stewart JH, Russell GB, Levine EA, Geisinger KR. Pseudomyxoma peritonei of appendiceal origin: a clinicopathologic analysis of 101 patients uniformly treated at a single institution, with literature review. *Am J Surg Pathol*. 2006;30(5):551–9. [Crossref](#)
38. Young RH, Gilks CB, Scully RE. Mucinous tumors of the appendix associated with mucinous tumors of the ovary and pseudomyxoma peritonei. A clinicopathological analysis of 22 cases supporting an origin in the appendix. *Am J Surg Pathol*. 1991;15(5):415–29. [Crossref](#)
39. Collins DC. A study of 50,000 specimens of the human vermiform appendix. *Surg Gynecol Obstet*. 1955;101(4):437–45. [Website](#)
40. Cerame MA. A 25-year review of adenocarcinoma of the appendix. A frequently perforating carcinoma. *Dis Colon Rectum*. 1988;31(2):145–50. [Crossref](#)
41. Proulx GM, Willett CG, Daley W, Shellito PC. Appendiceal carcinoma: patterns of failure following surgery and implications for adjuvant therapy. *J Surg Oncol*. 1997;66(1):51–3. [Crossref](#)
42. Nitecki SS, Wolff BG, Schlinkert R, Sarr MG. The natural history of surgically treated primary adenocarcinoma of the appendix. *Ann Surg*. 1994;219(1):51–7. [Crossref](#)

43. Chang P, Attiyeh FF. Adenocarcinoma of the appendix. Dis Colon Rectum. 1981;24(3):176–80. [Crossref](#)