



Original Article

Evaluating intraoperative cytology with histopathology diagnosis and its importance in ovarian tumors

Karishma Malla Vaidya¹, Bigya Shrestha^{1,4}, Runa Jha², Binit Shrestha¹, Aasiya Rajbhandari¹, Rizuta Joshi³, Kritipal Subedi³

¹Department of Pathology, Paropakar Maternity and Women's Hospital, Kathmandu, Nepal

²National Public Health Laboratory, Kathmandu, Nepal

³Department of Obstetrician and Gynecology, Paropakar Maternity and Women's Hospital, Kathmandu, Nepal

⁴Department of Pathology, Hospital for Advanced Medicine and Surgery, Kathmandu, Nepal

ABSTRACT

Keywords:

Histology diagnosis;
Intraoperative diagnosis;
Ovarian neoplasm;
Touch imprint;

Background: Touch /imprint cytology has been utilized for intraoperative evaluations of tumors to complement frozen sections in order to reach diagnosis prior to histopathology diagnosis. The main aim of this study is to find role of touch imprint in determining histopathology diagnosis of ovarian neoplasm.

Materials and Methods: All together one hundred three cases were evaluated using both touch/imprint and histopathology diagnosis. The histopathology diagnoses consisted of Benign (n=85), borderline (n=4), and malignant (n=12). Touch imprint cytology consists of Negative for malignancy (n=90), Positive for malignancy (n=11) and inadequate (n=2). Inadequate smear was excluded from the study.

Results: Both touch / imprint cytology were able to diagnose benign and malignant ovarian neoplasm. Out of 103 cases, in cytology showed 89.1% patients were negative and 10.9% patients were positive. Histopathology shows 84.2% of benign ovarian neoplasm, 3.9% borderline neoplasm and 11.9% of malignant. Diagnostic accuracy of touch/ imprint was 99% with sensitivity 100% and specificity was 91.67%. Positive predictive value was 98.89% and negative predictive value was 100%.

Conclusion: Touch/ imprint cytology examination is simple, rapid and useful test in evaluation of ovarian neoplasms. It plays very important role in preliminary intraoperative diagnosis of benign and malignant ovarian neoplasms.

Correspondence:

Dr. Karishma Malla Vaidya, MBBS, MD

Sr Consultant, Department of Pathology,

Paropakar Maternity and Women's Hospital, Kathmandu, Nepal

ORCID ID: 000-0002-5035-9631

Email: rupkari@yahoo.com



Received : February 5th 2020 ; Accepted : March 6th 2020

Citation: Vaidya KM, Shrestha B, Jha R, Shrestha B, Rajbhandari A, Joshi R, Subedi K. Evaluating cytology with histopathology diagnosis and its importance in ovarian tumors. J Pathol Nep 2020;10:1630-4 DOI: 10.3126/jpn.v10i1.27551

Copyright: This is an open-access article distributed under the terms of the Creative Commons Attribution 4.0 International License, which permits unrestricted use, distribution, and reproduction in any medium, provided the original author and source are credited.

INTRODUCTION

Dudgeon and Patrick from London developed a simple method to obtain rapid diagnosis of freshly cut specimens, in 1927.¹ Popularity of touch imprint has increased in cytopathology practice after increase of hematopathology case and frozen section. Intraoperative cytology (IC) is performed by taking imprint smears from the cancerous tissue and establishing an early diagnosis at the operation site.² Ovarian cancer is eight most common cancer among women, and it includes about 4% of all women's cancer.³ Lifetime risk of ovarian cancer in women is one in 71, and the chance of dying from the disease is 1 in 95.⁴ Malignant epithelial tumors of ovary are usually aggressive and they

need extensive surgery that at times requires bilateral salpingo-oophorectomy and total abdominal hysterectomy; mostly followed by chemotherapy. Patients with benign epithelial tumors may present with features mimicking malignancy like large abdominal-pelvic mass in case of mucinous cystadenoma, however if correctly diagnosed on IC, requires cystectomy only.⁵ Intraoperative cytology diagnosis helps to manage patient during the operative procedure and process further in the benefit of the patient management. Preliminary diagnosis helps to provide the specific therapy in time, reducing morbidity and mortality. Histopathology is the gold standard and definitive pathology diagnosis, whereas touch imprints are used for detecting preliminary diagnosis for malignant and benign condition. Touch imprint cytology has got definite role in Intra operative diagnosis that would guide the Surgeon's hand.⁶ Imprint is a touch preparation in which tissue is touched on the slide and leaves behind its imprint in the form of cells on the glass slide.⁷ The literature suggests that intraoperative touch imprint cytology can be useful in evaluation of margin.⁸ Thus, in an intraoperative consultation, the application of both imprint cytology and histological diagnosis of frozen sections has been recommended for ovarian tumors.⁹⁻¹¹ We underwent this study to evaluate the accuracy of imprint cytology/ touch preparation in the diagnosis of ovarian neoplasms and correlate it with histopathological diagnosis.

MATERIALS AND METHODS

We conducted a prospective study of total 103 resected ovarian neoplasm in our Pathology department of Paropakar Maternity and Women's Hospital over a period of 10 months (2018 June 1st-2019 to March 31). The entire sample operated in Gynecology surgery with solid and cystic ovarian mass was included. Insufficient cellularity in touch imprint and emergency operation for ovarian mass were excluded from the study. The lesions were cut when fresh and tissue was obtained from representative area from solid and cystic component. Samples for cytology were obtained from several parts of tumors presenting different gross morphology. Tissue was firmly touched or representative samples were cut and firmly pressed on the clean dry leveled frosted glass slides and wet smear were immediately fixed in 95% ethanol or 80% isopropyl alcohol. Air dried smear were stained with rapid Giemsa stain. Wet smear were processed for rapid Papanicolaou method. The slides were immediately dipped in hematoxylin for 1 min, rinsed rapidly with distilled water, differentiated with ammonium hydroxide, counterstained with eosin by three slow dips, washed in tap water, dried, mounted on glass slides and covered with a coverslip. The time consumed for taking imprints, staining and reporting was 20 minutes.¹² The smears were evaluated for cellularity, arrangement of epithelial cells, cellular features of malignancy, necrosis and background. All benign and borderline lesions were reported as negative for malignancy. And malignant lesions were reported as positive for malignancy. Histopathology

diagnosis was considered as the gold standard for statistical evaluation. All surgical resection specimens were fixed in 10% formalin were routinely processed. Histopathology diagnosis of paraffin embedded tissue sections was made by H.E staining and compared with the results of Imprint Cytology. The histopathology diagnosis of ovarian tumor was made according to WHO classification.¹³ The results were statistically evaluated for sensitivity, specificity, positive predictive value and overall accuracy of diagnosis. The statistical analysis of data was performed by Microsoft Excel 2013.

RESULTS

All together the study included 103 patients with ovarian mass diagnosed by clinical examination, ultrasonography and CT scan examination. Imprint cytology smears were performed in all patients. Out of which two were excluded from the study due to insufficient material. The age ranged from 12 years to 68 years with mean age of 34 year. The malignant ovarian tumor was among patient with age of 12 year to 57 years with mean age of 35.7 years (Table. 1).

Out of 101 cases 89% (n=90) cases shows benign and 11% (n=10) cases show malignant in touch imprint cytology. Whereas in histopathology 90 cases shows benign and 11 cases show malignant ovarian neoplasm (fig. 1). The frequency of malignant tumors diagnosed on histology are shown in figure 2.

The most common malignant tumor is serous cystadenocarcinoma comprise 41% among all malignant tumor. The second common malignant tumor is mucinous carcinoma 25% among all malignant tumors followed by 8.3% of Clear cell carcinoma, Immature Teratoma, Yolk sac tumor and Metastasis tumor each. For borderline group, the diagnostic accuracy of imprint cytology was low as three cases of borderline given as benign in imprint cytology. One

Histology Findings of Ovarian Neoplasm

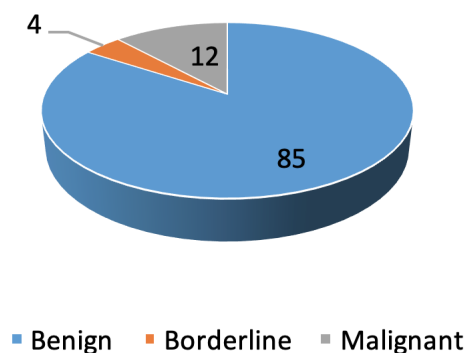


Figure 1: Pie chart showing histology findings of ovarian neoplasm

Table 1: Age-wise distribution of ovarian tumors

Age group	Total no. of cases	No. of malignant cases
11 to 20	15	3
21 to 30	23	1
31 to 40	37	2
41 to 50	19	2
51 to 60	6	3
61 and above	1	-
Total	101	11

Table 2: Correlation between Imprint and Histology

		Histopathology	
		Benign	Malignant
Touch imprint	Negative for malignant cells	89	1
	Positive for malignant cells	0	11

Frequency of malignant tumors on histopathology

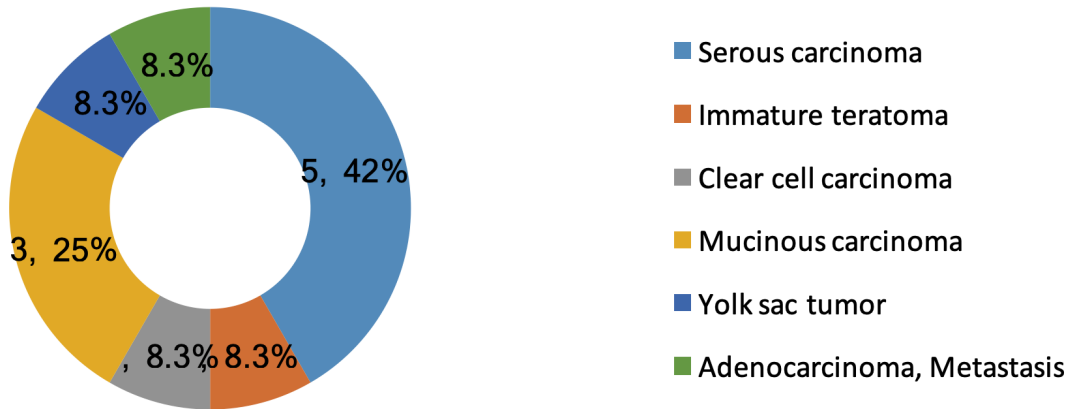


Figure 2: Frequency of malignant tumors on histopathology

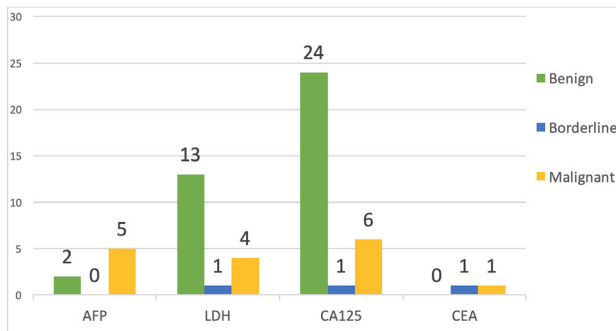


Figure 3: Ovarian neoplasm showing high tumor markers

benign imprint cytology report turns out to be malignant in histopathology diagnosis, thus giving one false negative case in our study. Correlation between imprint cytology with that of histopathology diagnosis was shown in Table 2. We found a satisfactory diagnostic accuracy of the

intraoperative imprint cytology (99%) in our study. The imprint cytology does not match with 1% cases with the histological diagnosis.

Based on above findings sensitivity of imprint cytology in our study was 91.67% and specificity was 100.0%. Positive predictive value was 100.0% and Negative predictive value was 98.89%.

Positivity of tumor markers was seen in benign, borderline, and malignant ovarian neoplasm are shown in figure 3. Among the malignant ovarian tumors, tumor markers were not performed in one case of serous carcinoma. CA125 was increased in four cases of serous carcinoma and in two cases LDH was increased. One case each of mucinous carcinoma showed increased levels of CA125, LDH, CEA and AFP. AFP was also raised in one case of clear cell carcinoma and one of immature teratoma, however, the level of AFP was markedly elevated (more than 1000) in the case of Yolk sac tumor only. The case of immature teratoma also showed increase in LDH.

DISCUSSION

Intraoperative imprint cytology is one of the important diagnostic tools for any suspicious of doubtful ovarian neoplasm, which can help surgeon how to proceed for further surgery. In the places where there is limitation to access other means of diagnosis tools it plays a very important role. Michael C et al. and Khalid A et al. also mentioned in their articles that imprint cytology is probably the only means of rapid intraoperative consultation where access to intraoperative histological diagnosis is limited.^{14,15} This study is to describe intraoperative accuracy of imprint cytology with that of histology diagnosis in case of Ovarian Neoplasm. As there are only a few reports describing its accuracy and validity of intraoperative cytology.¹⁶⁻¹⁸

The present study shows touch/ imprint cytology consists Negative for malignancy 89.1% and Positive for malignancy 10.9%. Whereas, Melies M et al. in their study showed 81.8% patients were negative and 18.2% patients were positive while in border line all cases were positive and in malignant group 11.9% patients were negative and 88.1% patients were positive.¹⁶

Nagai et al. examined the imprint cytology and reported that the accuracy of intraoperative imprint cytology was 87.1% for benign, 30% for borderline, and 83.6% for malignant tumors.¹⁹ Jain R et al. in the study about role of intraoperative cytology showed diagnostic accuracy of 95.60%.²⁰ Sushma and Panicker in their study showed 96.4% diagnostic accuracy in surface epithelial lesions, almost 100% accuracy in identifying germ cell tumors and 98.5% accuracy in categorizing sex cord stromal tumors.²¹ Melies et al. in 2018 intraoperative imprint cytology study found sensitivity was 84.85% and specificity 100%.¹⁶ In the study of imprint cytology of ovarian neoplasms done by Tushar, et al. the sensitivity and specificity were 93% and 92% respectively.²² Nadji, et al. had a sensitivity and specificity of 96.4% and 92% respectively in their study on cytology of ovarian neoplasms.²³ In our study, overall diagnostic accuracy of touch imprint was 99% with sensitivity 100% and specificity was 91.67 percent.

Among epithelial malignant tumor serous cystadenocarcinoma are the most common malignant tumor in our study which imprint cytology and histology diagnosis was correlated showing 100% diagnostic accuracy. Jain R et al. and Shahid M in their studies showed 100% accuracy in serous adenocarcinoma.^{20,24} But Melies M et al. study showed 76% diagnostic accuracy in serous adenocarcinoma.¹⁶ In our study, serous borderline cases were reported as negative for malignancy in Shahid M²⁴ in their study also reported it as benign serous tumor for borderline serous tumor.

Mucinous cystadenocarcinoma was second most common malignant tumor in our study which imprint cytology and histology diagnosis was correlating showing 100% accuracy. Melies M et al. in their study also show 100% accuracy in diagnosis of mucinous cystadenocarcinoma.¹⁶

Mature cystic teratoma, Immature teratoma and Yolk sac tumor are the germ cell tumors that we came across in our

study. Diagnostic accuracy is 100% in our study and our findings are supported by the study done by Shahid et al.²⁴, Khunamornpong and Siriaunkgul²⁶ and Jain R et al.²⁰ which also showed 100% diagnostic accuracy of cytological examination in detecting germ cell tumors.

Clear cell carcinoma was another epithelial malignant tumor that we came across in our study. Most of the comparing cytology studies with histopathology showed 100% accuracy like in study done by Azami S et al.²⁵ also showed 100% accuracy in their study.

Metastasis adenocarcinoma was one of the false negative cases in imprint cytology in our study, whereas in the study of Azami S, Aoki Y, Iino M, et al.²⁵ and Sardar K et al.²⁷ showed true positive in their study for the metastasis malignant tumor.

The touch/ imprint cytology is a good compliment to histopathology. Facility where advanced rapid intraoperative technology is not available, IOC plays very important roles in rapid preliminary diagnosis.

CONCLUSIONS

Imprint cytology plays a significant role in the quick diagnosis of the lesion. It is less expensive, simple, fast and reliable method for diagnosis of malignant ovarian neoplasms. And it is better option where there is no available facility of technology like frozen sections. It can act as a good complement to histopathology and can be of benefit for rapid preliminary diagnosis and surgical management planning.

Conflict of interest: None

REFERENCES

1. Misra SP DM, Misra V, Gupta SC. Imprint cytology - A cheap, rapid Monaco SE, Pantanowitz L. Introduction. In: Pantanowitz L, Xing J, Monaco SE. Atlas of Touch Preparation Cytopathology: Springer Publishing Company; 2018. p.1-8
2. Jaafar H. Intra-operative frozen section consultation: Concepts, applications and limitations. Malays J Med Sci 2006;13:4-12. Website
3. Sankaranaryan R, Ferlay J. Worldwide burden of gynecological cancer: the size of the problem. Best Pract Res Clin Obstet Gynaecol 2006;20:207-25. Crossref
4. Ahlgren JD. Epidemiology and risk factors in pancreatic cancer. Semin Oncol 1996;23: 241-250 Website
5. Riaz A, Khalid A, Tanwani AK. Diagnostic Accuracy of Touch Imprint Cytology in Ovarian Neoplasms. Int. j. pathol 2015;13:66-71. Website
6. Koss LG, Melamed MR (eds). Diagnostic Cytology: Its Origins and Principles. In: Koss' diagnostic Cytology and Its Histopathologic Bases. 5th edn. Lippincott Williams and Wilkins; 2006.p.5-20
7. Melies M, Agamia A, Abdallah DM, Rady HA, Selim A. Evaluation of Intraoperative Imprint Cytology in Ovarian Tumors. J Cytol Histol 2018;9:523. Crossref
8. Valdes EK1, Boolbol SK, Cohen JM, Feldman SM. Intraoperative touch preparation cytology; does it have a role in re-excision lumpectomy? Ann Surg Oncol. 2007;14:1045-50. Crossref

9. Silverberg S. Female genital tract. In Intraoperative consultation. A guide to smears, imprints, & frozen sections. Nochomovitz L, SidawyM, Silverberg S, Jannotta F, Schwartz A, eds. Chicago: ASCP Press; 1989:24–41.
10. Souka S, Kamel M, Rocca M, et al. The combined use of cytological imprint and frozen section in the intraoperative diagnosis of ovarian tumors. *Int J Gynecol Obstet.* 1990; 31:43–6. [Crossref](#)
11. Santin CA, Sica A, Melesi S, et al. Contribution of intraoperative cytology to the diagnosis of ovarian lesions. *Acta Cytologica.* 2011;55:85–91. [Crossref](#)
12. Rahman K, Siddiqui FA, Zaheer S, Sherwani MKA, Shahid M, et al. Intraoperative cytology-role in bone lesion. *Diagn Cytopathol* 2010;38:639-44. [Crossref](#)
13. Kurman RJ, Carcangiu ML, Harrington CS, Young RH, eds. Tumors of ovary. In: WHO Classification of Tumors of the Female Reproductive Organs. Geneva, Switzerland: WHO Press; 2014. 4th edn. p. 8-86.
14. Michael C, Lawrence W, Bedrossian C. Intraoperative consultation in ovarian lesions: a comparison between cytology and frozen section. *Diagn Cytopathol.* 1996;15:387-94. [Crossref](#)
15. Khalid A, Haque AU Touch impression cytology versus frozen section as intraoperative consultation diagnosis. *Int J Pathology.* 2004;2:63-70. [Website](#)
16. Melies M, Agamia A, Abdallah DM, Rady HA, Selim A. Evaluation of Intraoperative Imprint Cytology in Ovarian Tumors. *J Cytol Histol* 2018;9:523. [Website](#)
17. Suen KC, Wood WS, Syed AA, Quenville NF, Clement PB. Role of imprint cytology in intraoperative diagnosis, value and limitations. *J Clin Path* 1978;31:328-337. [Crossref](#)
18. Lee TK. The value of imprint cytology in tumor diagnosis: A retrospective study of 527 cases in China. *Acta Cytol* 1982;26:169-171. [Website](#)
19. Nagai Y, Tanaka N, Horiuchi F, et al. Diagnostic accuracy of intraoperative imprint cytology in ovarian epithelial tumors. *Int J Gynecol Obstet.* 2001;72:159–64. [Crossref](#)
20. Jain R, Jain V, Dutta S, Awasthi S, Jain SK. Role of Intra-operative Cytology in the Diagnosis of Ovarian Neoplasm's. *Int J Sci Stud* 2015;3:72-75. [Crossref](#)
21. Sushma, Panicker S. Imprint cytology in the diagnosis of ovarian lesions. *Int J Res Med Sci.* 2015;3:3770-4. [Crossref](#)
22. Tushar K, Asaranti K, Mohapatra PC. Intraoperative cytology of ovarian tumors. *J Obstet Gynecol India* 2005;55:345-349. [Website](#)
23. Nadji M, Greening SE, Sevin BU. Fine needle aspiration cytology in gynaecologic oncology. ii. morphologic aspects. *Acta Cytol* 1979;23:380-88. [Website](#)
24. Shahid M, Aysha SZ, Rahman MK, Sherwani RK. The Role of Intraoperative Cytology in the Diagnostic Evaluation of Ovarian Neoplasms. *Acta Cytologica* 2012;56:467–73. [Crossref](#)
25. Azami S, Aoki Y, Iino M, et al. Useful aspects of diagnosis of imprint cytology in intraoperative consultation of ovarian tumors: comparison between imprint cytology and frozen sections. *Diagn Cytopathol* 2018;46:28-34. [Crossref](#)
26. Khunamornpong S, Siriaunkgul S. Scrape cytology of the ovaries: Potential role in intraoperative consultation of ovarian lesions. *Diagn Cytopathol* 2003;28:250-7. [Crossref](#)
27. Sardar K, Singh J, Tirkey S. Evaluation of Intraoperative Cytology in Ovarian Tumours. *IOSR Journal of Dental and Medical Sciences.* 2017;16:93-102. [Website](#)