



Case Report

Colloid cyst of the third ventricle: Histopathological and ultrastructural study

Prasanna Karki¹, Sameer Chhetri Aryal², Gopi Aryal², Rajesh Panth², Manoj Bohara¹,
Sumit Joshi¹, Prakash Paudel¹, Damber Bikram Shah¹, Gopal Raman Sharma¹

¹Department of Neurosciences, Neurosurgery division, Nepal Medciti Hospital, Kathmandu, Nepal

²Department of Laboratory Medicine & Pathology, Nepal Medciti Hospital, Lalitpur, Nepal

Keywords:

Colloid cyst;
Hydrocephalus;
Third ventricle;

ABSTRACT

Cysts occupying the third ventricle are rare lesions and may appear as an unusual cause of hydrocephalic crisis. A 40-year old woman with headache and one episode of fainting attack was diagnosed with a cystic lesion in the third ventricle after brain MRI study. She was operated with the pre-operative diagnosis of a colloid cyst. A yellowish, thick and mucoid cyst was observed intra-operatively. The total removal of the cyst was done along with the cyst wall.

On histopathological evaluation, the cyst wall was lined by ciliated cuboidal to pseudostratified columnar epithelium resting on an eosinophilic basement membrane. The ultrastructural study showed the characteristic 9+2 pattern of cilia. Immunohistochemistry showed positive staining for epithelial membrane antigen (EMA), cytokeratin (CK), and negative staining for Glial fibrillary acidic protein (GFAP). Histopathological and ultrastructural findings confirm the diagnosis of a colloid cyst of third ventricles favoring the endodermal origin of the cyst.

Correspondence:

Dr. Gopi Aryal, MD, PhD

Chair, Department of Laboratory Medicine & Pathology

Nepal Medciti Hospital Pvt. Ltd, Lalitpur, Nepal

ORCID ID: 000-002-8566-2593

Email: gopiaryal1@gmail.com



Received : June 14th 2019 ; Accepted : August 24th 2019

Citation: Karki P, Aryal SC, Aryal G, Panta R, Bohara M, Joshi S, Paudel P, Shah DB, Sharma GR. Colloid cyst of the third ventricle: Histopathological and ultrastructural study. J Pathol Nep 2019;9:1590-4. DOI 10.3126/jpn.v9i2.24882

Copyright: This is an open-access article distributed under the terms of the Creative Commons Attribution 4.0 International License, which permits unrestricted use, distribution, and reproduction in any medium, provided the original author and source are credited.

INTRODUCTION

The ventricular Colloid cyst (CC) is slow growing, benign developmental lesions that occur at the roof of the third cerebral ventricle close to the foramen of Monro. They account for 0.5%–2% of all intracranial 1-3 and 15%–20% of all intraventricular tumors¹ The cysts are surgically challenging to manage as these are deeply located, and have an excellent prognosis when diagnosed early and totally excised.⁴ The multiple terms used to describe these cysts like colloid, endodermal, epithelial, paraphyseal, and neuroepithelial cyst.^{1,2}

As the cysts grow they obstruct the foramen of Monro producing hydrocephalus of the lateral ventricles leading to intermittent headache and features of raised Intracranial pressure. This can be acute and catastrophic because of the pedunculated nature of the tumor resulting in brain herniation and death.⁴ They are usually diagnosed by computed tomography (CT) or magnetic resonance imaging (MRI). These developmental cysts arise from the

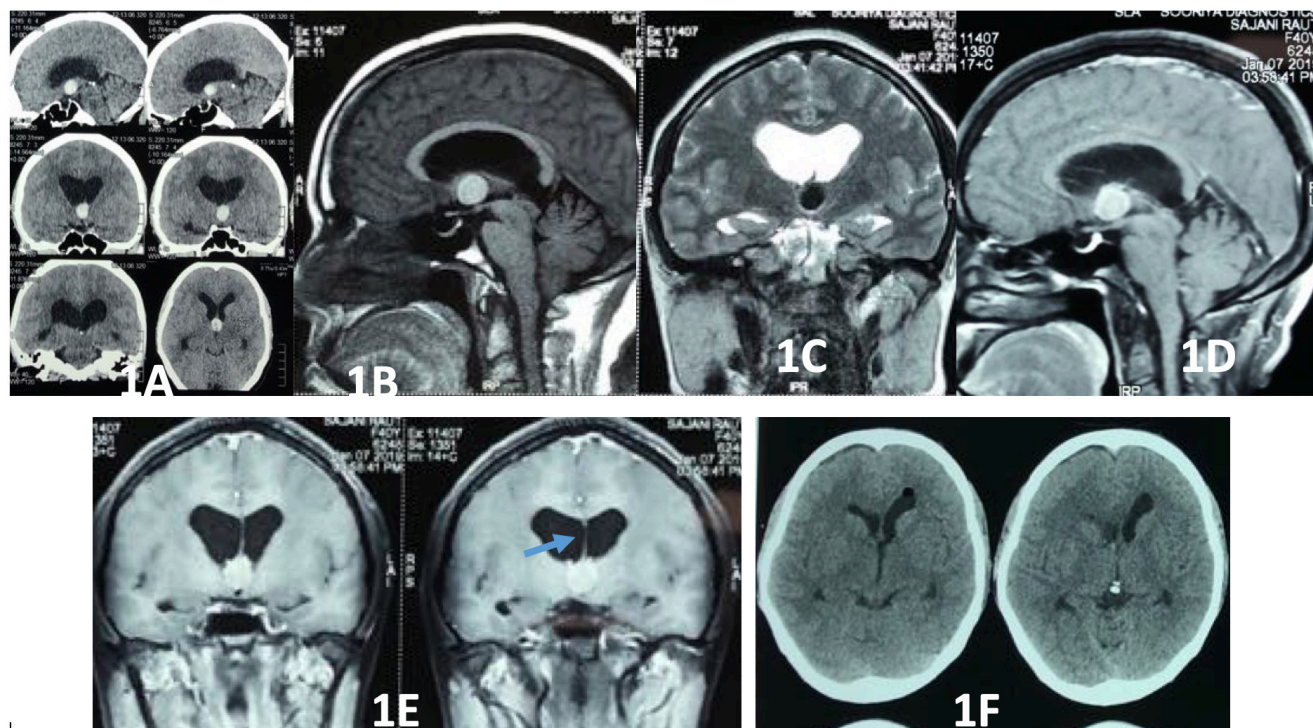


Figure 1: A: Coronal and axial CT head showing hyperdense third ventricular lesion. B: Sagittal MRI T1 weighted image showing hyperintense lesion in 3rd ventricle just over chiasma. C: Coronal MRI T2 weighted image showing hypointense lesion. D: Sagittal MRI T1 weighted image with contrast demonstrated no uptake of contrast material by the cystic lesion. E: Coronal MRI Fluid-attenuated inversion recovery (FLAIR) showed slightly hyperintense cyst with deviation of septum pellucidum towards left. F: Post operative CT head non contrast showed complete excision of the cystic lesion .

neuroepithelium of the diencephalic roof. In third ventricle, the cysts are generally classified as "colloid cyst" and differ from most neuroepithelial cysts occurring in other locations, in that the cyst contents are usually viscid, with gelatinous or mucinous appearance.⁵

We report a case of third ventricular colloid cyst in a 40-year old female and discuss the histopathological and ultrastructural findings.

CASE REPORT

A 40-year old female presented with a history of intermittent headache aggravated by coughing, sneezing and laughing. She had one episode of loss of consciousness one month earlier.

Her general and systemic examination was unremarkable. Fundoscopic examination of the eye was normal. Neurological examinations were normal. Complete blood count including coagulation profile was within normal limit.

CT (non-contrast) images showed a well-defined 15×13 mm size, hyper-attenuating cystic lesion in the region of foramen of Monro leading to mild dilatation of bilateral lateral ventricles (Rt-18mm - Lt-13mm) (fig.1A). On MRI brain well-defined oval lesion in the anterior third ventricle in the region of foramen of Monro measuring about 1.4x 1.1x 1.8 cm in axial and cranio-caudal dimensions. MRI

images confirmed the cystic nature of the lesion, sagittal T1 hyperintense (fig.1B) and on coronal T2 extremely hypointense (fig.1C). MRI sagittal post contrast images showed the cranio-caudal extension of the lesion and cyst was not enhanced (fig.1D). Inferiorly lesion was just above the optic chiasma and tectum of the midbrain. Coronal FLAIR images showed a slightly hyperintense cyst with mild hydrocephalus and a thin rim of periventricular seepage. The septum pellucidum is seen bowed towards left (fig.1E). Based on the imaging findings a diagnosis of the colloid cyst was suspected. The patient underwent the right fronto-parietal parasagittal large craniotomy midline interhemispheric transcalsal-transforaminal approach and complete excision of the cyst along with the cyst wall. Complete excision of the cyst is evident in post-operative CT scanning (fig. 1F).

The patient underwent surgical intervention and a biopsy specimen was sent to the laboratory. Grossly, the mucoid cyst contained thick gelatinous mucoid material (arrow-head) with a thin and well defined cyst wall (arrow) (fig.2A). Microscopically the cyst was lined by pseudostratified ciliated columnar epithelium resting on homogenous eosinophilic material with foci of dystrophic calcification (fig.2B). The cyst wall showed mild chronic inflammatory cell infiltration in the underlying fibrovascular tissue. Immunohistochemistry for EMA and CK (fig. 2C & D) were positive and GFAP (fig. 2E) was negative.

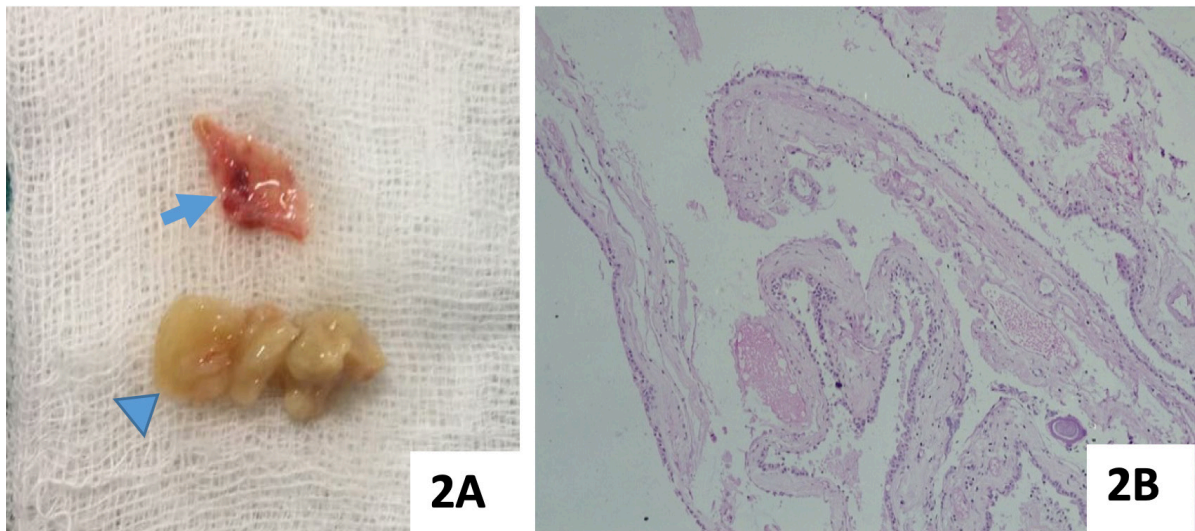


Figure 2A: Gross finding of the cystic lesion showed thin greyish wall of the cyst (arrow) and thick gelatinous mucoid inner content (arrowhead) **Figure 2B:** Cyst wall lined by pseudostratified ciliated columnar epithelium resting on eosinophilic basement membrane (HE stain, x100).

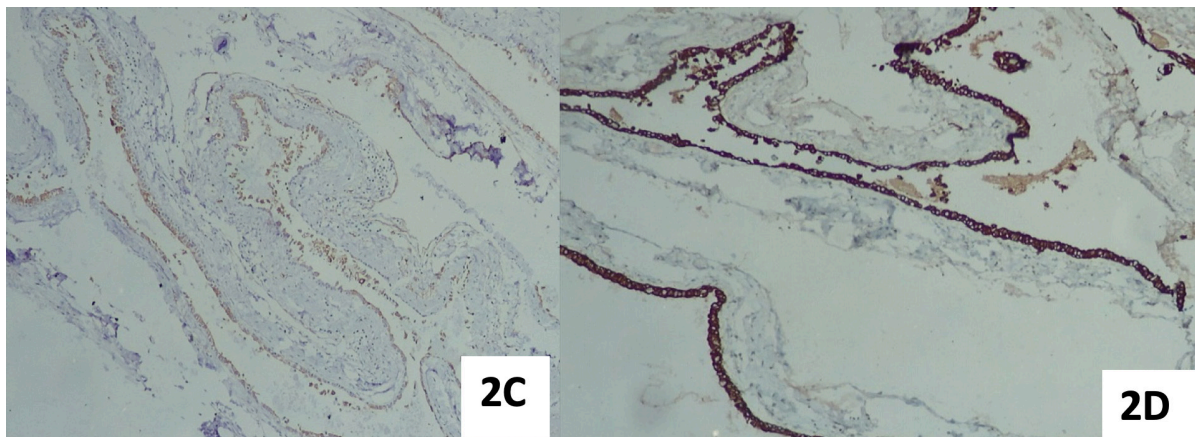


Figure 2C: Positive Immunostaining for EMA (IHC; x 100). **Figure 2D:** Positive Immunostaining for CK (IHC; x 100).

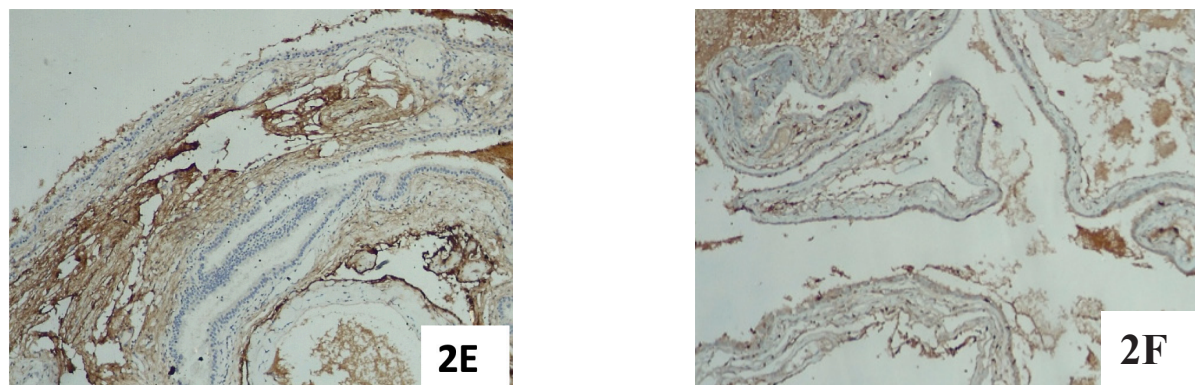


Figure 2E: Epithelial membrane antigen (EMA) immunohistochemical staining was positive

Figure 2F: Negative staining for GFAP (IHC; x 100)

Ultrastructural Finding

The electron microscopic examination of cyst wall showed characteristic 9+2 pattern (Fig. 3A (x2000) & B (X8000)). The 9+2 pattern consists of 11 longitudinal fibrils, 2 central

and 9 peripheral fibrils as seen in figure 3B (arrow). The findings confirmed the diagnosis of endodermal origin of cyst. On follow up after 6 months of surgery, the patient is doing well without any symptoms.

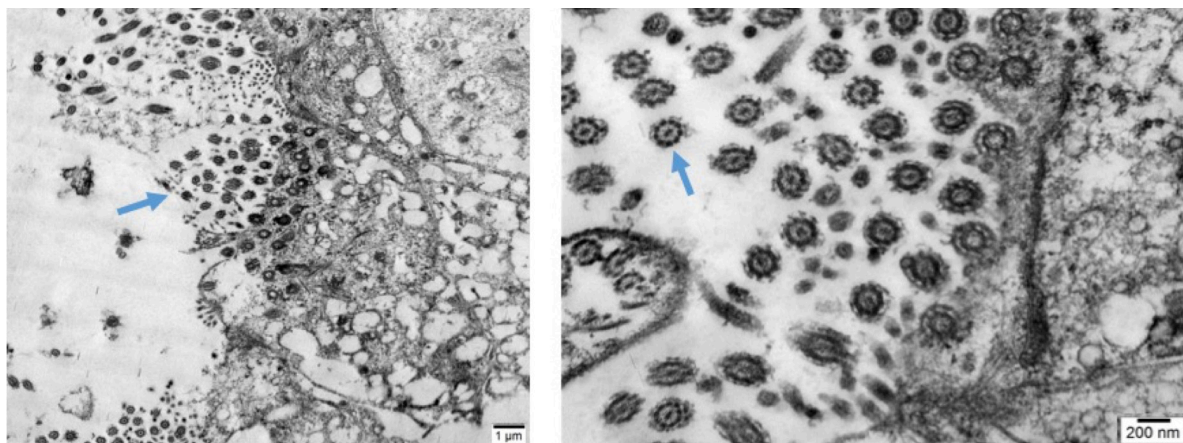


Figure 3A: Electron Microscopy (EM) showed detailed structure of the ciliary pattern (X2000), **B:** Electron Microscopy (EM) showed 9+2 ciliary pattern with nine peripheral microtubular doublets and two central microtubules (arrow) (X8000)

DISCUSSION

Colloid cysts usually occur in the anterior and anterosuperior part of the third ventricle.⁵⁻⁷ Thus even relatively small lesions may block the Foramen of Monro producing hydrocephalus. Intermittent headache associated with sneezing, coughing and laughing may be due to the ball-valve effect, as a result of translocation of the lesion or compression of an already compromised foramen of Monro.⁸ In this case, the cyst caused a hydrocephalic crisis. The operation was recommended due to the possibility of cyst growth in the future, which could cause unexpected deterioration of consciousness. The transient worsening of symptoms was a consequence of intermittent CSF blockage.

Owing to their strategic location of cyst adjacent to the foramina of Monro, the cyst is relatively small at the time of diagnosis, usually not more than 2 cm in diameter. The radiological finding of the cyst depends upon the protein and cholesterol content of the cyst fluid. MRI T1 signal intensity is isointense to slightly hyperintense compared with CSF and typically very hypointense on T2WI because of protein content.^{5,7} In the present case, the cyst was filled with mucoid, dense material which leads to hyperdensity on CT scan. Another cause of hyperdensity seems to be due to high electron density, but trace amounts of higher atomic number elements that could possibly contribute to the CT density of colloid cysts.⁸

On histopathological evaluation, the cyst is usually lined by simple to pseudostratified columnar or cuboidal epithelium. Colloid cysts are usually filled with various gelatinous materials such as blood products, mucin, or cholesterol crystals.⁵ In 1992, using immunohistochemical techniques, Tsuchida et al found a non-neuroepithelial origin of colloid cyst similar to respiratory mucosa of the trachea and sphenoid sinus.⁹ Ho and Garcia on ultrastructural analysis of colloid cysts found: ciliated cells and non-ciliated cells with microvilli, goblet cells with secretory granules,

and basal cells and undifferentiated cells with scanty organelles.¹⁰ Specialized intercellular junctional complexes, or desmosomes were noted in many cell types. Desmosomes are a characteristic feature of epithelial cells and promote cell cohesion. The ultrastructural analysis of colloid cysts and their topographic arrangement were reminiscent of respiratory epithelium, and thus, an endodermal lineage.

In this case, the 9 +2 cilia in this colloid cysts has nine peripheral microtubular doublets and two central microtubules, characteristic of motile cilia, unlike non-motile cilia which have 9+0 pattern. Typical 9+2 ciliary pattern occurs in many normal and neoplastic tissues including bronchial and uterine epithelium, ependymoma, choroid plexus papillomas, Rathke cleft cyst, cerebral endodermal cyst, and cerebral epithelial cysts. The typical axoneme of motile cilia consists of nine peripherals and two central microtubules.^{11,12} The 9+2 arrangement signifies endodermal lineage instead of being neuronal lineage. Endodermal origin, in this case, is also favored by positive immunohistochemistry for CEA, CK, EMA and negative for S-100.

CONCLUSIONS

The management of the colloid cyst needs a multidisciplinary approach involving neurosurgeon, pathologist, and radiologist. The detailed histopathological and ultrastructural findings suggest that the type of cells and their topographic arrangement are reminiscent of respiratory epithelium, and thus, an endodermal lineage.

Conflict of Interest: None

REFERENCES

1. Sharifi G, Bakhtevvari MH, Samadian M, et al., Endoscopic surgery in nonhydrocephalous third ventricular colloid cysts: a feasibility study. *World Neurosurg.* 2015; 84;2:398-404. [Crossref](#)

2. Paniraj GL, Panigrahi M, Reddy AK, et al. Suprasellar colloid cyst: an unusual location. *World Neurosurg* 2014; 81;1:202.e15-8. [Crossref](#)
3. Fraisse T, Sirvain S. Colloid cyst of third ventricle. *Eur Geriatr Med* 2010; 1;5:308-9. [Crossref](#)
4. Rao BH, Satyavaraprasad K, Rajiv PK, Phaneeswar T. Giant Colloid Cyst of Third Ventricle: A Rare Case Report. *Int J Sci Stud* 2015; 3;6:247-50. [Crossref](#)
5. Diane Armao, Mauricio Castillo, Hong Chen and Lester Kwock. Colloid Cyst of the Third Ventricle: Imaging-pathologic Correlation. *Am J Neuroradiol.* 2000; 21;8:1470-7. [Crossref](#)
6. Jeffree RL, Besser M. Colloid cyst of the third ventricle: a clinical review of 39 cases. *J Clin Neurosci.* 2001;8:328-31. [Crossref](#)
7. Christov C, Chretien F, Brugieres P. Giant supratentorial enterogenous cyst: report of a case, literature review, and discussion of pathogenesis. *Neurosurgery.* 2004; 54:759-63. [Crossref](#)
8. Beaumont T.L, Limbrick Jr. D.D., Rich K.M, Wippold II F.J. and Dacey Jr. R.G. Natural history of colloid cysts of the third ventricle. *J Neurosurg.* 2016;125;6:1420-30. [Crossref](#)
9. Tsuchida T, Hruban R.H., Carson B.S, Phillios P.C. Colloid cysts of the third ventricle: Immunohistochemical evidence for nonneuroepithelial differentiation. *Hum Pathol.* 1992;23;7: 811-6. [Crossref](#)
10. Ho K.L., Garcia J.H. Colloid cysts of the third ventricle: ultrastructural features are compatible with endodermal derivation. *Acta Neuropathol.* 1992; 83;6:605-12. [Crossref](#)
11. Karki P, Bohara M, Yonezawa H, Tokimura H, Hirano H, Hanaya R, Arita K. Cerebellopontine angle endodermal cyst presenting with hemifacial spasm. *Brain Tumor Pathol.* 2011; 28;4:371-4. [Crossref](#)
12. Roldán V. E, Hernández M. P, Elizalde A. I, Osorio P. S. Colloid cyst of the third ventricle: case description and survey of the literature. *Rev Neurol.* 2003;1-15; 36;9:833-6. [Crossref](#)