



Case Report

Lesion with blue bone -a case report

Laila Mohamed Ilias¹, Babitha Alingal Mohammed², Roshini PS¹,
Anupama Ponniah¹, Poornima Vijayan¹

¹Department of Pathology, MES Medical College, Perinthalmanna, Kerala, India

²Department of Pathology, NMC hospital, Abu Dhabi, UAE

Keywords:

Bizarre;
Bone;
Nora's lesion;
Osteosarcoma;
Osteochondromatous;
Parosteal;

ABSTRACT

Bizzare parosteal osteochondromatous proliferation, or Nora's lesion is a unique bone lesion that most often arises in the small bones of hands and feet. It is characterised by proliferation of chondroid, bony and fibrous tissue, and is occasionally misdiagnosed as a malignant process. Our case was a 31 year old lady, who presented with a painless swelling near the 5th metacarpal bone of right hand. X-ray showed well marginated mineralised mass arising from the cortical surface of the metacarpal bone. Histopathological examination revealed bizarre parosteal osteochondromatous proliferation composed of varying amounts of cartilage, bone and spindle cells. Cartilage was hypercellular and chondrocytes were enlarged. Ossification was irregular and had a peculiar blue tinctorial quality.

Correspondence:

Dr. Laila Mohamed Ilias, MD
Associate Professor, MES Medical College,
Perinthalmanna, Kerala, India
Email: ilias.laila@gmail.com
ORCID ID: 0000-0001-7651-3062



Received : September 8th 2017 ; Accepted : November 27th 2017; Published : March 30th 2018

Citation: Ilias LM, Mohammed BA, Vijayan P, Ponniah A, Roshini PS. Lesion with blue bone-a case report. J Pathol Nep. 2018;8:1323-5. doi: 10.3126/jpn.v8i1.19464

Copyright: This is an open-access article distributed under the terms of the Creative Commons Attribution 4.0 International License, which permits unrestricted use, distribution, and reproduction in any medium, provided the original author and source are credited.

INTRODUCTION

Bizzare parosteal osteochondromatous proliferation or Nora's lesion is a unique bone lesion that most often arises in the small bones of hands and feet. It was first reported in literature by Nora and co-workers in 1983.¹ Though a benign lesion characterised by proliferation of chondroid, bony and fibrous tissue, it is occasionally misdiagnosed as a malignant process. This entity is associated with a high local recurrence after surgical excision.

CASE REPORT

Our case was a 31 year old lady, who presented with a painless swelling near the 5th metacarpal bone of right hand. On examination, there was a hard swelling with ill defined edges over the dorsal aspect of fifth right metacarpal bone. X-ray showed well marginated mineralised mass arising from the cortical surface of the metacarpal bone (fig.1)

Per-operatively, it was a well circumscribed lesion arising from the right dorsolateral aspect of distal end of 5th

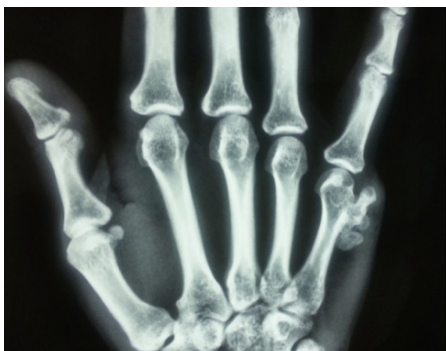

Figure 1: well margined mineralised mass arising from the cortical surface of the 5th metacarpal bone.

metacarpal bone. Lesion was excised and multiple bony tissue bits with attached soft tissue aggregate measuring 2x2x1 cm were received for histopathological examination.

Microscopic evaluation of the tumor revealed bizarre parosteal osteochondromatous proliferation composed of varying amounts of cartilage, bone and spindle cells (fig. 2A&B). Cartilage was hypercellular and chondrocytes were enlarged (fig.3A). Ossification was irregular and had a peculiar blue tinctorial quality (fig.3B). Spindle cells were arranged loosely between the bony trabeculae and at the periphery. Based on these findings a diagnosis of Nora's lesion was made.

DISCUSSION

Bizarre parosteal osteochondromatous proliferation (BPOP) or Nora's lesion is a rare entity of bone most often arising in small bones of hands and feet. These lesions are more common in hands than in feet.¹ Recent studies have shown that it can also arise in the long bones, skull, maxilla and mandible.³ It is mostly seen in adults in their third decade of life and is rare in other age groups. Most patients present with a mass, which is often painless. Radiographs show a well margined mass of heterotopic mineralized tissue arising from cortical surface of affected bone, without periosteal reaction or change to underlying bone.⁴ The mass lacks connection with adjacent medullary cavity, which is commonly seen with osteochondroma, the main differential diagnosis of Nora's lesion.

BPOP can bear radiological resemblance to malignant lesions or osteomyelitis when there is intramedullary inflammatory extension. In such cases, preservation of cortical bone under osteo-cartilaginous mass on T1 weighted magnetic resonance imaging and homogenous intramedullary enhancement with Gadolinium diethylenetriaminepentaacetic acid (Gd-DTPA) can be helpful for distinguishing BPOP from malignant lesions.⁵

Microscopically, bizarre parosteal osteo-chondromatous

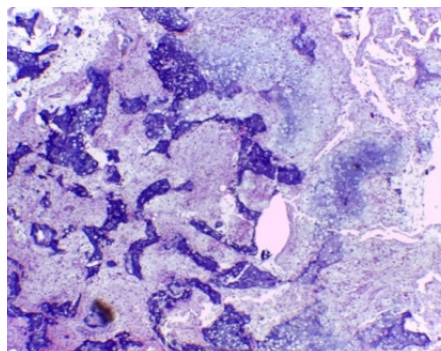


Figure 2A: Variable amount of cartilage, bone and fibrous tissue (HE stain; X20)

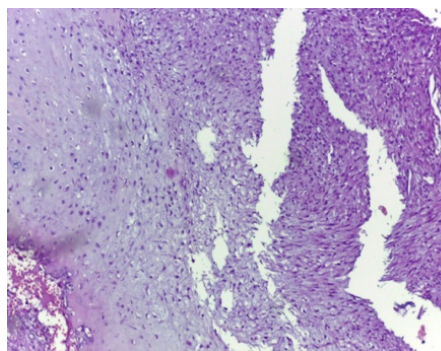


Figure 2B: Spindle cell proliferation (HE stain; X100)

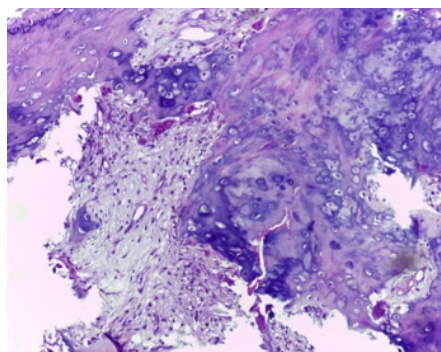


Figure 3A: Hypercellular cartilage with enlarged chondrocytes (HE stain; X100)

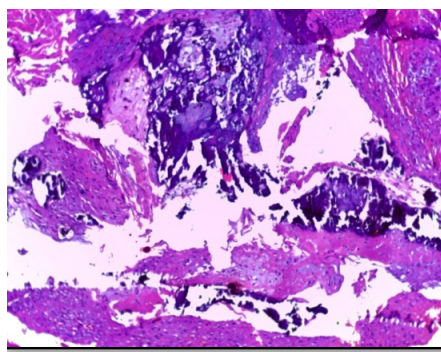


Figure 3B: Irregular ossification with a peculiar blue tinctorial quality (HE stain; X100)

proliferation consists of 3 components in different amounts: cartilage, bone and spindle cells. The cartilaginous component may form a cap or be in lobules separated by dense fibrous tissue. It matures into bone with spindle cells in the background, and is usually hypercellular with enlarged chondrocytes. Ossification is much more irregular than in osteochondroma and has a peculiar blue, tinctorial quality. Spindle cells are arranged loosely between bony trabeculae.

Periosteal chondroma can bear clinical and radiological similarity with Nora's lesion and the distinction between the two is made by histopathologic examination.⁶ The former shows a sharp margin with the underlying thickened cortex and show cytological features of chondroma.

The most important malignant differential diagnosis is parosteal osteosarcoma.⁷ However; it is mostly seen in young adults and involves long bones. X-ray reveals heavily mineralised mass attached to cortex with a broad base. Microscopic examination shows parallelly arranged well-formed bony trabeculae and hypocellular inter-trabecular stroma composed of spindle cells. Hypercellular nodules of cartilage can also be present. BPOP also needs to be clearly distinguished from other benign and malignant differentials for appropriate management.

Surgical excision is the definitive treatment, but it is associated with a high local recurrence.⁸ The current recommendation is to excise the pseudocapsule over the lesion, any periosteal tissue beneath the lesion and to decorticate any abnormal appearing areas in the underlying bone, so that local recurrence can be minimised.

CONCLUSION

Nora's lesion is a benign bone lesion seen in adults, involving small bones and sometimes long bones. It needs to be differentiated from benign and malignant lesions like osteochondroma, periosteal chondroma and parosteal osteosarcoma. Appropriate surgical excision offers curative treatment, minimising local recurrence.

Conflict of Interest: None

REFERENCES

1. K Krishnan Unni and Carry Y. Bone Tumors. 6th Edn. Lippincott Williams & Wilkins;2009. 416pp.
2. Sciort R, Mandahi N. Subungual exostosis and bizarre parosteal osteochondromatous proliferation. In: Eds. Fletcher CDM, Bridge JA, Hogendoorn PCW, Mertens F. WHO Classification of tumours, pathology of genetics, Tumors of soft tissue and bone. Lyon 2013: p259-60.
3. Lynch DW, Jassim S, Donelan K, VanDenmark R Jr, Jassim AD. Usual clinical presentation of bizarre parosteal osteochondromatous proliferation with unusual histology. *SD Med* 2013;66:221-5.
4. Smith NC, Ellis AM, McCarthy S, McNaught P. Bizarre parosteal osteochondromatous proliferation: a review of seven cases. *Aust N Z J Surg* 1996;66:694-7. [Crossref](#)
5. Orui H, Ishikawa A, Tsuchiya T, Ogino T. Magnetic resonance imaging characteristics of bizarre parosteal osteochondromatous proliferation of hand: a case report. *J Hand Surg Am* 2002;27:1104-8. [Crossref](#)
6. Flint JH, McKay PL. Bizarre parosteal osteochondromatous proliferation and periosteal chondroma: a comparative report and review of the literature. *J Hand Surg Am* 2007;32:893-8. [Crossref](#)
7. Oveido A, Simmons T, Benya E, Gonzalez-Crussi F. Bizarre parosteal osteochondromatous proliferation: case report and review of literature. *Pediatr Dev Pathol* 2001;4:496-500. [Crossref](#)
8. Michelsen H, Abramovici L, Steiner G, Posner MA. Bizarre parosteal osteochondromatous proliferation (Nora's lesion) in the hand. *J Hand Surg Am* 2004;29:520-5. [Crossref](#)