



Original Article

# Profiles of histopathological lesions of urinary bladder: A five years study

Shrestha EP<sup>1</sup>, Karmacharya K<sup>1</sup>

<sup>1</sup>Department of Pathology, Army Hospital, Chhauni, Kathmandu, Nepal.

## Keywords:

Bladder;  
Neoplastic;  
Urothelial lesion

## ABSTRACT

**Background:** Neoplastic and non-neoplastic urinary bladder lesions are the main reasons for morbidity and mortality throughout the world. Amongst these, urothelial carcinoma is a common primary tumor of urinary bladder (90%). The objective of this study is to determine the profile of various urothelial lesions received in Army Hospital within 5 years of period.

**Materials and methods:** Five years retrospective study of cystoscopic biopsies and radical cystectomy specimens were carried out in Department of Pathology, Army hospital.

**Results:** Out of 53 cystoscopic biopsies and radical cystectomy specimens, 42 were neoplastic and 11 were non neoplastic lesions. Thirty six urothelial carcinomas were observed out of which 20 were high grade urothelial carcinoma and 16 were low grade. Out of 20 high grade urothelial carcinoma, 17 had muscle invasion and 3 had invasion upto lamina propria. Of 16 low grade urothelial carcinoma, 12 were noninvasive, 2 had invasion upto lamina propria and 2 had muscle invasion. Papilloma was the commonest benign lesions found (7.1%) followed by papillary urothelial neoplasms of low malignant potential (PUNLMP) (2.4%) and hemangioma (2.4%).

**Conclusion:** This article have highlighted upon the importance of histopathological study in evaluating urinary bladder lesions. Also, it has helped in determining that neoplastic lesions were more common than non-neoplastic lesions as seen in our study. A great majority of neoplastic lesions were of urothelial origin. Cystoscopic studies and biopsies help in early detection of bladder neoplasms and they form the mainstay of the diagnosis and follow up.

## INTRODUCTION

Neoplastic and non-neoplastic urinary bladder lesions are collectively responsible for significant morbidity and

mortality throughout the world.<sup>1</sup> Tumors of bladder however continue to be the most common cause of morbidity and mortality.<sup>2</sup> Amongst bladder tumors, urothelial carcinoma, also known as transitional cell carcinoma is a common malignant tumor of urinary bladder and comprises of 90% of primary tumor of bladder.<sup>3</sup> It is the ninth most common cancer in the world, with 430,000 new cases diagnosed in 2014.<sup>4</sup> The remaining 10% comprises of all other types of

## Correspondence:

Dr. Eva Shrestha (Piya), MBBS, MD  
Department of Pathology,  
Army Hospital chhauni, Kathmandu, Nepal  
Email: evapiya@yahoo.com

carcinomas, a small number of sarcomas and miscellaneous tumors.<sup>5</sup> Approximately 98% of malignant tumors arising in the urinary bladder are of epithelial origin and of these, 90% are usual urothelial carcinoma.<sup>6</sup> The highest incidence is sixth and seventh decades of life. It is more common in men than women in the ratio of 3-4:1. Cystoscopy is the primary diagnostic tool for patients who are suspected to have bladder tumors.<sup>7</sup> The objective of this study is to determine the profile of various urothelial lesions received in Army Hospital within 5 years of period.

## MATERIALS AND METHODS

This is a retrospective analysis of biopsies taken from urinary bladder were performed in Army hospital. Prior to study permission was obtained from institutional review committee. A total 53 biopsies were reviewed within 5 years of period. All cystoscopic biopsies and radical cystectomy specimens were included in the study. All cases of urothelial carcinomas were graded histologically according to WHO (2004)/ISUP classification. Statistical analysis was performed using Excel wherever applicable.

## RESULTS

A total of 53 cystoscopic biopsies and radical cystectomy specimens were reviewed in a period of five years from January 2011 to December 2015 in Army Hospital. Out of 53 cases, 42(79 %) were neoplastic and 11(21%) cases were non neoplastic lesions. (Table 1) Of 11 non-neoplastic lesions, 3(28%) cases were ulcerative polypoid cystitis, 3 (27%) were chronic inflammatory lesion, 2(18%) were cystitis glandularis and 3(27%) were granulomatous cystitis (Table 2). Of 42 neoplastic cases, 5(12 %) were benign neoplastic lesions and 37(88 %) were malignant lesions. Among benign lesion, 3(7.1 %) were papillomas, 1(2.4 %) was PUNLMP and 1(2.4 %) was hemangioma. (Table 3)

Amongst 37 malignant lesions which were observed, 36 cases were transitional carcinoma and 1(2.4%) case was diagnosed as Rhabdomyosarcoma, embryonal type. Transitional carcinomas were by far the commonest malignant neoplasms (85.7%) of urinary bladder. Of 36 transitional carcinoma cases, 16(44 %) were low grade urothelial carcinomas and 20(56%) were high grade urothelial carcinomas.

Out of 16 low grade urothelial carcinomas, 12(33%) were noninvasive urothelial carcinoma. Rest 4(11%) cases were invasive urothelial carcinomas, in which 2(50%) had invasion upto lamina propria and 2(50%) had muscular invasion. Similarly, out of all 20(56%) high grade urothelial carcinoma, lamina propria invasion was seen in 3 cases (15%), and muscular invasion was documented in 17 cases (85%). The age and sex distribution of the urothelial neoplasms is shown in Figure 1.

**Table 1: Distribution of neoplastic and inflammatory lesions of urinary bladder**

Distribution	Total number of cases (n = 53)
Non-neoplastic	11 (21%)
Neoplastic	42 (79%)

**Table 2: Spectrum of inflammatory lesions**

Histopathological categorization	Total number of cases (n=11)
Ulcerative polypoid cystitis	3 (28%)
Chronic nonspecific cystitis	3 (27%)
Cystic glandularis	2 (18%)
Granulomatous cystitis	3 (27%)

**Table 3: Spectrum of different urinary bladder tumors**

Histopathological categorization	Total Number of cases (n = 42)
Papilloma	3 (7.1%)
Hemangioma	1 (2.4%)
PUNLMP	1 (2.4%)
Urothelial carcinoma	36 (85.7%)
Rhabdomyosarcoma	1 (2.4%)

Most of the patients who had bladder tumor were in the age group on 61-70 years. Out of 53 cases studied, 45 cases were male and 8 were female. Amongst 42 neoplastic lesions 36 urothelial bladder tumors were seen in male and 6 were seen in females, the male to female ratio being 6:1. (fig. 1)

## DISCUSSION

Cystoscopic biopsy and radical cystectomy specimens of 53 patients were included in this study. In the present study, of 11 non-neoplastic lesions, whose age ranged from 40 to 90 years, 3 cases had ulcerative polypoid cystitis which showed polypoid lesions with ulceration with oedematous lamina propria with variable amount of chronic inflammatory infiltrate.<sup>8</sup> Three cases were diagnosed as chronic nonspecific cystitis which showed the urothelium within normal limits with lamina propria showing oedema and infiltration by chronic inflammatory cells.

In present study, 2 cases were of cystitis glandularis, which showed slitlike and cystic spaces, lined by cuboidal and columnar epithelium and a rim of urothelium, which were present in lamina propria which co-relates well with the study shown by Semins et al.<sup>9</sup> All 3 cases of granulomatous cystitis showed ulcerations with characteristic granuloma of epitheloid cells, histiocytes, giant cells and lymphocytes.

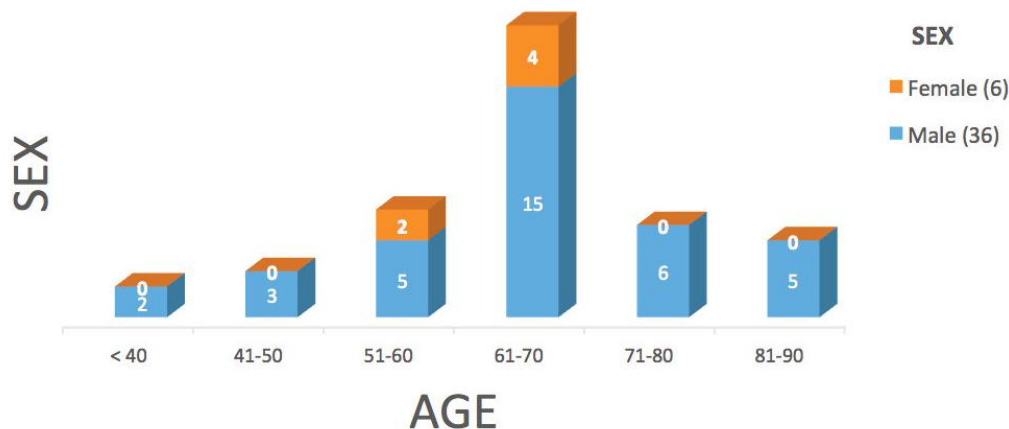


Figure 1: Age and sex distribution of bladder tumors.

This correlated with the findings of Young et al.<sup>10</sup>

As already known, a vast majority of tumors of urinary bladder are of epithelial origin, which arise from the urothelium, transitional type of epithelium that lines the bladder.<sup>1</sup> Approximately 90% of malignant bladder tumors are transitional cell carcinomas. The remaining 10% comprises of all other types of carcinomas.<sup>11</sup> In our study too, urothelial carcinoma was the most common urinary bladder neoplasm comprising 36 cases (85.7%), which correlates well with the study conducted by Kalpana Beniwal et al (93.6%), Mahesh et al (81.81%) and Vaidya et al (80.72%).<sup>12-14</sup>

The commonest age group of tumor presentation was 60-80 years with male to female ratio 6:1 which matches with other studies conducted in other part of Asia. In our study, bladder cancer was the most commonly seen in males as compared to females which is comparable to other studies.<sup>14,15</sup>

In our study, High grade TCC was seen in 20 cases (56%), and 16 cases (44%) were low grade TCC. This correlated well with the study conducted by Vaidya et al, who documented high grade TCC in 35 cases (43.21%) and low grade TCC in 32 cases (39.57%) and study conducted by Mahesh et al, in which high grade TCC comprised of 53.57% compared to low grade TCC which comprised of 42.85%.<sup>13,14</sup> In contrast Lashiram et al, found 53.9% of cases were of Low grade TCC and only 34.6% were of high grade.<sup>15</sup>

Amongst low grade urothelial carcinomas, 12(33%) were limited to mucosa. Out of rest of the 4(11%) cases of invasive low grade urothelial carcinomas, 2(50 %) had lamina propria invasion and muscular invasion was seen in rest 2(50 %) cases. Similarly, amongst 20 cases of High grade TCC, lamina propria invasion was seen in 3(15 %) cases and muscular invasion was documented in 17(85 %) cases. Detrusor muscle invasion was seen in 16% of cases of low grade TCC and 76.92% cases of high grade TCC in

the study done by Vaidya et al which correlated well with our study.<sup>14</sup> 18.2% of low grade tumors and 75% of high grade tumors were invasive to the detrusor muscle layer in the study conducted by Lashiram et al., which again correlated well with our study.<sup>15</sup>

In our study, 5 cases were benign lesion amongst 42 neoplastic lesions. Papilloma was the commonest (7.1%) benign lesion followed by PUNLMP (2.4%) and hemangioma (2.4%) in our study. According to Vaidya et al study papilloma comprised 0.3% and PUNLMP 13.58%, while our study documents higher incidence of papilloma compared to PUNLMP.<sup>14</sup> Incidence of papilloma and PUNLMP documented by Lashiram et al is very much comparable to our study in which 2(7.7%) were papillomas and 1(3.9%) was a papillary urothelial neoplasm of low malignant potential.<sup>15</sup>

## CONCLUSION

Most of the non-neoplastic lesions were of inflammatory origin comprising of ulcerative polypoid cystitis, chronic inflammatory lesions, cystitis glandularis and granulomatous cystitis. A great majority of neoplastic lesions were of urothelial origin while only 1 case was from non-urothelial origin. Amongst urothelial origin neoplastic lesion, transitional cell carcinoma formed the bulk of the cases (87.5%), majority of which showed muscle invasion (45.2%), high grade lesions being the commonest with detrusor muscle invasion. Muscle invasion are the most important determinants of prognosis and treatment for bladder cancer. All urothelial neoplasms were more common in males. Cystoscopic studies and biopsies help in early detection of bladder neoplasms and they form the mainstay of the diagnosis and follow up.

## REFERENCES

1. Srikousthuba et al., Profile of Lesions in Cystoscopic Bladder Biopsies: A Histopathological Study; J Clin Diagn Res. 2013;8:1609–

- 12.
2. Kumar Mahesh U, Yelikar B.R. Spectrum of lesions in cystoscopic bladder biopsies-A histopathological study. *AJMS*. 2012;5:132–6.
3. Rosai and Ackerman's surgical pathology, 9th edition author: Juan Rosai Mosby, Edinburgh, 2004. 2892pp.
4. World Cancer Report 2014. World Health Organization. 2014. pp. Chapter 1.1. ISBN 9283204298.
5. Victor E. Reuter, BLADDER : Risk and Prognostic Factors—a Pathologist's Perspective, *Urologic Clinics of North America* 1999;26:481–92.
6. Mills SE, Carter D, Greenson JK, Oberman HA, Reuter V, Stoler MH, editors. *Sternberg's Diagnostic Surgical Pathology*. 4th edition. Philadelphia, Pa, USA: Lippincott Williams & Wilkins; 2004. 3104pp
7. Grignon DJ. *Urologic Surgical Pathology*. St Louis: Mosby; 1997. Neoplasm of the urinary bladder; pp. 215–305.
8. Silverberg SG, Delellis RA, Frable WJ, LiVolsi VA, Wick MR, eds. *Silverberg's Principles and Practice of Surgical Pathology and Cytopathology*. 4th ed. Philadelphia, Pa: Churchill Livingstone; 2006. 2656pp.
9. Semins MJ and Schoenberg MP: A case of florid cystitis glandularis. *Nat Clin Pract Urol*. 4:341–345. 2007. Crossref
10. Young RH, Eble JN M. Non neoplastic disorders of the urinary bladder, *Urologic Surgical Pathology*. St Louis: Mosby; 1997. pp. 166–212.
11. Reuter VE. Bladder - Risk and prognostic factors – a pathologist's perspective. *Urologic Clinics of North America*. 1993;26:481–91. Crossref
12. Kalpana Beniwal, Sapna Goel, Praveen Ran, Clinicopathological Analysis of Urinary Bladder Tumors at a Tertiary Care Institute in North India, *International Journal of Scientific Study*. 2015;2:96-9.
13. Mahesh Kumar U.\*and B.R.Yelikar. Spectrum of Lesions in Cystoscopic Bladder Biopsies-A Histopathological Study *Al Ameen J Med Sci* 2012;5:132-6.
14. Sujan Vaidya, Mamta Lakhey, Sabira KC, Suspana Hirachand. Urothelial Tumours of the Urinary Bladder: A Histopathological Study of Cystoscopic Biopsies *J Nepal Med Assoc* 2013;52:475-8.
15. Lashiram RS, Kipgen P, Lashiram S, Khuraijam S, Sharma D.C. Urothelial tumors of urinary bladder in Manipur. A histopathological perspective. *Asian Pac J Cancer Indian J Urol*. 2009;25:207-10.