



Case Report

# Primary malignant mucosal melanoma of the larynx: A case report and literature review

Khadka SS<sup>1</sup>, Min Chu Lee<sup>1</sup>, Karki AB<sup>2</sup>

<sup>1</sup>Department of Pathology, BP Koirala Memorial Cancer hospital, Chitwan, Nepal.

<sup>2</sup>Department of Oncosurgery, BP Koirala Memorial Cancer hospital, Chitwan, Nepal.

## Keywords:

Larynx;  
Mucosal melanoma;  
Immunohistochemistry;  
Head and neck.

## ABSTRACT

Malignant mucosal melanoma is very rare entity. It comprises about 1% of all malignant melanoma and exhibit more aggressive behaviour than that of skin melanomas. Mucosal melanoma arises mainly from the mucous membranes of head and neck, the female genital organs or the anorectal and the urinary tracts. Laryngeal malignant melanoma constitutes 3.8% to 7.4% of all cases of malignant mucosal melanoma of head and neck. In this article we report a case of primary malignant mucosal melanoma of larynx in 27 years old male who was treated with radical surgery and adjuvant chemotherapy in BPKM Cancer Hospital, Chitwan.

## INTRODUCTION

Malignant melanoma is a neoplasm that arises from the melanocytes. Melanocytes are derived from the neural crest and are widely distributed throughout all cutaneous and mucosal surfaces. They are found in the basal layer of the epidermis near the dermal-epidermal junction. Although melanoma usually arises from the skin, in rare cases it can affect the eyes, meninges and mucous membranes of the digestive and upperrespiratory tract.<sup>1</sup>

Head and Neck malignant melanoma (HNMM) is a very rare and aggressive neoplasm of melanocytic origin. It was firstly described by Weber in 1859 and recognized as a distinct clinical entity, named "melanotic Sarcoma" in 1869. In the National Cancer Database of USA, only 1-3% out of 84,836 cases of melanoma were proven to be mucosal

origin and 611(0.7%) of these were located in the head and neck region.<sup>2-4</sup>

## CASE REPORT

A 20-years-old Nepali man presented to ENT out Patient Department in Baishakh 2065 with sore throat and hoarseness for one and half years, occasional difficulty in breathing for five months. Direct Laryngoscope examination revealed multiple exophytic, dark color masses involving epiglottis and pyriform fossa of right side. CT scan showed eccentric exophytic soft tissue density mass arising from the laryngeal surface of the right half of the epiglottis (fig. 1). Biopsy was performed and microscopic examination displayed brownish black pigment laden tumor cells in mucosa and submucosa (fig.2 &3). Immunostaining of these tumor cells were positive for S-100 protein and HMB-45 antibodies. No other primary melanoma was detected. Complete clinical examination with fudoscopic examination was unremarkable. He was treated with a total laryngectomy

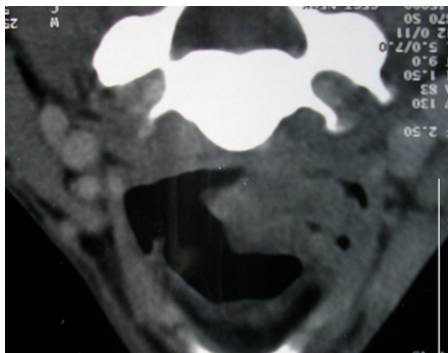
## Correspondence:

Dr. Srijana Shrestha Khadka,

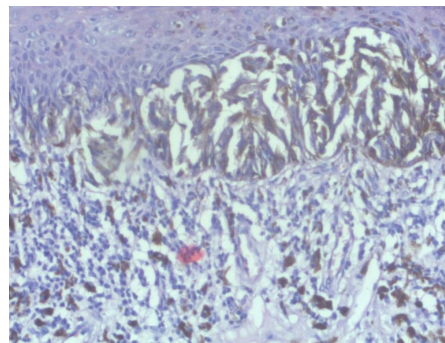
Consultant Pathologist

Grandy City Clinic & Diagnostic Services Pvt. Ltd., Kathmandu, Nepal

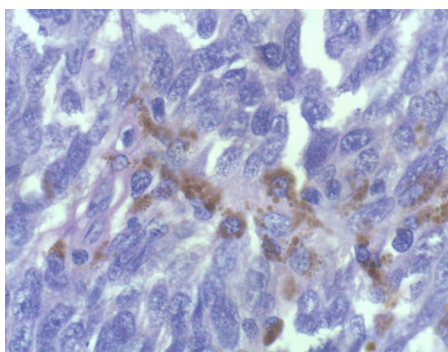
Email: Srijanak82@gmail.com



**Figure 1:** CT scan showing eccentric exophytic soft tissue density mass arising from the laryngeal surface of the right half of the epiglottis



**Figure 2:** In situ or junctional component of tumor (HE stain, X40).



**Figure 3:** Epithelioid tumor cells with melanin laden pigments. (HE stain, X400).

with left radical neck dissection and chemotherapy.

## DISCUSSION

Malignant mucosal melanomas that arise mainly from the head and neck, the female genital organs or the anorectal and urinary tracts have a neuroectodermal origin, which is the reason for their low occurrence in the epithelial lining of endodermal origin. Mucosal melanoma in the head and neck region accounts for half of all mucosal melanoma, occur mainly in the upper respiratory tract, oral cavity and pharynx. Wide range of age (20-80) have been mentioned in reviewed literatures. Very few cases have been reported in age of 4-7 years. They appear with equal gender distribution. But, in series of studies, male predominance was observed. Our case was a male of 27 years old.<sup>2,5</sup> Etiology and pathogenesis of HNMM is poorly understood. The literature alludes to factors such as tobacco use and exposure to formaldehyde without any substantiation.<sup>5</sup> The diagnosis of malignant mucosal melanoma is based on the demonstration of intracellular melanin under light microscope, tyrosinase activity by dopa reaction on fresh tissue and demonstration of premelanosome by electron microscope.<sup>2,5</sup>

The "typical" tumor shows epithelioid and/or spindle cells

with pleomorphism, large nuclei and mitosis. Eosinophilic macronucleoli are seen in the epithelioid cells. Melanin content may be variable. Demonstration of melanin in these lesions ranges from 50% to 70%. Remaining cases lack pigmentation and diagnosed as amelanotic melanoma. It has been reported that Immunohistochemical staining with HMB-45 is useful for the cytological and histological diagnosis of amelanotic melanoma. The HMB-45 antibody stains a 10 kDA cytoplasmic glycoprotein thought to be a part of the premelanosome complexes.<sup>4,6</sup>

The tumor often assumes many others 'faces' and may have signet ring, balloon rhabdoid and round cells making diagnosis difficult. It is, therefore, emphasized by many authors that melanoma be listed in the differential diagnosis of poorly differentiated malignancy. Immunohistochemical analysis remains a deciding factor in establishing a diagnosis of melanoma. Antibodies used in Immunohistochemical analysis include S-100, HMB45 and Melan-A/MART 1. Literatures have mentioned that S-100 is more likely to be positive in the spindle cells and HMB-45 in the epithelioid cells. Neither cytokeratins antibodies nor leukocytic antigen/antibodies react with melanoma cells. Tumor in our patient was melanotic/dark colored grossly and melanin pigments were readily appreciated in cytoplasm of many tumor cells under the light microscope. Tumor cells demonstrated strong positivity for S-100 and HMB-45.<sup>4,5,7,8</sup>

Three conditions that help to identify as a primary malignant melanoma are: (1) the tumor should be the dominant lesion, (2) there may be local and regional metastasis, and (3) the patient should have no history of a primary cutaneous or ocular melanoma of nevus that regressed spontaneously. The hallmark of a primary malignant melanoma is the presence of junctional activity in the overlying or adjacent mucosa. Many authors state that malignant cells must be identified in the surface epithelium to establish a diagnosis of a primary malignant melanoma. However, given the identification of melanocytes in both the mucoserous glands and in the submucosal compartment of the larynx, it is entirely possible that a malignant melanoma arising in the larynx may take origin from melanocytes in the submucosa and not arise

from the surface epithelium. Thus, the presence of an in situ or junctional component is not required to postulate origin from the laryngeal mucosa. In case in which an intact epithelium is seen and junctional activity is not identified, a metastasis certainly must be excluded. In our case, malignant cells were clearly seen in the surface of epithelium. With no other identifiable malignant lesion, no history of self regressed naevus and the presence of in situ or junctional component, the present case was diagnosed as primary malignant mucosal melanoma of larynx.<sup>1,9</sup>

The treatment of choice for mucosal malignant melanoma, including laryngeal melanoma, is complete surgical excision, with or without adjuvant radiotherapy or chemotherapy. Although surgery remains the treatment of choice, radiation therapy potentially may offer a greater chance at local control of the primary neoplasm, resulting in longer remission periods. And, radiation may be of benefit as the initial mode of treatment in mucosal melanomas. Benefits of chemotherapy and immunotherapy for the patient remain unproven.<sup>1,8,9</sup>

The average survival rates for patients with LMM usually are less than 3.5 years. The literature have mentioned that 5- year survival rate and distant metastasis rate of stage I (N0 M0) primary mucosal melanoma of head and neck were 30.8% and 44% respectively. And, the overall 3- and 5-year survival rates were 28.6% and 7.1% respectively.<sup>8,9</sup>

## CONCLUSION

Mucosal melanoma represents aggressive and highly lethal tumors. The diagnosis is dependent on histological evaluation, and, the use of immunohistochemistry is a key to diagnosis in most of the cases. Despite all the therapeutic efforts to control mucosal malignant melanoma of the larynx, the overall 5 years survival rate remain very poor.

## REFERENCES

1. Lengyel E, Gilde K, Remenar E, Esik O. Malignant mucosal melanoma of the Head and Neck – a review . Pathology Oncology Research 2003;9:7-12. Crossref
2. Pour MAH, Rad M, Zarei MR, and Chamani G. Malignant mucosal melanoma of the Head and Neck diagnosed in an Iranian population in over an 11 – year period. American Journal of Applied Sciences 2009;6:1467-72. Crossref
3. Lakhtakia R, Mehtra A, Nema SK. Melanoma: A frequently missed diagnosis. MJAFI 2009;65:292-94. Crossref
4. Oguri H, Izumiya C, Maeda N, Fukaya T, Moriki T. A primary amelanotic melanoma of the vagina, diagnosed by Immunohistochemical staining with HMB-45, which recurred as a pigmented melanoma J Clin Pathol 2004;57:986–8. Crossref
5. Tomonori T, Nobuo S, Kunichika T et al. Primary malignant melanoma of the larynx: A case report and literature review. Auris Nasus Larynx 2007;34:105-10. Crossref
6. Manolidis S, Donald PJ. Malignant mucosal melanoma of the head and neck. Review of the literature and Reports of 14 patients. Cancer 1997;80:1373-86. Crossref
7. Hesham MA, Petruzzelli GJ, Husain AN, Nickoloff BJ. Primary Malignant Melanoma of the Larynx. Arch Pathol Lab Med 2001;125:271-73.
8. Wenig BM. Laryngeal mucosal malignant melanoma. A clinicopathologic Immunohistochemical and ultrastructural study of four patients and a review of the literature. Cancer 1995;75:1568-77. Crossref
9. Durai R, Hashmi S. Primary malignant melanoma of the epiglottis: a rare presentation. Melanoma Research 2010;20:233-39