



Case Report

Extra - Intestinal Gastrointestinal Stromal Tumor of Omentum.

Basnet S¹, Lakhey A¹

¹Department of pathology, KIST medical college, Lalitpur, Nepal

Keywords:

Abdominal mass;
Mesenchymal tumor;
CD117.

ABSTRACT

Gastrointestinal stromal tumors are rare tumors, constituting less than 3% of all gastrointestinal malignant neoplasms but are the most common mesenchymal tumors of the gastrointestinal tract. Approximately 10% of gastrointestinal stromal tumors are extraintestinal and mostly arise from the mesentery or omentum. Here we report a rare case of an extraintestinal gastrointestinal stromal tumor of mesentery. Morphological and immunohistochemical features led to a diagnosis of extra-gastrointestinal stromal tumor.

INTRODUCTION

Gastrointestinal stromal tumors (GISTs) are rare and account for 0.1%-3.0% of all gastrointestinal neoplasms.¹ Gastrointestinal stromal tumors (GISTs) are the most common mesenchymal neoplasms of the gastrointestinal tract. Extragastric stromal tumors, by definition, arise from outside the GI tract but histologically resemble their GI counterparts. Although stromal tumors in the gastrointestinal tract commonly metastasize to the omentum and mesentery, they may also occur as primary tumors outside the gastrointestinal tract, especially in the omentum and the mesentery.² A case of a 60 year-old man who had an extraintestinal gastrointestinal stromal tumor of mesentery is reported.

Correspondence:

Dr. Sunila Basnet, MD

Department of Pathology, KIST medical college, Lalitpur, Nepal

Email: sunila77@hotmail.com

CASE REPORT

Sixty years-old man patient was admitted with complains of abdominal distention for last 4 years, abdominal pain increasing in intensity for 4-5 days and vomiting for one day. Abdominal distension was gradual in onset. Patient complained of generalized abdominal pain which later on became continuous, severe and did not relieve with analgesics.

On examination, his vitals were stable. Abdominal examination revealed generalized tenderness with abdominal distension. An intra-abdominal hard mass was palpable, with distinct margin, not moving with respiration. On percussion it was dull and without any bowel sound over it, without shifting dullness

Investigation; Previous CT scan done 4 years back revealed presence of enhancing soft tissue lesion in perihepatic

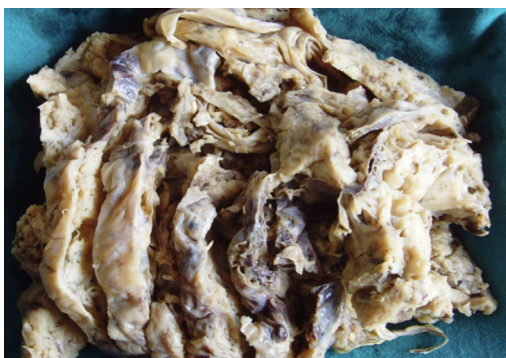

Figure 1: Macroscopic appearance of Tumor

space. USG showed hemorrhagic collection in lesser sac. Patient was operated under general anaesthesia. Tumour was resected and sent to department of pathology.

Histopathological findings

Grossly there was a well circumscribed and encapsulated hemorrhagic mass weighing 2 kg and measuring 23x20x5 cm. External surface was smooth with bulged out nodular surface. Cut surface showed solid and cystic areas with multiple and variable sized interconnecting spaces, the largest measuring 5.5 cm in diameter. Cystic cavity was filled with serous fluid. Other foci showed hemorrhagic areas.

On microscopic examination, sections from the cyst wall showed irregular thickened areas lined by attenuated endothelial cells. The variable sized vascular spaces were filled with red blood cells or nodular aggregates of lymphocytes. Sections from the solid areas showed proliferating bundles and fascicles of spindle cells with elongated nuclei. The tumor cells were mildly pleomorphic with slight increase in cellularity. Mitotic figure ranged < 5/50 hpf. The stroma composed of fibrillary collagen with foci of nodular aggregates of lymphocytes. Necrosis was absent. The diagnosis of extra-intestinal gastrointestinal stromal tumor (GIST) was suggested with further confirmation by Immunohistochemistry. Immunohistochemically showed diffuse positivity for CD117.

DISCUSSION

GIST arises from the wall of the gastrointestinal (GI) tract and is thought to originate from the Interstitial Cells of Cajal (ICC), which regulate the motility of the gastrointestinal tract.³ The discovery of the mutation of KIT (CD117) in GIST proto-oncogene was fundamental in order to understand the genesis and classification of these tumors.³ The observation that ICC can be immunohistochemically highlighted with an antibody to CD117 lead to the discovery that it is also strongly expressed in most GISTs.¹⁻² GISTs are defined as spindle cell, epithelioid, or occasionally

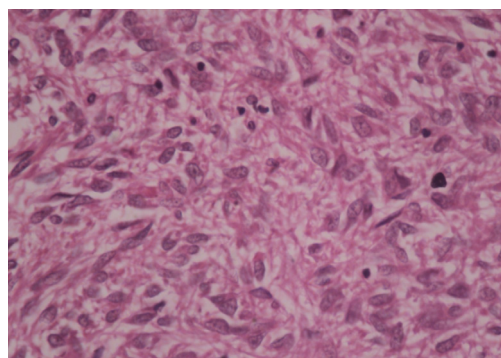


Figure 2: Photomicrograph showing proliferating bundles and fascicles of spindle cells with elongated nuclei (HE stain; X400).

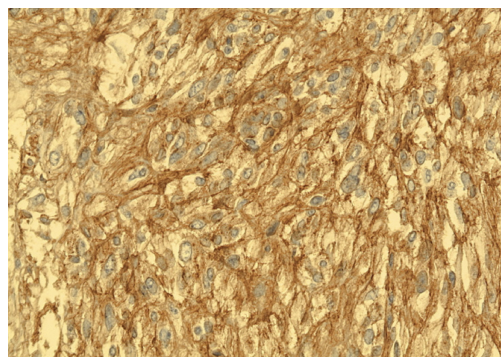


Figure 3: Immunohistochemistry spindle cells stain positive for CD117 (X100)

pleomorphic mesenchymal tumors of the gas-trointestinal tract, which express the CD117 protein detected at immunohistochemistry.⁴

GISTs have been documented in all parts of the gastrointestinal tract: especially in the stomach (60% to 70%) and small intestine (25% to 35%), with rare occurrence in the colon and rectum (5%), esophagus (2%) and appendix, gallbladder and pancreas.⁵⁻⁶ Some GISTs, primary in the omentum, mesentery or retroperitoneum, are unrelated to the tubular gastrointestinal tract and are called Extra-gastrointestinal Stromal Tumor (EGISTs).³ EGISTs are identical by histological and immunohistochemical features with GISTs.³ EGISTs show staining of CD117, marker of Interstitial Cells of Cajal which are normally present just in the gut wall.³

It is difficult to differentiate a GIST in the lesser omentum from a GIST in the lesser curvature of the stomach, despite the use of advanced radiological imaging techniques. About half of all omental GISTs are misdiagnosed as extra mucosal tumors of the stomach.⁷⁻⁹ Additionally, omental EGISTs seem to be morphologically and immunohistochemically identical to their gastric and intestinal counterparts. They are cellular tumors consisting of elongated spindle and epithelioid cells that are typically positive for CD117 and, less consistently, for CD34. They may show smooth muscle

actin positivity but are negative for desmin and S-100 protein.

Extra-intestinal GIST expressed CD117 (100%), CD34 (50%), neuron-specific enolase (44%), smooth muscle actin (26%), desmin (4%), and S-100 protein (4%).³ Diagnosis of a CD117 negative GIST can be supported by immunostains for desmin and the S-100 protein, which exclude smooth muscle tumors and neural tumor like schwannomas.^{4,10} DOG1.1 is an especially sensitive immunohistochemical marker for GIST, and has potential for clinical use in the routine diagnosis of GIST.¹¹

It should be noted here that, according to the National Institutes of Health algorithm for assessing malignancy of classical GISTs,⁴ most omental EGISTs would be classified as high-risk due to their large size alone, as in at least 55% of published cases it exceeds 10 cm. However, the tumor size is not a reliable prognostic parameter in the case of EGISTs.

Previously, the only proven treatment was surgical resection. Radiation therapy and chemotherapy have been ineffective. However, specific therapy targeting the CD117 receptor with imatinib has resulted in improved outcomes for patients with unresectable, metastatic, and recurrent disease.¹²

CONCLUSION

GIST is the most common mesenchymal neoplasm in the gastrointestinal tract. However, it may also arise beyond GI tract. Thus, EGIST should be kept in mind while diagnosing omental mass.

REFERENCES

1. Hirota S, Isozaki K, Moriyama Y, et al. Gain-of-function mutations of c-kit in human gastrointestinal stromal tumors. *Science* 1998;279:577-580. [Crossref](#)
2. Kindblom LG, Remotti HE, Aldenborg F, Meis-Kindblom JM. Gastrointestinal pacemaker cell tumor (GIPACT): gastrointestinal stromal tumors show phenotypic characteristics of the interstitial cells of Cajal. *Am J Pathol* 1998;152:1259-1269. PMID:9588894
3. Claudio Casella, Vincenzo Villanacci, Fillippo, Manuela Codazzi and Bruno Salerni. Primary extra gastrointestinal stromal tumor of retroperitoneum. *Clinical medicine insight: Oncology* 2012;6:189-197. PMID:22563251
4. Burkill G J C, Badran M, Muderis O A, Thomas JM. Malignant Gastrointestinal Stromal Tumor: Dis-tribution, Imaging Features, and Pattern of Metastatic spread. *Radiology* 2003; 226: 527-32. [Crossref](#)
5. Miettinen M, Sarlomo-Rikala M, Sobin LH, Lasota J: Esophageal stromal tumors: a clinicopathologic, immunohistochemical, and molecular genetic study of 17 cases and comparison with esophageal leiomyomas and leiomyosarcomas. *Am J Surg Pathol* 2000;24:1339-52. [Crossref](#)
6. Miettinen M, Sobin LH: Gastrointestinal stromal tumors in the appendix: a clinicopathologic and immunohistochemical study of four cases. *Am J Surg Pathol* 2001;25:1433-7. [Crossref](#)
7. Lee JT, Kim MJ, Yoo HS, et al. Primary leiomyosarcoma of the greater omentum: CT findings. *J Comput Assist Tomogr* 1991;15:92-4. [Crossref](#)
8. Ikematsu Y, Usui K, Kamohara Y, et al. Leiomyoma of the lesser omentum: report of a case. *Surg Today* 1996;26:46-8. [Crossref](#)
9. Sasamoto A, Yamaguchi A, Isogai M, et al. [A case of primary leiomyosarcoma of the lesser omentum]. *Nippon Rinsyou Geka Gakkai Zasshi [Article in Japanese]* 1998;59:1409-13.
10. Antonescu CR. Targeted therapy of cancer: new roles for pathologists in identifying GISTs and other sarcomas. *Mod Pathol* 2008;21 Suppl 2:S31-S36. [Crossref](#)
11. Espinosa I, Lee CH, Kim MK, et al. A novel monoclonal antibody against DOG1 is a sensitive and specific marker for gastrointestinal stromal tumors. *Am J Surg Pathol* 2008;32:210-218. [Crossref](#)
12. Schubert M L, Moghimi R. Gastrointestinal stromal tumor (GIST). *Curr Treat Options Gastroenterol* 2006; 9(2): 181-8. [Crossref](#)