



Case Report

Peutz-Jeghers syndrome: A case report and literature review

Lakhey A¹, Shakya H²

¹Department of Pathology, Kist medical college, Lalitpur, Nepal

²Department of Pediatrics, Kist medical college, Lalitpur, Nepal

Keywords:

Mucocutaneous;
Pigmentation;
Gastrointestinal polyps;
Hamartoma.

ABSTRACT

Peutz-Jeghers Syndrome is an autosomal dominant inherited hamartomatous polyp. We present a case of a 5-year-old young boy with a history of per rectal bleeding and mass protruding out of the anus. Physical examination revealed presence of mucocutaneous pigmented lesions over the tongue, and few hamartomatous polyps protruding out of the rectum suggesting Peutz-Jeghers syndrome. The presence in early infancy of small, well-demarcated and dark-brown to blue-black lentiginos on the lips, buccal mucosa and perioral skin, should alert the clinician to Peutz-Jeghers Syndrome.

INTRODUCTION

Peutz-Jeghers Syndrome (PJS) is an inherited autosomal dominant disorder distinguished by hamartomatous polyps in the gastrointestinal tract and mucocutaneous lesions. Inheritance is autosomal dominant with a pleiotropic gene. Inactivation of this gene by germline mutations or loss of normal allele can result in hamartomatous polyps.

Prevalance of PJS is estimated from 1 in 8,300 to 1 in 280,000.¹⁻⁷ Well documented data on the incidence are not available.⁷ It is accepted to be a precancerous syndrome. The polyps can cause anaemia and intestinal obstruction and intussusception.⁸ Those polyps are present from childhood.⁹ The relative risk of dying from a gastrointestinal

cancer is 13 fold elevated.¹⁰ Melanotic spots are the earliest manifestation of PJS, typically appearing in the first year of life.⁹ Extra-intestinal tumors associated with Peutz-Jeghers syndrome include ovarian, uterine cervix, testicular, breast, thyroid, bile duct, pancreas and gall bladder.¹¹

CASE REPORT

A 5-year-old boy came to the ER with history of bleeding per rectum. Examinations showed a protruding rectal mass. Pigmented lesions were seen on the buccal mucosa and lower lip (fig.1). Mother noted pigmented spots when he was 5 years old. No family history of PJS or any other polyposis syndrome could be verified and both parents are free of symptoms. The mass was resected and sent for histopathological evaluation. Grossly the mass measured 6x5x4cm. The mass was soft and reddish to brownish with several adhered polyps (fig.2). Histologically, the polyps

Correspondence:

Dr. Ashish Lakhey MD

Kist medical college and hospital

Gwarko, Lalitpur, Nepal

Phone: +977-9846219215, E-mail: aashishlakhey@hotmail.com

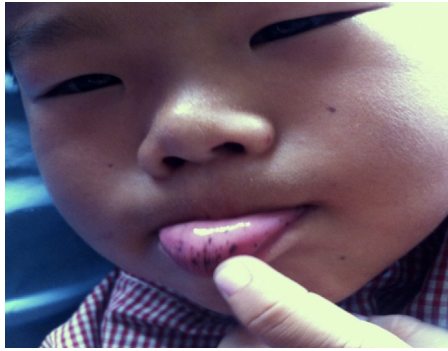

Figure 1: Mucocutaneous pigmentation in the lower lip.



Figure 2: Multiple polyps of different sizes and shapes seen

exhibited arborization of muscularis mucosae covered with normal villi and was defined as a hamartoma, thus confirming the clinical diagnosis of Peutz-Jeghers Syndrome (fig. 3).

DISCUSSION

The first clear cut association of melanin pigmentation of the lips and buccal mucosa with intestinal polyposis was reported by Peutz in 1921. American physician Jegher published 10 additional cases in 1944.¹²

The World Health Organisation clinico-pathological criteria for diagnosing this rare disorder are:

1. Three or more polyps, which show histological features consistent with PJS.
2. A family history of PJS with any number of PJs.
3. A family history of PJS with characteristic mucocutaneous pigmentation.
4. Characteristic mucocutaneous pigmentation with any number of PJs.¹²

The characteristic pigmentation is present in more than 90% of the PJS cases. The pigmented macule may be present at birth but usually develop in early childhood, and even may develop later in life occasionally. Round, oval or irregular patches of brown or almost black pigmentation 1-5 mm in diameter are most commonly found around the mouth, nose, lower lip, buccal mucosa, hands and feet.⁹

The Peutz-Jeghers polyp is a unique hamartomatous lesion characterized by glandular epithelium that covers an arborizing framework of well-developed smooth muscle that is continuous with the muscularis mucosae. These polyps are usually multiple and their distinctive appearance, in association with extra-intestinal manifestations, makes Peutz-Jeghers syndrome easily identifiable.⁹

The most common location for polyps is the small bowel

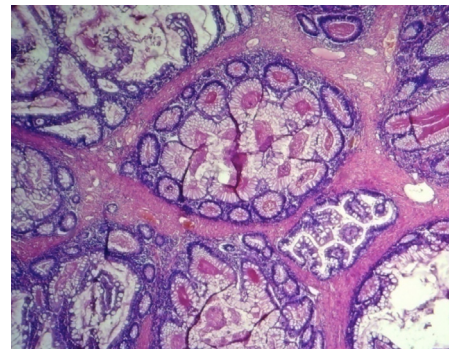


Figure 3: Microscopic section of a polyp showing arborizing muscular framework (HE stain, X 400).

(64%), although involvement of the colon (53%) stomach (49%) and rectum (32%) is also described. Usually there are fewer than 20 polyps present in each case, varying in size from several millimeters to more than 5 cm diameter.⁹

Patients are diagnosed usually in the second or third decade of life and common presentations include abdominal pain, rectal bleeding, anemia, small intestinal intussusception, bowel obstruction, and rectal prolapse of polyps.¹³ Abdominal symptoms tend to occur early in life, with more than 50% symptomatic patients before the age of 20.^{9,14}

Although it has been found that there is a high cancer risk in PJS patients according to John Hopkin's hospital polyposis registry 6, no cancer was found in our patient's polyps.

Over the years, the standard therapy for Peutz-Jeghers syndrome has been laparotomy and bowel resection to remove symptomatic gastrointestinal polyps that cause persistent or recurrent intussusceptions. However, some patients require multiple surgical resections, which can lead to short gut syndrome. Because of this, it has been recommended that endoscopy be performed to remove all polyps. During each laparotomy, the small bowel should be examined by means of intraoperative enteroscopy. Nowadays, double balloon enteroscopy in combination with capsule enteroscopy are the gold standard for the diagnosis

and treatment of the small bowel hamartomatous polyps.¹

CONCLUSION

Peutz Jegher should be suspected in a child who presents with mucocutaneous pigmentation with gastrointestinal polyps. These patients should be regularly and closely monitored because of the risk of cancer and to reduce other morbidities.

REFERENCES

- Kopacova M, Tacheci I, Rejchrt S, Bure J. Peutz-Jeghers syndrome: Diagnostic and therapeutic approach. *World J Gastroenterol* 2009;15:5397-5408. [Crossref](#)
- Miyaki M. Peutz-Jeghers syndrome. *Nippon Rinsho* 2000;58:1400-4. PMID:10921312
- Choi HS, Park YJ, Youk EG et al. Clinical characteristics of Peutz-Jeghers syndrome in Korean polyposis patients. *Int J Colorectal Dis* 2000;15:35-8. [Crossref](#)
- Westerman AM, Entius MM, de Baar E, et al. Peutz-Jeghers syndrome: 78-year follow-up of the original family. *Lancet* 1999;353:1211-5. [Crossref](#)
- Choi HS, Park YJ, Park JG. Peutz-Jeghers syndrome: a new understanding. *J Korean Med Sci* 1999;14: 2-7. [Crossref](#)
- Itzkowitz SH, Kim YS. Colonic polyps and polyposis syndromes. Feldman M, Scharschmidt BF, Sleisenger MH Sleisenger & Fordtran's *Gastrointestinal and Liver Disease*. 6th Edition. Philadelphia, WB Saunders, 1998, pp113.
- Aaltonen LA, Jarvilen H, Gruder SB, Billaud M, Jass JR. Peutz-Jeghers Syndrome. In: Hamilton SR and Aaltonen LA, editors. *World Health Organization Classification of Tumours. Pathology and Genetics of Tumours of the Digestive System*. Lyon, France: IARC Press; 2000. pp.74-6.
- Mozaffar M, Sobhie MR, Hasani M, Fallah M. Peutz-Jeghers syndrome without mucocutaneous pigmentation: a case report *Gastroenterol Hepatol Bed Bencha* 2012;5:169-73.
- Georgescu E. F., Stansescu L, Simionescu C, Georgescu I, Inoescu R, Florescu G. Peutz-Jeghers Syndrome: Case report and literature review. *Romanian Journal of Morphology and Embryology* 2008;49:241-5. PMID:18516333
- Saranrittichai S. Peutz-Jeghers Syndrome and Colon Cancer in a 10-Year-Old Girl: Implications for When and How to Start Screening? *Asian Pacific Journal of Cancer Prevention* 2008; 9:159-61. PMID:18439097
- Almoutaz A El Tayeb, Naglaa H. Ibrahim, Azza A. El Tayeb, AE. Essa. Peutz-Jeghers Syndrome in Children and Adolescents. *Annals of Pediatric Surgery* 2008;4:37-4.
- Girvin S, Glancy M, Dunlop M. Peutz-Jeghers syndrome: a case report and discussion of surveillance recommendations. *Eur J Radiol Extra* 2007;62:81-4. [Crossref](#)
- Mcgarrrity T.J., Amos C., Peutz-Jeghers Syndrome: clinicopathology and molecular alterations, *Cell Mol Life Sci* 2006;63:2135-44. [Crossref](#)
- Tovar JA, Eizaguirre AA, Jimenez J. Peutz-Jegher syndrome in children: report of two cases and review of literature. *J Pediatr Surg* 1983;1:18.