

# Chlorpromazine Induced Cataract in a female patient: A Case Report

Nidhi Rajeshwori Thapa,<sup>1\*</sup> Deepika Karki,<sup>2</sup> Asim Shrestha,<sup>2</sup> Pradip Man Singh,<sup>1</sup>

1. Department of Psychiatry, Nepal Medical College and Teaching Hospital, Kathmandu, Nepal.

2. Nepal Medical College and Teaching Hospital, Kathmandu, Nepal.

## Abstract

Tablet Chlorpromazine is a commonly used, affordable antipsychotic in developing countries. Chlorpromazine induced cataract and corneal pigmentation was first described by Greiner & Berry in 1964 but in the context of Nepal, there is no available literature or cases reported to date.<sup>1</sup> Despite having a myriad of side effects, it is still used frequently in developing countries due to its cost-effectiveness. In this light, we report a case of a 43-year-old female with a diagnosis of Schizophrenia who had been treated with Tab. Chlorpromazine for 25 years. She lost to follow-up and presented at the OPD with cataract in bilateral eyes.

Keywords: Antipsychotic agents; cataract; chlorpromazine; schizophrenia

## \*Correspondence Author

Dr. Nidhi Rajeshwori Thapa

Nepal Medical College and Teaching Hospital,  
Jorpati, Kathmandu, Nepal  
Email: thapanidhi2015@gmail.com

## INTRODUCTION

Chlorpromazine is an aliphatic phenothiazine derivative used primarily as an antipsychotic agent and in the treatment of nausea and vomiting.<sup>2</sup> It is a commonly used affordable antipsychotic in developing countries like Nepal. Amongst many side-effects, its long-term use i.e. dose >300mg per day for longer than 90days, has been associated with 3.5% risk of developing cataract.<sup>3</sup> Another study states the prevalence ranges from 15% to 74%, but in the context of Nepal there is no available literature.<sup>4</sup> We report a case of a 43-year-old female under long-term maintenance therapy of Tab. Chlorpromazine who subsequently developed cataract.

## CASE REPORT

A 43-year-old female from a low socioeconomic background with a diagnosis of Schizophrenia (ICD-10) for the past 25 years had been under the medication Tab. Chlorpromazine for the chief complaint of hallucinatory and disorganized behavior. In the past 25 years, the maximum dose of Tab. Chlorpromazine used was 400mg/day and the minimum dose used was 100mg/day. The course of treatment was augmented with on and off use of

Tab. Amisulpride, Tab. Olanzapine and Tab. Risperidone. Throughout the course of the disorder the patient party preferred Tab. Chlorpromazine over other medications as it was cheaper and patient was more manageable with its use. For the past three years, the patient started complaining of blurring of vision in both her eyes for which an ophthalmology consultation was advised. The patient lost to follow up and presented with visual impairment in both her eyes. On ocular examination, the visual acuity of the right eye was 3/60 and there was no perception of light in the left eye. Hirschberg corneal reflex test revealed 45-degree exotropia of left eye whereas right eye was normal. Penlight examination revealed normal pupils. On slit-lamp examination of the eyes, corneal endothelial deposits were seen in both eyes. After dilatation of pupils, a stellate-shaped cataract of the right eye (Figure 1) and a mature cataract of the left eye were seen (Figure 2). Fundus evaluation of the right eye was normal; however, fundus evaluation of the left eye couldn't be done due to the presence of the mature cataract.

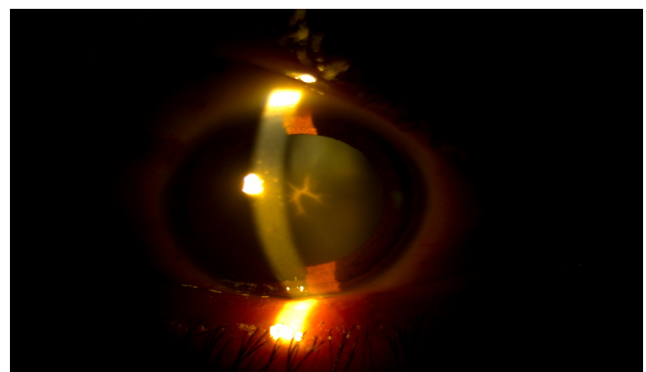


Figure 1. Right eye slit lamp examination: Anterior capsular cataract with the stellate pattern.




Figure 2. Left eye slit lamp examination: Mature cataract.

Rest of the physical examination and baseline laboratory investigations including complete blood count, random blood sugar, renal function test, lipid profile and, urine routine examination were normal. Patient's Tab. Chlorpromazine was stopped and substituted with Tab. Amisulpride and Tab. Clozapine. There is no history of steroid use, radiation therapy, diabetes mellitus or any other medical disease, smoking, eye trauma or eye surgery and no family history of cataract.

## DISCUSSION

Cataract is a degenerative condition which affects majority of elderly people. Due to aging of the world's population, cataract-induced blindness and visual dysfunction are on the rise making it a significant global problem. The challenges are to prevent or delay cataract formation and treat those which do occur.<sup>3</sup> Causes of cataract other than senile cataract are-hereditary, trauma, metabolic causes (diabetes), electric causes, radiation, substances like corticosteroids, miotics, copper and iron, skin diseases, osseous diseases, etc.

A case series reported dermatological and ocular complications with long-term phenothiazine use in the form of pigment deposits in the cornea, lens, and skin. The cases were mostly seen in women who received doses of 500 to 1500 mg on average.<sup>5</sup>

Similar studies have been conducted elsewhere.<sup>6,7</sup> An experimental study done on guinea pigs by feeding them large doses of Chlorpromazine and exposing them to UV rays resulted in albino and pigmented animals, finding

similar to humans receiving the same drug in high doses. Further progressive increasing deposition of Chlorpromazine with increased treatment was seen in the lens.<sup>8</sup>

The exact mechanism behind the deposition of these opacities has been unclear but proposed mechanisms include alteration of the respiratory mechanism of a lens by a metabolic block at a site preceding succinate.<sup>9</sup> Also cataract may be a representation of the denatured protein foci due to interaction of light with the drug, a photosensitizing agent, and lens protein, or possibly deposits of drug within the lens.<sup>8</sup>

Despite various documented changes on lens opacities by Chlorpromazine worldwide, there is a scarcity of literature in the context of Nepal. It is still the first choice of treatment for Schizophrenia since the drug is listed amongst the Nepal government's list of essential drugs making it is easily available and economical. Our case had no known risk factors for the development of cataract other than the use of Tab. Chlorpromazine with a dose of more than 300mg per day for a long duration. This case highlights the need of regular follow up in- order to prevent complications that result from long term use of Tab. Chlorpromazine.

## CONCLUSION

Though Tab. Chlorpromazine is still a commonly used antipsychotic in Nepal, physicians should remain alert of its side effects. This case emphasizes the need for routine follow-up including eye checkups in such patients in- order to prevent ophthalmological complications along with other foreseeable outcomes.

## ACKNOWLEDGEMENTS

We are grateful to the patient and her family for their support and for giving consent. We are also thankful to Dr. Pradip Man Singh, Head of Department of Psychiatry, NMCTH, for providing insight into the case. Also, we would like to extend our gratitude to the Department of Ophthalmology, NMCTH, especially to Dr. Dikshaya Pradhan and Dr. Rosy Manandhar, for their continuous support.

## References

1. Greiner AC, Berry K. Skin pigmentation and corneal and lens opacities with prolonged chlorpromazine therapy. *Can Med Assoc J.* 1964 Mar 14;90(11):663-5. [PubMed | Full Text]
2. Sadock BJ, Sadock VA, Ruiz P. Kaplan and Sadock's Comprehensive Textbook of Psychiatry. 10th edition. Philadelphia (PA): Lippincott Williams & Wilkins (LWW); c2017. 12752 p.[Full Text]
3. Brian G, Taylor H. Cataract blindness--challenges for the 21st century. *Bull World Health Organ.* 2001;79(3):249-56. Epub 2003 Jul 7. [PubMed | Full Text]
4. Subashini K, Rao V A. Chlorpromazine-induced cataract and corneal pigmentation. *Indian J Pharmacol* 2004;36:323-4. [Full Text]
5. Ruigómez A, García Rodríguez LA, Dev VJ, Arellano F, Raniwala J. Are schizophrenia or antipsychotic drugs a risk factor for cataracts? *Epidemiology.* 2000 Nov;11(6):620-3. [PubMed | Full Text | DOI]
6. Leung AT, Cheng AC, Chan WM, Lam DS. Chlorpromazine-induced refractile corneal deposits and cataract. *Arch Ophthalmol.* 1999 Dec;117(12):1662-3. [PubMed | Full Text | DOI]
7. Divakaran A, Rao NP, Venkatasubramanian G, Behere RV, Varambally S, Gangadhar BN. Chlorpromazine induced cataract in a young patient with schizophrenia. *Indian J Psychol Med.* 2010 Jan;32(1):69-70. [PubMed | Full Text | DOI]
8. Howard RO, McDonald CJ, Dunn B, Creasey WA. Experimental chlorpromazine cataracts. *Invest Ophthalmol.* 1969 Aug;8(4):413-21. [PubMed | Full Text]
9. DeLong SL, Poley BJ, McFarlane JR Jr. Ocular changes associated with long-term chlorpromazine therapy. *Arch Ophthalmol.* 1965 May;73:611-7.[PubMed | Full Text | DOI]