

Fronto-temporal Lobe Epilepsy Presenting as Intermittent Outburst of Anger: A Case Report from Eastern Nepal

Neeraj Acharya^{1*}, Sonali Nayak¹, Suraj Nepal², Bhupendra Shah¹

1. Department of Internal medicine, B.P. Koirala Institute of Health Sciences
2. Department of Psychiatry, B.P. Koirala Institute of Health Sciences

Abstract

INTRODUCTION

Episodes of rage and anger with violent outbursts are common manifestations of various psychiatric and behavioral disorders. Though rare, it can be a manifestation of frontotemporal lobe epilepsy which is often misdiagnosed. Here we present a case of 20 years male having intermittent episodes of anger and violent outburst for three years who was later diagnosed as a case of frontotemporal lobe epilepsy.

KEYWORDS

Nepal; Rage attacks; Temporal lobe epilepsy

*Corresponding Author

Dr. Neeraj Acharya

Department of Internal Medicine

B.P. Koirala Institute of Health Sciences

Email: neerajach10@gmail.com

INTRODUCTION

An anger outburst or rage attack is an intermittent episode of disproportionate explosive aggression.^{1,2} Although it is a common manifestation of psychiatric diseases like impulse control disorder, mania, and dissociative disorder, it can rarely occur as a manifestation of temporal lobe epilepsy.² Differentiating temporal lobe epilepsy from other psychiatric disorders as a cause of anger outbursts has a huge implication in patient management. Hence, we are reporting a case of a 20-year-old male who presented with anger outbursts for the last 3 years and was later diagnosed as a case of temporal lobe epilepsy.

CASE REPORT

A 20-year-old patient presented to the medical outpatient department with a complaint of episodic anger outburst of 5 to 10 minutes duration. He presented with violently hitting others and breaking nearby objects for three years. These episodes were preceded by severe occipital headache. During such episodes, the patient had history of not responding to verbal commands. After termination of such an outburst, he had a history of fatigability for 20-30 minutes duration. The patient was asymptomatic between episodes. In the past, he had a history of febrile seizure up to 3 years of age which subsided on its own. Her mother delivered him after prolonged labor but his developmental milestones were normal. He is a non-smoker and non-alcohol consumer. He left his school in class nine due to poor academic performance.

Detailed physical and neurological examinations were normal. On psychiatric consultation, his Intelligence quotient was 60 (mild mental retardation). Routine blood and urine

investigations were within normal limits. Based on history, neurological examination, psychological evaluation, and appropriate laboratory tests, differential diagnoses of the intermittent explosive disorder, dissociative disorder, and focal emotional seizure were made. Non-contrast Computed tomography (NCCT) head was normal as shown in *figure 1*. Waking state 20-minute Electro Encephalogram Gram (EEG) showed epileptiform discharges from the left frontotemporal region as shown in *figure 2*. We made a diagnosis of Frontotemporal focal epilepsy and started on Tablet Carbamazepine 200 milligram twice daily. He was on remission for 3 years, then left medication without doctor's advice. After not taking medication for 3 days, he had another episode of anger burst for one hour which stopped on taking injection Diazepam 5 mg and tablet carbamazepine 200 milligrams twice a day.

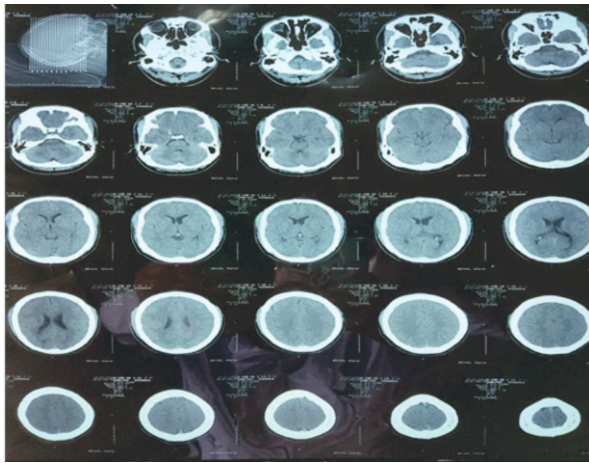


Figure 1: NCCT head of the patient showing normal scan.

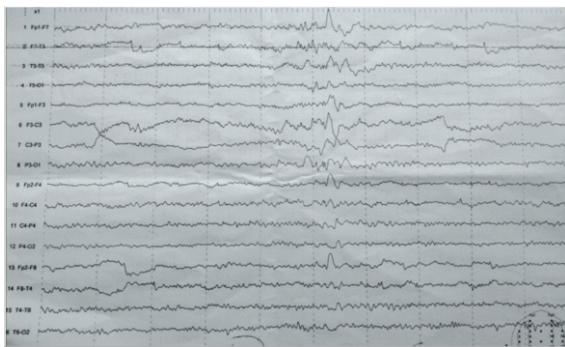


Figure 2: Waking state EEG showing spikes/epileptiform discharges on left frontotemporal region.

DISCUSSION

We made the diagnosis of Frontotemporal epilepsy in this patient based on the episodic nature of symptoms, amnesia

of the incident, poorly directed violent behavior, postictal symptoms of fatigability, EEG showing frontotemporal discharges, patient responding to anticonvulsant, and recurrence of symptoms after stoppage of the anticonvulsant. Similar to our case, Saha et al, reported an 11-year-old child having episodic anger burst due to simple partial seizure who was previously treated as a psychiatric disorder.³ A case of 22 years male with post-encephalitic seizure presenting with episodic violent behavior was reported by L Marsh et al.⁴ Similarly, hitting out at people and kicking hard surfaces has been reported in various case reports as the manifestations of frontal lobe epilepsy.⁵ After review of the available literature, we couldn't find such a case report in our country. So, this is probably one of the few case reports of frontotemporal lobe epilepsy presenting as an anger outburst from Nepal.

Epilepsy, as a cause of altered behavior, has been described in different pieces of literature.^{3,5,6} Seizures may be frequently misdiagnosed if manifested with emotional symptoms as in our patient.⁷ Frontotemporal lobe epilepsy can have varied manifestations including focal seizures with intact awareness, focal seizure with impaired awareness, and secondarily generalized tonic-clonic seizures.⁸ Here in our case, the only symptoms of frontotemporal lobe epilepsy were anger outbursts. Therefore, differential diagnosis of a seizure should be considered in cases of episodic stereotyped behavior with atypical presentations.³ Nonetheless, we had limitations that we couldn't perform an MRI brain because of the financial constraints of the patient's attendant.

CONCLUSION

Frontotemporal lobe epilepsy can have varied clinical manifestations and this may pose a challenge for diagnosis. Since the diagnosis of epilepsy can have significant implications for patients, their families, and therapeutic management, one should consider epilepsy as one of the possibilities when the patient presents with an episodic emotional outburst.

FUNDING SOURCES; NON-FUNDED

Informed consent: Written informed consent was taken from patient and patient's attendant.

ACKNOWLEDGEMENT

We would like to acknowledge patient and patient attendant for giving us consent to write this paper.

REFERENCE

- Budman CL, Bruun RD, Park KS, Lesser M. Explosive Outbursts in Children With Tourette's Disorder. *J Am Acad Child Adolesc Psychiatry.* 1997;39(10):1270-1276. doi:10.1097/00004583-200010000-00014
- Carlson GA, Potegal M, Ph D, Margulies D, Gutkovich Z, Basile J. Rages — What Are They and Who Has Them? *2009;19(3):281-288.*
- Saha R, Srivastava MK, Anand KS. Case Report Psychiatric presentation of childhood epilepsy : Case series and review. *2020:367-372. doi:10.4103/1817-1745.199481*
- Marsh L, Krauss GL. Aggression and Violence in Patients with Epilepsy. *2000;168:160-168. doi:10.1006/ebbeh.2000.0061*
- Gedye A. Episodic rage and aggression attributed to frontal lobe seizures. *1989:369-379.*
- Tisher PW, Holzer JC, Greenberg M, Benjamin S, Devinsky O, Bear DM. Psychiatric Presentations of Epilepsy. *1993:219-228.*
- Mirsattari SM, Gofton TE, Chong DJ. Misdiagnosis of Epileptic Seizures as Manifestations of Psychiatric Illnesses. *2018:487-493.*
- Rosa M PQ. Temporal Lobe Epilepsy : Clinical Semiology and Neurophysiological Studies.; 2007. doi:doi:10.1053/j.sult.2007.09.004