



ISSN: 2091-2749 (Print)
2091-2757 (Online)

Correspondence

Sailuja Maharjan
Dept. of Pathology
B & B Hospital, Gwarko,
Lalitpur, Nepal
Email: sailuzaa73@gmail.com

Peer Reviewers

Asst. Prof. Dr. Ashis Shrestha,
Patan Academy of Health
Sciences, Nepal

Asst. Prof. Dr. Pawan Sharma,
Patan Academy of Health
Sciences, Nepal

Submitted

9 Jun 2022

Accepted






20 Sep 2022

How to cite this article

Sailuja Maharjan, Arun Shahi,
Bandana Satyal, Reena Baidya,
Rajesh Batajoo. Mixed warty
and sarcomatoid squamous cell
carcinoma of vulva: a rare
occurrence. Journal of Patan
Academy of Health Sciences.
2022Dec;9(3):77-80.

<https://doi.org/10.3126/jpahs.v9i3.52222>

Mixed warty and sarcomatoid squamous cell carcinoma of vulva: a rare occurrence

Sailuja Maharjan¹ , Arun Shahi² , Bandana Satyal¹ , Reena Baidya¹ ,
Rajesh Batajoo³ 

¹Pathologist, ²Medical Oncologist, ³Urologist, B & B Hospital, Lalitpur, Nepal

Abstract

Vulvar cancer is a rare tumor accounting for <5% of female genital tract tumors. The most common type of vulvar malignancy is squamous cell carcinoma. There are many histological variants of squamous cell carcinoma, keratinizing type being the most common one. Sarcomatoid variant is an extremely rare variant in vulva and comprises both epithelial and mesenchymal features. Due to the rarity of this tumor in the vulva and limited cases reported in the literature, no proper management guidelines have been established yet. In the current case report, we describe a case of mixed warty and sarcomatoid squamous cell carcinoma of vulva.

Keywords: HPV, sarcomatoid, SCC, vulva, warty

Introduction

Squamous cell carcinoma (SCC) is the most common vulvar malignancy comprising of 95% of all cases.¹⁻³ It predominantly occurs in elderly group with average age of diagnosis being 75y.^{4,5} There are many histologic variants of SCC and sarcomatoid variant is one of them. It is a rare histological entity in female genital tract comprising of 1.8 % of SCC but has been well documented in other anatomic sites like oral cavity, larynx, esophagus and lungs.^{3,6} The clinical behavior of this variant is very aggressive and is associated with early development of local recurrence and distant metastasis.^{7,8} No specific treatment guidelines are available due to its rare occurrence. Herein we report a case of mixed variant of vulvar SCC with warty and sarcomatoid features.

Case Report

A 57-year-old lady presented with complaints of gradually increasing mass in the vulva for five mo. The patient also gives a history of bleeding from the mass associated with local discomfort and pain. Local examination revealed a mass in the left labia majora. It was not adherent to underlying bony structures. There was no involvement of the urethra. The vaginal mucosa and cervix appeared normal. Furthermore, there was no palpable lymphadenopathy in the bilateral inguinal region. Systemic examination was unremarkable. Complete blood test showed neutrophilic leukocytosis and urinalysis showed presence of pus cells. An incisional biopsy was done initially which demonstrated features of SCC. Staging work up did not show any sign of metastasis. Hence, the patient underwent wide local excision of the mass and was sent for histopathological evaluation. Gross examination showed a warty mass measuring 6 x 3 x 2 cm with ulceration (Figure 1). The skin adjacent to the mass demonstrated whitish areas. Histopathological examination showed an undulating warty and frond-like surface lined by dysplastic squamous cells and associated koilocytic atypia. Nests and islands of

moderately differentiated squamous cell carcinoma were seen with presence of keratin pearls (Figure 2a). The deeper areas of the tumor showed spindle shaped tumor cells arranged in bundles and storiform pattern against a myxoid stroma (Figure 2b, 3). Frequent mitotic activity and areas of necrosis were seen. There were no lymphovascular invasion or perineural invasion. Heterologous elements were not identified. All the peripheral and deep margins were uninvolved. Hence, the diagnosis was made as Squamous Cell Carcinoma, Warty type with Sarcomatoid Differentiation. The epidermis adjacent to the tumor showed features of lichen sclerosis.

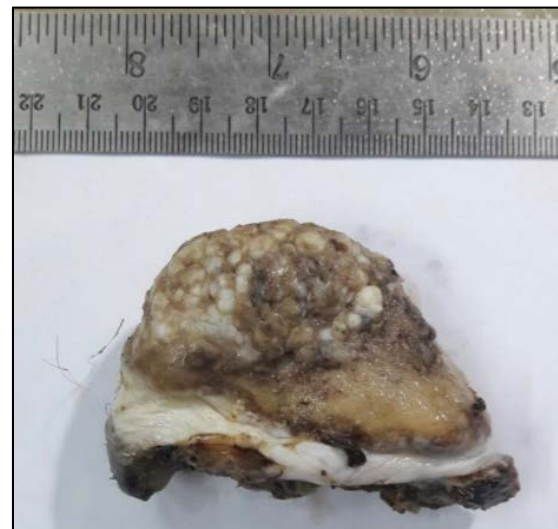


Figure 1. Gross Specimen demonstrating warty appearance and adjacent skin showing whitish sclerotic areas

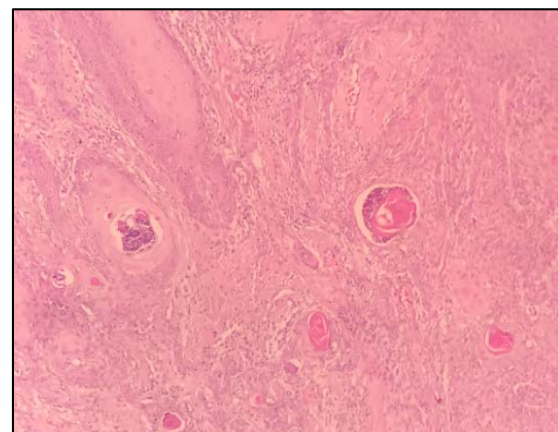


Figure 2a. Microscopy showing moderately differentiated SCC

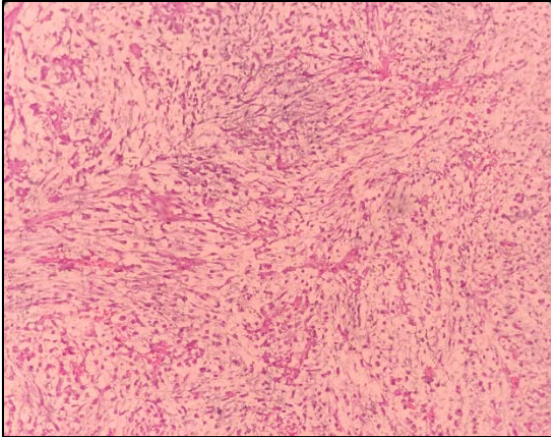


Figure 2. Microscopy showing sarcomatoid component.

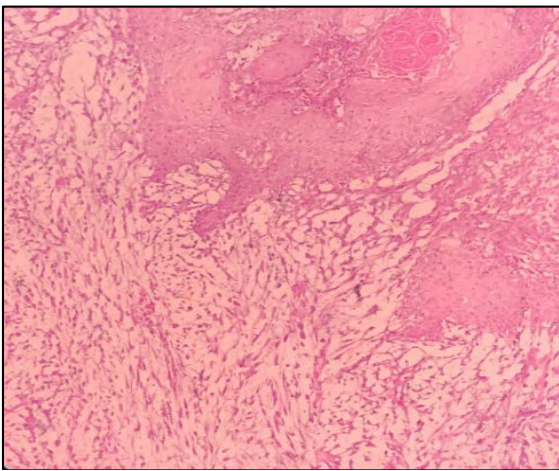


Figure 3. Microscopy showing transition from islands of squamous cells to spindle cells.

Discussion

Several variants of SCC are recognized by WHO in different sites. Keratinising SCC is the most common variant of SCC in vulva with other variants being non keratinising, warty, basaloid, verrucous, sarcomatoid.^{4,7} Sarcomatoid variant of SCC(SSCC) was first described in skin by Martin and Stewart in 1935.³

Sarcomatoid carcinoma comprises of a mixture of both epithelial and mesenchymal features. Different nomenclature has been given to this entity like spindle cell carcinoma, pseudosarcoma, metaplastic carcinoma, carcinosarcoma due to its biphasic features.⁷ Histological diagnosis of SCC becomes straightforward in presence of two separate components with typical squamous features

located on the surface and spindle cell component located on deeper portion similar to our case.⁵ When both these features are not present, the differential diagnoses include sarcoma, amelanotic malignant melanoma, malignant mixed mullerian tumor (MMMT).³ However, the most challenging situation lies in distinguishing SSCC from MMMT. Carcinomatous component in MMMT is usually adenocarcinoma which is intermixed with sarcomatous component rather than easy segregation into superficial carcinomatous and deep sarcomatous areas in SSCC.^{4,7} Sometimes heterologous elements may be seen in SSCC which further pose diagnostic enigma.⁵ Immunohistochemistry is the diagnostic modality of choice in distinguishing epithelial from mesenchymal origin. However, a study done by Terada et al reported that the malignant spindle cells showed immunoreactivity for SMA and S100 in addition to CK.⁹

Vulvar SCC is known to arise from Human Papilloma Virus (HPV) dependent and HPV independent pathways. Persistent infection with high risk HPV genotypes (16,18) in young women develop into usual vulvar intraepithelial neoplasia (uVIN) and subsequently progresses to warty or basaloid SCC.^{3,6,10} In contrast, HPV independent route occurs in elderly in setting of lichen sclerosus and differentiated vulvar intraepithelial neoplasia (dVIN) and progresses to keratinizing SCC.^{1,11} Even though vulvar SCC may follow two different pathways, one third of patients have coexistence of lichen sclerosus, uVIN and dVIN.² This is in agreement to our case demonstrating both koilocytosis and features of lichen sclerosus, the former one attributing to warty type and latter possibly attributing to sarcomatoid features.

The histogenesis of vulvar SSCC is still debatable. It has been believed that vulvar SSCC arises from metaplastic process of carcinomatous component which is supported by embryological, ultrastructural, immunohistochemical, molecular parameters with concept of epithelial to mesenchymal

transition accounting for sarcomatoid change.^{3,5} On contrary Choi et al mentioned that the change in tumor cell phenotype probably reflects change in differentiation itself than metaplasia.⁷

The prognosis varies from case to case depending upon many factors like inguinal node involvement, size, depth, stage, margin status and perineural invasion.^{3,4,5,6} Thickness of > 6 mm is associated with increased risk of lymph node involvement and 15% chance of distant metastasis.⁸ Heap et al has suggested that removal of at least 15 mm disease free tissue is associated with no local recurrence.² Due to rare occurrence of this tumor, no specific treatment modality have been formulated.

Conclusion

Vulvar SCC is a rare and aggressive tumor with poor outcome. Hence, it demands the collection and study of tumors of similar type for early diagnosis and to identify the best treatment approach.

Author Contribution

Concept, design, planning: SM, AS, BS, RB; Literature review: SM, AS; Data collection: SM; Data analysis: Not applicable; Draft manuscript: SM; Revision of draft: SM, AS, BS, RB. Final manuscript: SM, AS, BS, RB; Accountability of the work: SM, AS, BS, RB.

Reference

1. Wohlmuth C, Wohlmuth-Wieser I. Vulvar malignancies: an interdisciplinary perspective. *J Dtsch Dermatol Ges.* 2019;17(12):1257-76. | [DOI](#) | [PubMed](#) | [Google Scholar](#) | [Full Text](#) | [Weblink](#) |
2. Yap J, O'Neill D, Nagenthiran S, Dawson CW, Luesley DM. Current insights into the etiology, pathobiology, and management of local disease recurrence in squamous cell carcinoma of the vulva. *BJOG.* 2017;124(6):946-54. | [DOI](#) | [PubMed](#) | [Google Scholar](#) | [Weblink](#) |
3. Petrillo M, Corrado G, Carbone A, Macchia G, Ferrandina G. Vulvar squamous cell carcinoma with sarcoma-like stroma: a case report and review of the literature. *Diagn Pathol.* 2011;6:95. | [DOI](#) | [PubMed](#) | [Google Scholar](#) | [Weblink](#) |
4. Taner C, Şenyuva İ, Üstünay E, Keçeli S, Ayaz D. Skin metastasis of sarcomatoid squamous cell carcinoma in vulva a case report. *Gynecol Obstet Reprod Med.* 2009;15(2):119-22. | [Google Scholar](#) | [Full Text](#) | [Weblink](#) |
5. Bigby SM, Eva LJ, Jones RW. Spindle cell carcinoma of the vulva: a series of 4 cases and review of the literature. *Int J Gynecol Pathol.* 2014;33(2):203-12. | [DOI](#) | [PubMed](#) | [Weblink](#) |
6. Erman-Vlahovic M, Vlahovic J, Mrcela M, Hrgovic Z. Coexistence of condylomata acuminata with warty squamous cell carcinoma and squamous cell carcinoma. *Med Arch.* 2017;71(1):72-5. | [DOI](#) | [PubMed](#) | [Google Scholar](#) | [Weblink](#) |
7. Choi DS, Lee JW, Lee SJ, Choi CH, Kim TJ, Lee JH, et al. Squamous cell carcinoma with sarcomatoid features of the vulva: a case report and review of literature. *Gynecol Oncol.* 2006;103(1):363-7. | [DOI](#) | [PubMed](#) | [Google Scholar](#) |
8. Cozma CN, Raducu L, Avino A, Scaunasu RV, Bratu O, Marcu D, et al. A rare case of vulvar squamous cell carcinoma; case presentation. *J Clin Invest Surg.* 2018;3(1):32-6. | [DOI](#) | [Google Scholar](#) | [Weblink](#) |
9. Terada T. Sarcomatoid squamous cell carcinoma of the vulva expressing smooth muscle actin and S100 protein. *Arch Gynecol Obstet.* 2011;283(5):1103-6. | [DOI](#) | [PubMed](#) | [Google Scholar](#) |
10. McAlpine JN, Leung SC, Cheng A, Miller D, Talhouk A, Gilks CB, et al. Human papillomavirus (HPV)-independent vulvar squamous cell carcinoma has a worse prognosis than HPV-associated disease: a retrospective cohort study. *Histopathology.* 2017;71(2):238-46. | [DOI](#) | [PubMed](#) | [Google Scholar](#) |
11. Yang M, Wen W, Chang J. Vulvar lichen sclerosis: a single-center retrospective study in China. *J Dermatol.* 2018;45(9):1101-4. | [DOI](#) | [PubMed](#) | [Google Scholar](#) |