



ISSN: 2091-2749 (Print)
2091-2757 (Online)

Correspondence

Dr. Surendra Prasad Bhatta
Resident, Dept. of Obstetrics
and Gynaecology, Patan
Academy of Health Sciences,
Lalitpur, Kathmandu, Nepal
Email:
res.surendraprasadbhatta@pa
hs.edu.np

Peer Reviewers

Prof. Dr. Reetu Baral
Nobel Medical College

Assc. Prof. Dr. Rupesh Mukhiya
KIST Medical College

Submitted

23 Sep 2020

Accepted

20 Nov 2020

How to cite this article

Surendra Prasad Bhatta, Sarada
Duwal Shrestha. Papillary
thyroid carcinoma arising
within a mature cystic
teratoma of ovary: a rare case
report. Journal of Patan
Academy of Health Sciences.
2020Dec;7(3):80-83.

DOI:

<https://doi.org/10.3126/jpahs.v7i3.33831>

Papillary thyroid carcinoma arising within a mature cystic teratoma of ovary: a rare case report

Surendra Prasad Bhatta¹  , Sarada Duwal Shrestha²

¹MS Resident, ²Assoc. Prof., Dept. of Obstetrics and Gynaecology, Patan Academy of Health Sciences, Lalitpur, Kathmandu, Nepal

Abstract

Mature cystic teratoma is the most common ovarian germ cell tumor with a rare malignant conversion. We report a case of 36 years lady, with an incidental post-operative finding of papillary carcinoma of the thyroid in histopathology of the left ovarian dermoid cyst. Postoperatively she was evaluated for the presence of primary thyroid tumor with thyroid ultrasonography, thyroid function test, and anti-thyroglobulin antibody which revealed normal thyroid gland with euthyroid status and negative anti-thyroglobulin antibody, which had ruled out primary thyroid tumor. There are limited case reports on papillary thyroid carcinoma in a mature cystic teratoma in absence of a struma ovary and specific recommendations on the plan of its management are not available. This study aims to report a rare case of papillary thyroid carcinoma arising in a mature cystic teratoma of the ovary in absence of a struma ovary.

Keywords: mature ovarian teratoma, ovarian cyst, papillary thyroid carcinoma, struma ovary

Introduction

Mature cystic teratoma is the most common ovarian germ cell tumor accounting for 10%–20% of ovarian tumors.¹ Malignant transformation is unusual, with an estimated risk of 0.17 to 2%. Squamous cell carcinoma is the most common (80%) form of malignant transformation, less common malignancies include thyroid carcinomas, sarcomas, adenocarcinomas, malignant melanomas, basal cell carcinomas, and carcinoid tumors.¹ Incidence of thyroid carcinomas in ovarian teratoma is 0.1 - 0.2% among the most common is papillary carcinoma (70%).³

Although a favorable prognosis is anticipated of papillary thyroid carcinoma arising in mature cystic teratoma, the information about its prognosis is limited.² The exact incidence of malignancy in mature cystic teratoma is difficult to evaluate, because of its uncommon nature.^{1,3}

We report a rare case of papillary thyroid carcinoma arising in a mature cystic teratoma of the ovary.

Case Report

A 36-years lady of para-2 living-2 (P2L2) presented with pain in the left lower abdomen. On examination, the abdomen was soft and non-tender, with no mass palpable per abdomen. Pelvic examination revealed a soft, cystic mobile non-tender mass, around 6×6 cm in size with a smooth surface, likely from left adnexa. The bimanual examination also revealed the groove between the mass and uterus. The uterus was of normal size.

Ultrasonography of abdomen and pelvis revealed a left adnexal complex cystic lesion with echogenic solid components measuring 66 mm × 56 mm x 53 mm in size suggestive of dermoid cyst of the left ovary. The right ovary

was normal. There was no free fluid in the abdomen.

Preoperatively, tumor markers (CA125, CEA, LDH, BHCG, and AFP) were normal. Laparoscopic left salpingo-oophorectomy and right tubal ligation were done. During laparoscopy, a left ovarian cyst of 6x6x5 cm was noted with a smooth surface, intact capsule suggestive of FIGO T1a surgical stage ovarian tumor. There were no ascites, peritoneal implants, and the surface of the liver was smooth. Grossly right ovary was normal in appearance.

Cut section of the specimen revealed a left ovarian cyst, a wall thickness of 0.3-0.8 cm, containing hair and sebaceous material suggestive of cystic teratoma. Histopathology revealed the focus of thyroid tissue in the ovarian cyst. Thyroid tissue measured 7 mm in maximum dimension. Microscopically ovarian capsule was intact.

Thus, the final clinical diagnosis was revised as 'papillary thyroid carcinoma arising from mature cystic teratoma of left ovary'.

Postoperatively thyroid ultrasonography revealed a normal thyroid gland. Thyroglobulin was normal and antithyroglobulin antibody (anti-TgAb) was not detected in serum.

Because of normal thyroid status, normal serum thyroglobulin, and absence of anti-thyroglobulin antibody (anti-TgAb), thyroidectomy was not performed. The patient is on regular follow-up.

Discussion

We found incidental papillary thyroid carcinoma within a mature cystic ovarian teratoma (FIGO T1a surgical stage) after left salpingo-oophorectomy for the left ovarian cyst. Postoperative recovery was good.

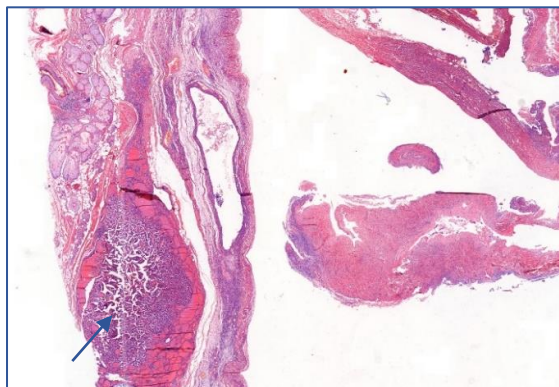


Figure 1. Immature cystic teratoma with a focal area of papillary carcinoma.

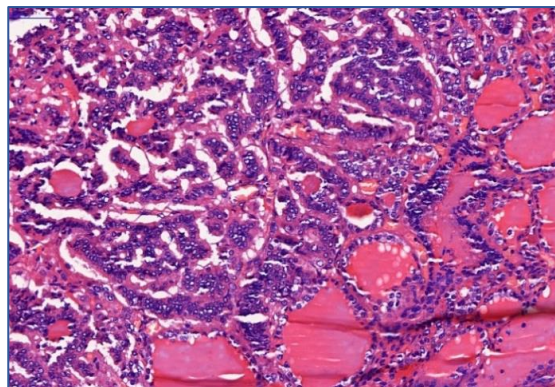


Figure 2. Magnified view- thyroid follicles and papillary carcinoma of thyroid in adjacent region

Teratoma is germ cell tumors composed of cell types derived from one or more of the three germ layers. These tumors are mostly benign which may also present as well-differentiated (mature) or malignant (immature) lesions. Mature cystic teratoma of the ovary is almost always benign with rare malignant transformation in 0.1-2% of cases majority being squamous cell carcinomas.¹ Monodermal teratoma are highly specialized ones containing a well-differentiated cluster of tissues. Struma ovary is termed when thyroid tissue is the predominant element (>50%) which is not in our case.⁵ In struma ovary 5-37% are complicated by thyroid carcinomas.²

In the case of incidentally found teratoma with thyroid tissue, a further diagnostic workup is needed.⁶ In our case, we had performed thyroid ultrasonography which showed normal thyroid gland, thyroid function test revealed euthyroid status and anti-thyroglobulin antibody was negative and thyroglobulin level was not elevated to suggest a distant metastasis from thyroid.^{9,10}

Pelvic surgery is sufficient for papillary thyroid carcinoma arising in a dermoid cyst of the ovary it is confined to the ovary and prophylactic thyroidectomy is not recommended in such cases^{6,7} In our case laparoscopic left salpingo-oophorectomy was done for left ovarian cyst.

Preoperative detection of thyroglobulin may help predict the tumor burden and lymph node metastasis of patients, also it has a

a significant role in the management and follow-up of thyroid cancer. In a review of 39 cases, follow up with thyroglobulin levels for at least 10 years is needed to monitor for recurrence or metastasis of Struma ovary, both benign and malignant.^{8,9}

In our case, papillary thyroid carcinoma was focal without capsular invasion. Our multidisciplinary team concluded oophorectomy was sufficient. This was also accepted by the patient and she was kept on follow-up.

Acknowledgement

Special thanks and credit to the department of pathology PAHS for providing pictures.

Conflict of Interest

None

Funding

None

Author Contribution

Concept, design, planning- SDS, SPB. Literature review- SPB. Draft manuscript SPB, SDS. Revision of draft SPB, SDS. Final manuscript: SPB, SDS. Accountability of the work SPB, SDS.

Reference

1. Rim SY, Kim SM, Choi HS. Malignant transformation of ovarian mature cystic teratoma. *Int J Gynecol Cancer*. 2006;16(1):140-4. | [DOI](#) | [PubMed](#) | [Google Scholar](#) | [Weblink](#) |
2. Pineyro MM, Pereda J, Schou P, de Los Santos K, de la Peña S, Caserta B, Pisabarro R. Papillary thyroid microcarcinoma arising within a mature ovarian teratoma: case report and review of the literature. *Clin Med Insights Endocrinol Diabetes*. 2017;10. | [DOI](#) | [PubMed](#) | [Google Scholar](#) | [Full Text](#) | [Weblink](#) |
3. Salman WD, Singh M, Twaij Z. A case of papillary thyroid carcinoma in struma ovarii and review of the literature. *Patholog Res Int*. 2010;2010:352476. | [DOI](#) | [PubMed](#) | [Google Scholar](#) | [Full Text](#) |
4. Cymbaluk-Ploska A, Chudecka-Głaz A, Chosia M, Ashuryk O, Menkiszak J. Conservative treatment of a young patient with thyroid carcinoma in adult ovarian teratoma – case report. *Gynecol Endocrinol*. 2014;30(3):187-91. | [DOI](#) | [PubMed](#) | [Google Scholar](#) | [Weblink](#) |
5. Park SB, Kim JK, Kim KR, Cho KS. Imaging findings of complications and unusual manifestations of ovarian teratomas. *Radiographics*. 2008;28(4):969-83. | [DOI](#) | [PubMed](#) | [Google Scholar](#) | [Full Text](#) | [Weblink](#) |
6. Brusca N, Del Duca SC, Salvatori R, D'Agostini A, Cannas P, Santaguida MG, et al. A case report of thyroid carcinoma confined to ovary and concurrently occult in the thyroid: is conservative treatment always advised? *Int J Endocrinol Metab*. 2015;13(1):e18220. | [DOI](#) | [PubMed](#) | [Google Scholar](#) | [Weblink](#) |
7. Dane C, Ekmez M, Karaca A, Ak A, Dane B. Follicular variant of papillary thyroid carcinoma arising from a dermoid cyst: a rare malignancy in young women and review of the literature. *Taiwan J Obstet Gynecol*. 2012;51(3):421-5. | [DOI](#) | [PubMed](#) | [Google Scholar](#) | [Full Text](#) | [Weblink](#) |
8. Makani S, Kim W, Gaba AR. Struma Ovarii with a focus of papillary thyroid cancer: a case report and review of the literature. *Gynecol Oncol*. 2004;94(3):835-9. | [DOI](#) | [PubMed](#) | [Google Scholar](#) | [Weblink](#) |
9. Wang W, Chang J, Jia B, Liu J. The blood biomarkers of thyroid cancer. *Cancer Manag Res*. 2020;12:5431-8. | [DOI](#) | [PubMed](#) | [Google Scholar](#) |
10. Qin J, Yu Z, Guan H, Shi L, Liu Y, Zhao N, Shan Z, Han C, Li Y, Teng W. High thyroglobulin antibody levels increase the risk of differentiated thyroid carcinoma. *Dis Markers*. 2015;2015:648670. | [DOI](#) | [PubMed](#) | [Google Scholar](#) |