



ISSN: 2091-2749 (Print)  
2091-2757 (Online)

#### Correspondence

Dr. Brihaspati Sigdel  
Dept. of Otolaryngology &  
Head and Neck Surgery  
Gandaki Medical College,  
Pokhara, Kaski, Nepal  
Email:  
brihaspatisigdel2020@gmail.com

#### Peer Reviewers

Prof. Dr. Ajit Nepal  
School of Medicine, Patan  
Academy of Health Sciences

Assoc. Prof. Shital Bhandary  
School of Public Health Patan  
Academy of Health Sciences

#### Submitted

16 Oct 2020

#### Accepted

8 Nov 2020

#### How to cite this article

Brihaspati Sigdel, Bhima  
Neupane, Tulika Dubey, Rajesh  
Maharjan, Kusheswar Sah.  
Microscope-assisted  
thyroidectomy. Journal of  
Patan Academy of Health  
Sciences. 2020Dec;7(3):73-79.

#### DOI:

<https://doi.org/10.3126/jpahs.v7i3.33830>

## Safety and efficacy of microscope-assisted thyroidectomy

Brihaspati Sigdel<sup>1</sup>  , Bhima Neupane<sup>2</sup> , Tulika Dubey<sup>3</sup> , Rajesh Maharjan<sup>4</sup>   
 , Kusheswar Sah<sup>4</sup> 

<sup>1</sup>Assoc. Prof., <sup>3</sup>Lecturer, <sup>4</sup>PG Resident, Dept. of Otolaryngology & Head and Neck Surgery, Gandaki Medical College, Pokhara, Nepal; <sup>2</sup>Lecturer, Dept. of Anatomy, Manipal College of Medical Sciences, Pokhara, Nepal

### Abstract

**Introduction:** Due to closely related structures like recurrent laryngeal nerve and parathyroid gland, thyroid surgery becomes challenging. Microscope assisted surgery has better visualization for dissection, and decreases the risk of injury to the nerve, parathyroid gland, and its vascular pedicle. Hence it decreases the operative complications.

**Method:** This is a retrospective study of microscope-assisted thyroidectomy at Gandaki Medical College Teaching Hospital, Nepal from January 2017 to December 2019. Ethical approval was obtained from Institutional review committee. Types of surgery, postoperative hypocalcemia and recurrent laryngeal nerve function were analyzed descriptively.

**Result:** Out of total 48 microscope assisted thyroidectomy, 41 were female, 42(87.5%) benign pathology, 6(12.5%) malignant. Hemithyroidectomy was done in 40(83.4%), total thyroidectomy 4 (8.2%), total thyroidectomy with neck dissection 3(6.3%), and completion thyroidectomy with neck dissection in 1(2.1%). Among total thyroidectomies, transient hypocalcemia occurred in 2(4.2%) and temporary recurrent laryngeal nerve palsy in 1(2.1%). No complication occurred in hemithyroidectomies.

**Conclusion:** Microscope-assisted thyroidectomy is a safe procedure which leads to reduced complication of hypocalcemia and recurrent nerve palsy.

**Keywords:** hypocalcemia, microscopic assisted thyroidectomy, thyroid nodule, parathyroid gland, recurrent laryngeal nerve

## Introduction

Thyroid surgery is a commonly performed procedure for thyroid nodules. Due to closely related structures like recurrent laryngeal nerve (RLN) & parathyroid gland, thyroid surgery becomes challenging.<sup>1-3</sup> The Swiss surgeon, Kocher has been described as the world leader in thyroid surgery at the end of the 19th century and his advances played a major role in decreasing the mortality rate associated with thyroid surgery.<sup>4</sup> In 1975 Attie and Khafi described a fine dissection technique using magnification during thyroidectomy.<sup>5</sup>

The use of a surgical microscope during thyroidectomy provides better illumination and magnification which allows precision in dissection and hemostasis.<sup>6</sup> Better visualization, meticulous dissection, and proper hemostasis decrease the risk of injury to the recurrent laryngeal nerve (RLN), the parathyroid gland, and its vascular pedicle, leading to a decrease in complications like recurrent laryngeal nerve palsy and hypocalcemia.<sup>2</sup>

This study aims to discuss the safety and efficacy of microscope-assisted thyroidectomy which has a reduced complication and morbidity like dysphonia and permanent hypocalcemia.

## Method

This is a retrospective study on patients who had undergone microscope-assisted thyroidectomy at Gandaki Medical College Teaching Hospital, a tertiary care hospital of Western Nepal, from January 2017 to December 2019. Ethical approval for the study was obtained from the Institutional Review Board of the hospital (Approval No: 062/2077/2078). Patients who underwent microscope-assisted thyroidectomy using Zeiss OPMI or Leica F 20 M525 surgical microscope, for benign or malignant thyroid nodule (based on thyroid function test, ultrasonography and fine needle aspiration cytology- FNAC) and a follow-up of at least six months were included in the study. Other modalities of thyroidectomies, previous thyroid surgery, or

pre-operative laryngeal nerve paralysis were excluded.

Surgery was performed under general anesthesia. The microscope was used after separating strap muscles until the delivery of the thyroid gland. Microscope was magnified 4 times to mobilize thyroid lobe and visualize all the three critical structures- recurrent laryngeal nerve, parathyroid glands (along with its blood supply), and external branch of superior laryngeal nerve.

Patient's demographics, diagnosis, type of surgery, complications (recurrent laryngeal nerve palsy, and hypocalcemia) were extracted from hospital records. Serum calcium level and video laryngoscopy reports from the first postoperative day, the first week, the first month, 3 m, and 6 m were also collected for analysis.

Postoperative serum calcium level below 8 mg/dl within 24 hours was categorized as temporary hypocalcemia. Persistent hypocalcemia was defined as that which remains, or still required calcium supplementation for 6 months after the surgery. Postoperatively, RLN function was assessed by fiber-optic laryngoscopy at first post post-op day, one week, 1 and 3 mo. The patients were followed-up for at least 6 mo to assess the RNL paralysis and hypocalcemia

Data were analyzed descriptively for frequency and percentage using Microsoft Excel.

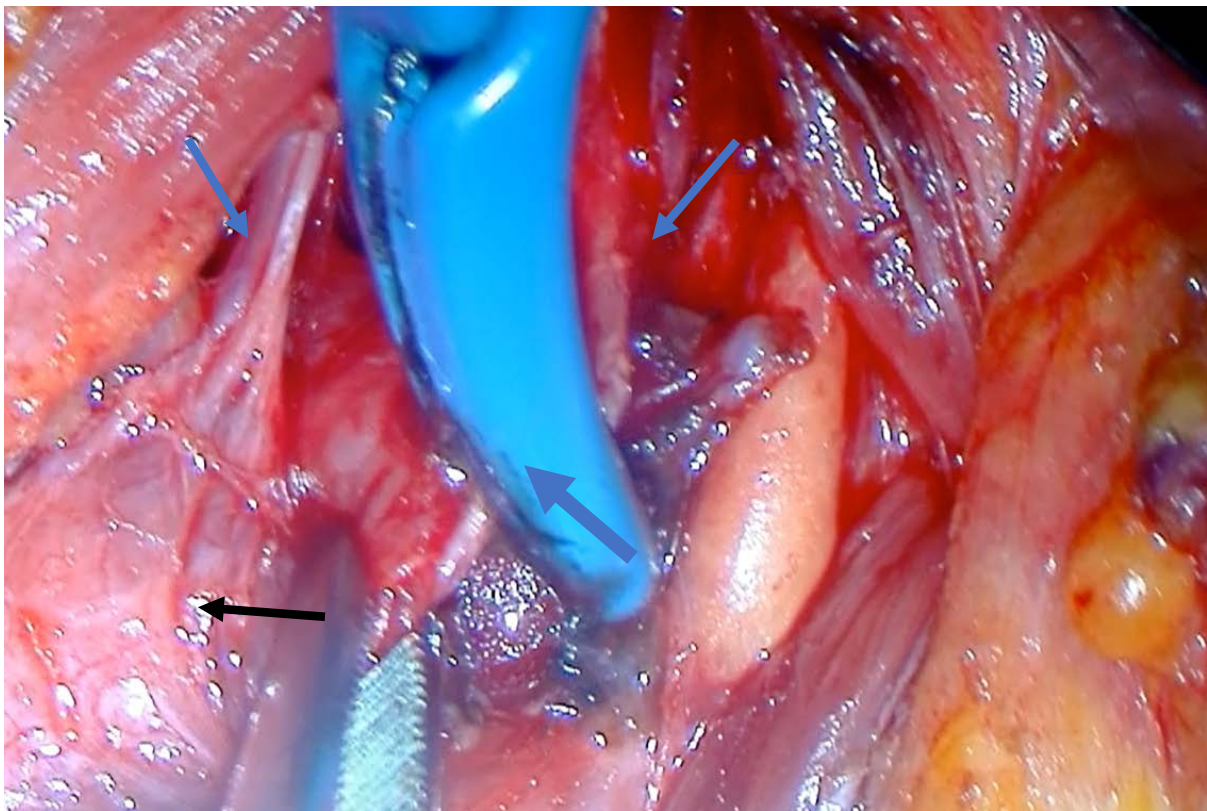
## Result

Out of total 48 patients, 41 were female, 32(66.7%) colloid goiter and 1(2.1%) follicular adenoma. Hemithyroidectomy was performed in 40(83.4%). Out of total thyroidectomies (N=8) neck dissection was performed in four, Table 1. Among total thyroidectomies, transient hypocalcemia occurred in 2(25%) and temporary recurrent laryngeal nerve (RLN) palsy in 1(12.5%). None of 40 hemithyroidectomies developed hypocalcemia or nerve palsy.

**Table 1. Demography of patients undergoing microscope-assisted thyroidectomy, N=48**

Characteristics		
Age	Range	17-62
	Mean±Standard Deviation	40.38±12.85
Sex	Female	41
	Male	7
	Female: Male	5.8:1
Diagnosis	Colloid goiter	32(66.7%)
	Multinodular goiter	10(20.8%)
	Papillary carcinoma	5(10.4%)
	Follicular adenoma	1(2.1%)
Hemi-thyroidectomy (40)	Right hemithyroidectomy	25(52.1%)
	Left hemithyroidectomy	15(31.3%)
Total-thyroidectomy (8)	Total thyroidectomy	4(8.2%)
	Total thyroidectomy + CCND*	2(4.2%)
	Total thyroidectomy + CCND + LND**	1(2.1%)
	Completion thyroidectomy + CCND + LND	1(2.1%)

\*CCND - Comprehensive Central Neck Dissection, \*\*LND - Lateral Neck Dissection



**Figure 1. Right individual harmonic superior vessel ligation (blue arrow- Individual vessels in superior thyroid pedicle, thick blue arrow and Harmonic vessel sealer; black arrow- Right thyroid lobe)**

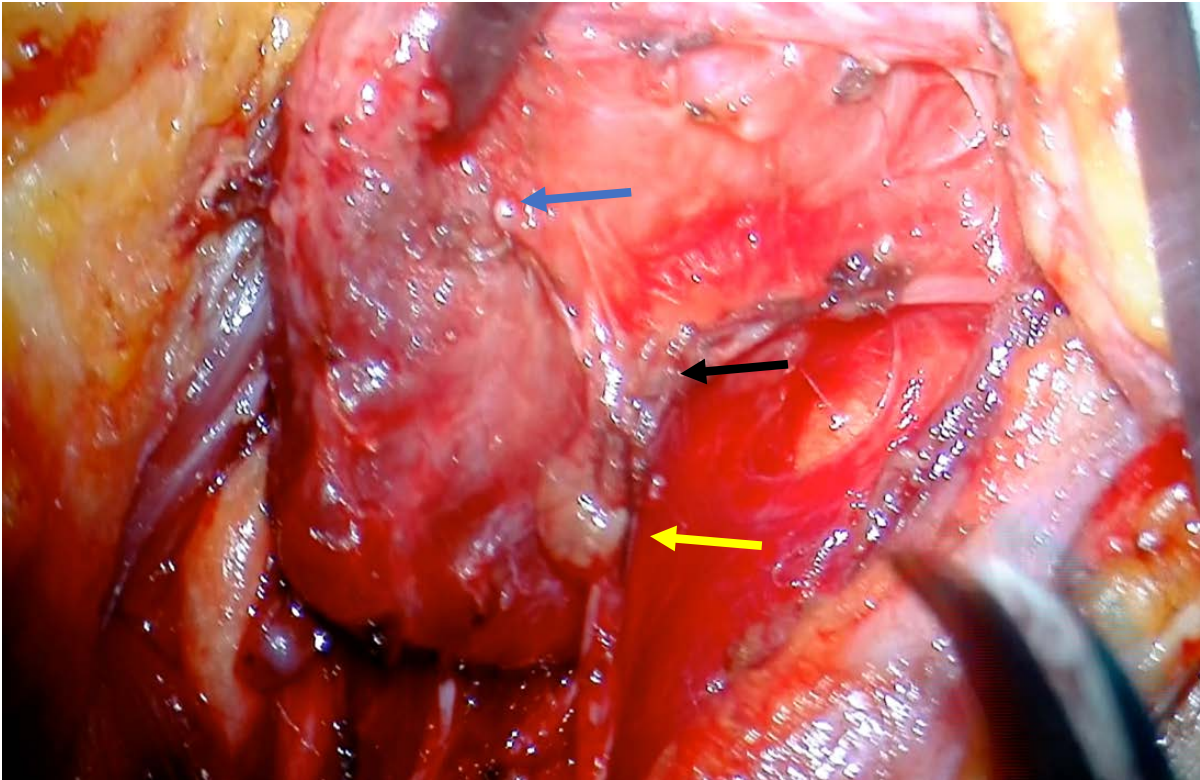


Figure 2. Parathyroid gland with intact blood supply inferior thyroid artery (blue arrow- Thyroid gland, black arrow- Inferior thyroid artery, yellow arrow- Parathyroid gland)

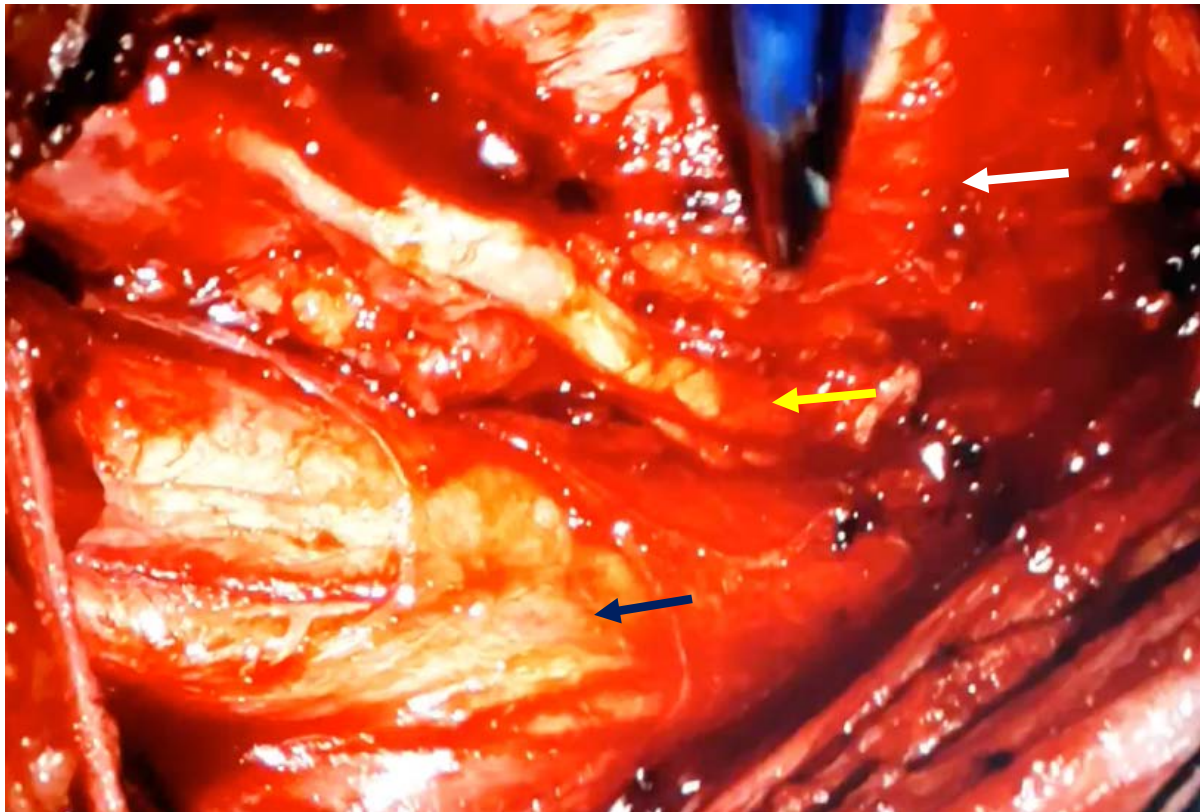


Figure 3. Microscopic view of right recurrent laryngeal nerve (white arrow- Trachea, yellow arrow- Right recurrent laryngeal nerve, black arrow- Common carotid artery)

## Discussion

We found transient hypocalcemia in 25% (2 out of 8) and temporary RLN palsy in 12.5% (1 out of 8) total thyroidectomies but none of the patients had permanent RLN palsy nor permanent hypocalcemia. Also, none of the hemi-thyroidectomies had any complications of hypocalcemia or nerve palsy. When we consider the overall complication of thyroidectomies (N= 48), including hemi- (40), total without neck dissection (4) and total with neck dissection (4), the overall transient hypocalcemia occurred in 4.2% (2 out of 48) and transient RLN in 2% (1 out of 48).

Thyroidectomy is done for diseases of the thyroid gland including thyroid malignancy, toxic thyroid nodule, multinodular goiter, grave's disease, etc.<sup>7</sup> In thyroid surgery there has been a tremendous evolution from the times of Kocher in 1878 to the early years of 1900 when Frank Howard Lahey FH.<sup>8</sup> In 1938, Lahey first used Bereny binocular loupes magnification for thyroid surgery. With this, he was able to magnify the nerve by two and half times.<sup>9</sup> The complications of thyroid surgery are attributable to the extent of thyroidectomy, experience of the surgeon, and the fineness of dissection in critical areas.<sup>10</sup>

It is important to preserve functioning RLN intact.<sup>11</sup> Parathyroid gland with intact blood supply is crucial to prevent hypocalcemia.<sup>12</sup> In our present study, transient hypocalcemia and RLN palsy were significantly higher in total thyroidectomy as compared to hemi-thyroidectomy. A study shows that permanent RLN palsy following microscope-assisted thyroidectomy for benign and malignant thyroid tumors to be 0.6% and 3.5% respectively.<sup>13</sup> Another study from Germany has reported the incidence of temporary vocal cord palsy following microscope-assisted thyroidectomy as 1 to 8.6%.<sup>14</sup>

The incidence of RLN palsy and hypocalcemia following conventional total thyroidectomy has been reported to be between 5-11% and 20-30% respectively.<sup>15</sup> Another study has reported RLN palsy in 31.9% of the total thyroidectomy cases without the use of

microscope, among which 20.5%.<sup>16</sup> A different study supplements the findings with reported 5.1% temporary RLN Palsy with conventional thyroidectomy.<sup>17</sup> A study conducted in Eastern Nepal has reported a transient hypocalcemia in 6.67% and temporary RLN palsy in 6.67% of their cases operated without magnification.<sup>18</sup> This rate was higher than the findings in our present study. A different study reported the rates of transient RLN palsy at 4.8% and 6.8% with loupe magnification versus without.<sup>19</sup>

In a study of microscope-assisted thyroidectomy transient hypocalcemia occurred in 10.36%.<sup>20</sup> The same study showed an inadvertent parathyroid gland removal in 7.8% without use of a loupe and 3.8% with use of loupe magnification.<sup>20</sup> The use of a microscope in thyroidectomy gives an excellent visualization and makes dissection precise. This prevents inadvertent injury to the RLN and the parathyroid gland.

The use of microscope in our setting seemed to improve the surgeon to maintain neutral cervical position, and upright posture of the patient, and facilitate in teaching learning activities for the residents. In our experience the use of microscope is easy to learn. The limitation of our study was small sample size at a single center, and thus requires larger sample size to generalize our findings.

## Conclusion

Microscope-assisted thyroidectomy is a safe procedure with less complications of transient hypocalcemia (2 out of 8) and transient recurrent laryngeal nerve palsy (1 out of 8) total thyroidectomies. There was zero incidence hypocalcemia or nerve palsy in forty hemithyroidectomies.

## Conflict of Interest

None

## Funding

None

### Author Contribution

Concept, design, planning- BS, RM, KS, BN, TD. Literature review– BS. Data collection, analysis- BS, RM. Drafting manuscript - BS, RM, KS. Revision of draft - BS, BN, TD. All authors read and approved final manuscript. BS-guarantor of the work.

### Reference

- Latif S, Altaf H, Waseem S, Farooqui F, Altaf OS, Amir M. A retrospective study of complications of total thyroidectomy; is it a safe approach for benign thyroid conditions. *J Pak Med Assoc.* 2019;69(10):1470-3. | [DOI](#) | [PubMed](#) | [Google Scholar](#) | [Full Text](#) | [Weblink](#) |
- Chahardahmasumi E, Salehidoost R, Amini M, Aminorroaya A, Rezvanian H, Kachooei A, et al. Assessment of the early and late complication after thyroidectomy. *Adv Biomed Res.* 2019;8:14. | [DOI](#) | [PubMed](#) | [Google Scholar](#) | [Full Text](#) | [Weblink](#) |
- Bhattacharyya N, Fried MP. Assessment of the morbidity and complications of total thyroidectomy. *Arch Otolaryngol Head Neck Surg.* 2002;128(4):389-92. | [DOI](#) | [PubMed](#) | [Google Scholar](#) | [Weblink](#) |
- Harding J, Sebag F, Sierra M, Palazzo FF, Henry JF. Thyroid surgery: postoperative hematoma - prevention and treatment. *Langenbecks Arch Surg.* 2006;391(3):169-73. | [DOI](#) | [PubMed](#) | [Google Scholar](#) | [Weblink](#) |
- Seven H, Calis AB, Vural C, Turgut S. Microscopic thyroidectomy: a prospective controlled trial. *Eur Arch Otorhinolaryngol.* 2005;262(1):41-4. | [DOI](#) | [PubMed](#) | [Google Scholar](#) | [Weblink](#) |
- Kumar A, Tyagi AK, Varshney S, Malhotra M, Priya M. Microscopic thyroidectomy: a prudent option. *Indian J Otolaryngol Head Neck Surg.* 2019;71(2):212-7. | [DOI](#) | [PubMed](#) | [Google Scholar](#) | [Full Text](#) | [Weblink](#) |
- Williams SP, Wilkie MD, Tahery J. Microscope-assisted thyroidectomy: our experience in one hundred and twenty-one consecutive cases. *Clin Otolaryngol.* 2014;39(5):307-11. | [DOI](#) | [PubMed](#) | [Google Scholar](#) | [Weblink](#) |
- Lahey R. Routine dissection and demonstration of the recurrent laryngeal nerve in subtotal thyroidectomy. *Surg Gynecol Obstet.* 1938;66:775-7. | [Google Scholar](#) |
- Lahey FH, Hoover WB. Injuries to the recurrent laryngeal nerve in thyroid operations: their management and avoidance. *Ann Surg.* 1938;108(4):545-62. | [DOI](#) | [PubMed](#) | [Google Scholar](#) | [Full Text](#) | [Weblink](#) |
- Steurer M, Passler C, Denk DM, Schneider B, Niederle B, Bigenzahn W. Advantages of recurrent laryngeal nerve identification in thyroidectomy and parathyroidectomy and the importance of preoperative and postoperative laryngoscopic examination in more than 1000 nerves at risk. *Laryngoscope.* 2002;112(1):124-33. | [DOI](#) | [PubMed](#) | [Google Scholar](#) | [Weblink](#) |
- Schneider R, Randolph GW, Barczynski M, Dionigi G, Wu CW, Chiang FY, Machens A, Kamani D, Dralle H. Continuous intraoperative neural monitoring of the recurrent nerves in thyroid surgery: a quantum leap in technology. *Gland Surg.* 2016;5(6):607-16. | [DOI](#) | [PubMed](#) | [Google Scholar](#) | [Full Text](#) |
- Fortuny VJ, Belfontali V, Sadowski SM, Karenovics W, Guigard S, Triponez F. Parathyroid gland angiography with indocyanine green fluorescence to predict parathyroid function after thyroid surgery. *Br J Surg.* 2016;103(5):537-43. | [DOI](#) | [PubMed](#) | [Google Scholar](#) | [Full Text](#) |
- Nielsen TR, Andreassen UK, Brown CL, Balle VH, Thomsen J. Microsurgical technique in thyroid surgery — a 10-year experience. *J Laryngol Otol.* 1998;112(6):556-60. | [DOI](#) | [PubMed](#) | [Google Scholar](#) | [Weblink](#) |
- Sulica L, Cultrara A, Blitzer A. Vocal fold paralysis: causes, outcomes, and clinical aspects. In: Sulica L, Blitzer A, editors. *Vocal fold paralysis.* Berlin: Springer, 2020. | [DOI](#) | [Google Scholar](#) | [Weblink](#) |
- Christou N, Mathonnet M. Complications after total thyroidectomy. *J Visc Surg.* 2013;150(4):249-56. | [DOI](#) | [PubMed](#) | [Google Scholar](#) | [Weblink](#) |
- Gardner GM, Smith MM, Yaremchuk KL, Peterson EL. The cost of vocal fold paralysis after thyroidectomy. *Laryngoscope.* 2013;123(6):1455-63. | [DOI](#) | [PubMed](#) | [Google Scholar](#) | [Weblink](#) |
- Chiang FY, Wang LF, Huang YF, Lee KW, Kuo WR. Recurrent laryngeal nerve palsy after thyroidectomy with routine identification of the recurrent laryngeal nerve. *Surgery.* 2005;137(3):342-7. | [DOI](#) | [PubMed](#) | [Google Scholar](#) | [Weblink](#) |
- Panthi N, Chettri ST, Shah SP, Poudel D, Manandhar S, Acharya K. Complications of thyroid surgery & their risk factors: a prospective study at a tertiary care center of eastern Nepal. *J BP Koirala Inst Health Sci.* 2019;2(1):25-33. | [DOI](#) | [Google Scholar](#) | [Full Text](#) | [Weblink](#) |

19. Pata G, Casella C, Mittempergher F, Cirillo L, Salerni B. Loupe magnification reduces postoperative hypocalcemia after total thyroidectomy. *Am Surg.* 2010;76(12):1345-50. | [DOI](#) | [PubMed](#) | [Google Scholar](#) | [Weblink](#) |
20. D'Orazi V, Panunzi A, Di Lorenzo E, Ortensi AI, Cialini M, Anichini S, Ortensi A. Use of loupes magnification and microsurgical technique in thyroid surgery: ten years' experience in a single center. *G Chir.* 2016;37(3):101-7. | [DOI](#) | [PubMed](#) | [Google Scholar](#) | [Full Text](#) |