



ISSN: 2091-2749 (Print)  
2091-2757 (Online)

#### Correspondence

Pradeep Raj Regmi  
Dept. of Radiology and Imaging  
Hospital for Advanced  
Medicine and Surgery (HAMS)  
GPO Box 3832, Kathmandu,  
Nepal  
Email: pradeep.iom@gmail.com

#### Peer Reviewers

Asst. Prof. Dr. Ranjan  
Devbhondary, Academy of  
Health Sciences

Asst. Prof. Dr. Ashis Shrestha,  
Patan Academy of Health  
Sciences

#### Submitted

05 Jun 2021

#### Accepted

12 Sep 2021

#### How to cite this article

Pradeep Raj Regmi, Isha  
Amatya. Imaging of vein of  
Galen malformation in late  
trimester. Journal of Patan  
Academy of Health Sciences.  
2021Dec;8(3):117-121.

<https://doi.org/10.3126/jpahs.v8i3.31433>

## Imaging of vein of Galen malformation in late trimester

Pradeep Raj Regmi<sup>1</sup>  , Isha Amatya<sup>2</sup> 

<sup>1</sup>Pediatric / General Radiologist, Dept. of Radiology, Hospital for Advanced Medicine and Surgery (HAMS); <sup>2</sup>Research Officer, Nepal Health Research Council, Kathmandu, Nepal

### Abstract

Vein of Galen malformation is a rare congenital vascular malformation due to the maldevelopment of the embryonic precursor median vein of Markowski. It results in significant morbidity and mortality in a fetus and neonate. Fetal ultrasound plays an important role in prenatal screening of fetuses to rule out development anomalies. Fetal Magnetic Resonance Imaging (MRI) plays a dual role both in diagnosis and periodical follow-up with identification of prognostically important complications of vein of Galen malformation. The combination of fetal ultrasound and fetal MRI provides a definite diagnosis during pregnancy thereby providing an opportunity to plan the delivery of the fetus and subsequent postnatal treatment. We are presenting a case of a 34 y female presented at 35 w period of gestation to the ultrasound unit of our hospital.

**Keywords:** Fetal MRI, ultrasound, vein of Galen malformation

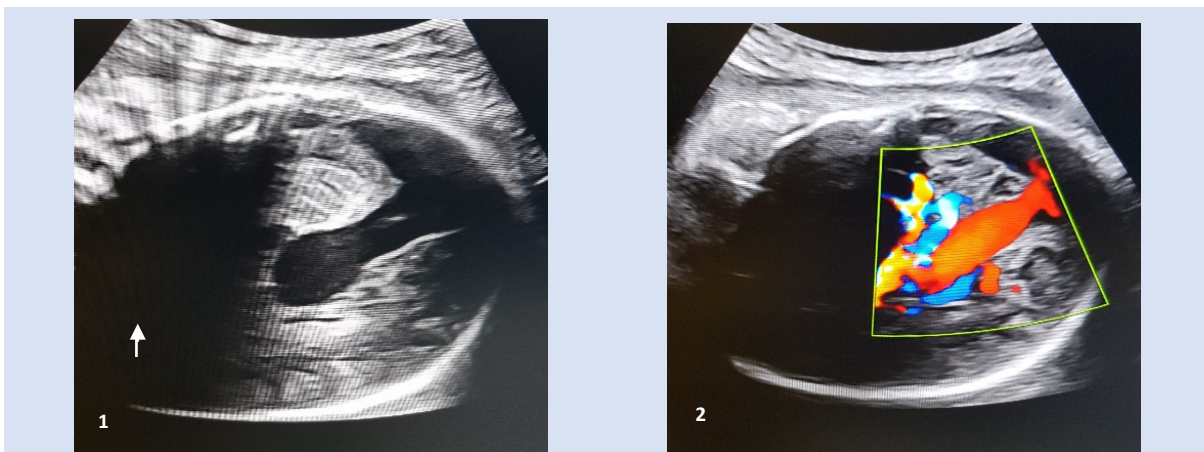
## Introduction

Vein of Galen malformation (VOGM) is a rare congenital vascular malformation that accounts for 1% of all arterio-venous malformations. They constitute approximately 30% of intracranial malformations in the pediatric population. The malformation is due to the presence of an arterio-venous fistula directed towards the median prosencephalic vein of Markowski. This vein undergoes regression in normal conditions during embryogenesis before the 11<sup>th</sup> week of gestation together with the development of the middle cerebral vein and vein of Galen.<sup>1-3</sup> This condition is mostly diagnosed in the late trimester of pregnancy due to the combined effect of fetal brain injury and cardiac failure.<sup>4</sup> This rare entity is not reported in our settings. Our experience with fetal ultrasound (US) and

Magnetic resonance imaging (MRI) of a case of VOGM in the third trimester is reported herein.

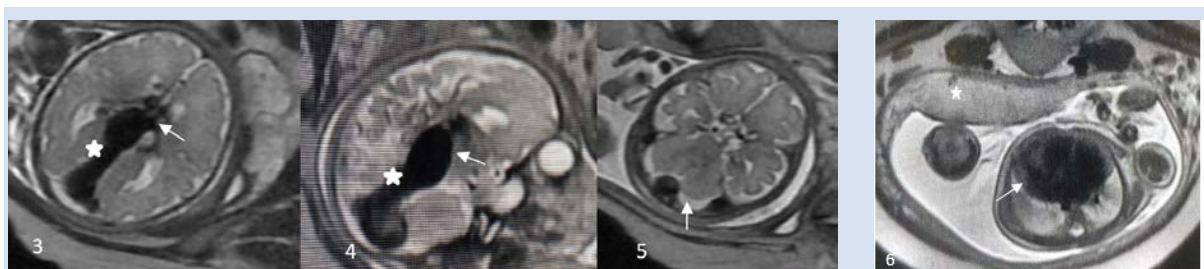
## Case Report

A 34 y G3P1 presented for a routine follow-up scan at 35 weeks of gestation. The mother denied any symptoms of abdominal pain and vaginal bleeding. The fetal movement was normally felt by the mother. The fetus was found to have a vein of Galen malformation which was unnoticed in the prior anomaly scan. No other anomalies were identified in the fetus except cardiomegaly. The patient denied any history of congenital anomalies in the previous child. Thus, fetal MRI was performed for further evaluation of the malformation and the status of brain parenchyma.



**Figure 1.** Ultrasonography shows a large tubular thin-walled anechoic lesion in the midline (The posterior acoustic shadowing in the anterior aspect of the brain (arrow) due to ossified skull as expected normally in the third trimester).

**Figure 2.** Similar finding on color Doppler study (Turbulent high flow is seen within the tubular lesion suggestive of a large abnormal vessel in midline suggesting vein of Galen malformation)



**Figure 3, 4.** MRI T2 axial/sagittal images showing enlarged median prosencephalic vein of Markowski in midline feeding by posterior choroidal artery (arrows), characteristic of vein of Galen aneurysmal malformation. Persistence of midline falcine sinus (asterisks)

**Figure 5.** MRI, posterior fossa structures especially the cerebellum (arrow) and vermis appear normal

**Figure 6.** MRI T2 axial image of the fetal chest shows cardiomegaly (arrow) and placenta (asterisk)

## Discussion

Jaeger and colleagues described the vein of Galen “aneurysms” in 1937, a misnomer according to the current understanding of this lesion.<sup>5</sup> True vein of Galen malformations is the arteriovenous fistula (AVFs) supplied by the feeder arteries that drain into the persistent vein of Markowski. The term was first postulated by the Polish anatomist Joseph Markowski.<sup>3</sup> The term “vein of Galen malformation” is a misnomer because the dilated vein seen in the location of the vein of Galen is the prosencephalic vein.<sup>5</sup> An arteriovenous (AV) shunt is between this vein and the arteries supplying the brain leads to high preload to the heart leading to heart failure.<sup>4</sup>

There are three classification systems for VOGM based on complexity, type of supplying arteries, location of the fistula, and degree of venous ectasia.<sup>6</sup>

- A. Litvak
  - Category A- Aneurysms of the great vein of Galen
  - Category B- Racemose conglomeration of blood vessels in the cerebral structures
  - Category C- Transitional types of midline AV shunts
- B. Lasjaunias
  - Type I – Choroidal type
  - Type II – Mural type
- C. Yasargil
  - Type I – Pure AVF between leptomeningeal arteries and feeders from P3, segments of posterior cerebral arteries and vein of Galen
  - Type II – Feeders from the thalamo-perforating vessels and P1 and P2 segments of the posterior cerebral arteries
  - Type III – Mixture of type I and II
  - Type IV – IV A - Aneurysmal dilation of the vein of Galen resulting from shunting from an adjacent thalamic AVM; IV B- Similar to type IV A with the AVM being mesencephalic instead of thalamic; IV C- Thalamomesencephalic

or mesodiencephalic plexiform malformation along with an adjacent and separate cisternal AVF to the vein of Galen.

Two different subtypes of vascular malformations can involve the vein of Galen, the vein of Galen aneurysmal malformation (VGAM), and the Vein of Galen aneurysmal dilatation (VGAD).<sup>4</sup> The VGAM is a persistent median prosencephalic vein of Markowski. For VGAM, one favored classification is choroidal and mural type. In the choroidal type, multiple feeders from the choroidal arteries and other deep midbrain arteries are present that converge on a fistula site at the anterior aspect of the median vein. However, in mural type, a fistula or fistulae in the wall of the median prosencephalic vein are seen. They typically have fewer feeding arteries, do not have a complex arterial maze, and are said to present with lesser degrees of heart failure.<sup>6</sup>

In VGADs, the vein of Galen is fully developed. The VGAD corresponds to an arteriovenous malformation centered in the subpial space. Shunts can be located in the cerebellum, brainstem, or in the deep supratentorial territories which subsequently drain into the dilated vein of Galen. Differentiation of VGAD and VGAM is important. Since VGAD can be symptomatic in childhood and can present with intracranial hemorrhage.<sup>6</sup> Diagnosis of VGAM was made in our case. The posterior choroidal arteries are the most common source of supply of the malformation as in our case shown in MRI, Figure 3. Anterior cerebral arteries are the second most frequent feeders. Middle cerebral and anterior choroidal arteries were found to be common feeders in neonates. Lenticulostriate arteries are uncommon.<sup>3</sup>

The malformation presents with features of cardiac failure and enlarged size of the head in neonates and infants which can be associated with palpable cranial bruits. The older child can present with headaches or recurrent seizures.<sup>8</sup> Ultrasonography (USG) is the first go-to modality for the evaluation of fetal anomalies in pregnancy.<sup>2</sup> Prenatal diagnosis is usually

made in the third trimester due to its natural history of progression. In addition to evaluation of brain parenchyma, color Doppler imaging can detect the vascular lesions in the brain of the fetus as in our case. However, due to its inadvertent limitations like the abnormal position of the head, maternal obesity, oligohydramnios, reverberation artifacts, or posterior shadowing of the ossified skull in the late trimester which can lead to inadequate evaluation.<sup>2</sup> In these scenarios, fetal brain MRI could play a vital role in fetal evaluation in addition to ultrasound.

The MRI is safe and radiation-free. It can confirm whether the fetal brain is developed adequately as well as the extent of brain injury. In our case, the development of the brain parenchyma appeared normal for gestational age. The presence of fetal cardiomegaly or fetal hydrops and injury to brain parenchyma indicates the poor outcome. There was cardiomegaly in our case, Figure 6. Hydrocephalus is the most common finding associated with a diagnosis of VGAM due to direct obstruction to the aqueduct or impaired absorption of CSF in arachnoid granulations due to venous hypertension which was absent in our case.<sup>6</sup> Melting brain syndrome is a term described in the literature to describe the most severe form in MRI in which the arterial supply of the brain seizes due to profound venous hypertension and brain parenchyma is progressively destroyed.<sup>5</sup>

Angiography is the gold standard for diagnosis leading to full characterization of the malformation, arterial feeders, and drainage thereby deciding the appropriate treatment approaches.<sup>8</sup> Treatment of choice involves transarterial embolization in the postnatal period and its efficacy depends largely on the size of malformations and developed complications.<sup>1</sup> However, in the case of multiple small feeders, transvenous embolization is preferred. Another technique that involves both the transarterial and transvenous approach also known as the kissing micro-catheter technique is also evolving.<sup>5,10,11</sup> In our case scenario, all the possible treatment modalities, and the

outcome was explained to the parents. Termination of pregnancy was decided by the parents. Normal vaginal delivery with “do not resuscitate” status was done after induction of labor.

The combination of fetal ultrasound and MRI provides a definite diagnosis during pregnancy thereby providing an opportunity to plan the delivery of the fetus and guide the subsequent postnatal treatment as well as counseling of the parents. A multidisciplinary approach is needed for the evaluation and treatment of this rare anomaly.

#### Acknowledgment

We would like to appreciate the time and help provided by the members of the Department of Gynaecology and Obstetrics, HAMS Hospital for providing the clinical information needed for the manuscript.

#### Author Contribution

Concept, design, planning: PRR, IA; Literature review: PRR; Data collection/analysis: Draft manuscript: PRR, IA; Revision of draft: IA, PRR; Final manuscript: PRR, IA; Accountability of the work: PRR.

#### Reference

1. Kośła K, Majos M, Polgaj M, Antosik-Biernacka A, Stefańczyk L, Majos A. Prenatal diagnosis of a vein of Galen aneurysmal malformation with MR imaging – report of two cases. *Pol J Radiol.* 2013 Nov 19;78(4):88–92. | [DOI](#) | [PubMed](#) | [Google Scholar](#) | [Full Text](#) | [Weblink](#) |
2. Li T, Zhang Y, Nie F, Peng M, Li Y-Z, Li P. Diagnosis of foetal vein of galen aneurysmal malformation by ultrasound combined with magnetic resonance imaging: a case series. *BMC Med Imaging.* 2020 Dec;20(1):63. | [DOI](#) | [PubMed](#) | [Google Scholar](#) | [Full Text](#) | [Weblink](#) |
3. Raybaud CA, Strother CM, Hald JK. Aneurysms of the vein of Galen: embryonic considerations and anatomical features relating to the pathogenesis of

- the malformation. *Neuroradiology*. 1989 Mar 1;31(2):109-28. | [DOI](#) | [PubMed](#) | [Google Scholar](#) | [Full Text](#) | [Weblink](#) |
4. Alvarez H, Monaco RG, Rodesch G, Sachet M, Krings T, Lasjaunias P. Vein of Galen aneurysmal malformations. *Neuroimaging clinics of North America*. 2007 May 1;17(2):189-206. | [DOI](#) | [PubMed](#) | [Google Scholar](#) | [Full Text](#) | [Weblink](#) |
  5. Mortazavi MM, Griessenauer CJ, Foreman P, Shahripour RB, Shoja MM, Rozzelle CJ, Tubbs RS, Fisher WS, Fukushima T. Vein of Galen aneurysmal malformations: critical analysis of the literature with proposal of a new classification system: a review. *Journal of neurosurgery: Pediatrics*. 2013 Sep 1;12(3):293-306. [DOI](#) | [PubMed](#) | [Google Scholar](#) | [Full Text](#) | [Weblink](#) |
  6. Puvabanditsin S, Mehta R, Palomares K, Gengel N, Da Silva CF, Roychowdhury S, Gupta G, Kashyap A, Sorrentino D. Vein of Galen malformation in a neonate: A case report and review of endovascular management. *World journal of clinical pediatrics*. 2017 Feb 8;6(1):103. | [DOI](#) | [PubMed](#) | [Google Scholar](#) | [Full Text](#) | [Weblink](#) |
  7. Wagner MW, Vaught AJ, Poretti A, Blakemore KJ, Huisman TA. Vein of Galen Aneurysmal Malformation: Prognostic Markers Depicted on Fetal MR I. *The neuroradiology journal*. 2015 Feb;28(1):71-5. | [DOI](#) | [PubMed](#) | [Google Scholar](#) | [Full Text](#) | [Weblink](#) |
  8. Berg DV, Pitcher R, Dumitriu D. Typical MRI Features of a Vein of Galen Aneurysmal Malformation. *Journal of the Belgian Society of Radiology*. 2020;104(1). | [DOI](#) | [PubMed](#) | [Google Scholar](#) | [Full Text](#) | [Weblink](#) |
  9. Madhuban A, van den Heuvel F, van Stuijvenberg M. Vein of Galen aneurysmal malformation in neonates presenting with congestive heart failure. *Child neurology open*. 2016 Mar 2;3:2329048X15624704. | [DOI](#) | [PubMed](#) | [Google Scholar](#) | [Full Text](#) | [Weblink](#) |
  10. Berenstein A, Fifi JT, Niimi Y, et al. Vein of Galen malformations in neonates: new management paradigms for improving outcomes. *Neurosurgery*. 2012;70(5):1207-1213;discussion 1213-1204. | [DOI](#) | [PubMed](#) | [Google Scholar](#) | [Full Text](#) | [Weblink](#) |
  11. Lasjaunias PL, Chng SM, Sachet M, Alvarez H, Rodesch G, Garcia-Monaco R. The management of vein of Galen aneurysmal malformations. *Neurosurgery*. 2006;59(5 suppl 3):s184-s194;discussion s183-s113. | [DOI](#) | [PubMed](#) | [Google Scholar](#) | [Full Text](#) | [Weblink](#) |