



ISSN: 2091-2749 (Print)
2091-2757 (Online)

Correspondence

Dr. Namita Sindan
Dept. of Gynecology and
Obstetrics, Paropakar
Maternity and Women's
Hospital, Kathmandu, Nepal
Email: namitasindan@163.com

Peer Reviewers

Prof. Dr. Jay N Shah
Patan Academy of Health
Sciences

Asst. Prof. Dr. Ashis Shrestha
Patan Academy of Health
Sciences

Submitted

16 Dec 2019

Accepted

20 Mar 2020




How to cite this article

Namita Sindan, Adheesh
Bhandari, Snigdha Rai, Devi
Gurung. Fetus papyraceus: a
rare case report. Journal of
Patan Academy of Health
Sciences. 2020Apr;7(1):113-
116.

DOI:

<https://doi.org/10.3126/jpahs.v7i1.28887>

Fetus papyraceus: a rare case report

Namita Sindan¹  ✉ Adheesh Bhandari² , Snigdha Rai¹ , Devi Gurung¹ 

¹Dept. of Gynecology and Obstetrics, Paropakar Maternity and Women's Hospital, Kathmandu, Nepal

²Formerly, Dept. of Thyroid & Breast Surgery, The First Affiliated Hospital of Wenzhou Medical University, Wenzhou, Zhejiang 325000, PR China

Abstract

Fetus papyraceus is a rare condition of a mummified and compressed fetus occurring in multiple gestations where one fetus dies in utero and is merged between the uterine wall and the membranes of living fetus. The blood vessels of the placenta of the two fetuses anastomose with each other, a third cycle occurs, causing fetal death (fetal transfer syndrome). Ultrasonography may identify the Fetus papyraceus, but is not always promising due to anatomical location. Cautious supervision is important during pregnancy for its positive outcome. We report a case of fetus papyraceus in Department of Gynecology and Obstetrics, Paropakar Maternity and Women's Hospital, Kathmandu, Nepal.

Keyword: fetus papyraceous, twin pregnancy, twin-twin transfusion syndrome

Introduction

Fetus papyraceus is a rare complication with a reported incidence of one in 12,000 pregnancies¹ and between 1:180 and 1:200 twin pregnancies.² Fetus papyraceus or fetus compressus refers to twin pregnancy, especially monozygotic twins, when the blood vessels of the placenta of the two fetuses anastomose with each other and the so-called third cycle occurs, which can cause fetal death (fetal transfer syndrome). One fetus dies and the other continues to develop. If it happens in the early stage, the dead fetus is absorbed; during 3-4 months it is compressed and flattened by the live fetus because the trunk has not been fully ossified and the water and amniotic fluid in the tissues are gradually absorbed.³

When fetus is absorbed completely, no complications other than first trimester bleeding occur. However, if the event occurs in the second or third trimester, serious complications may include premature labor, infection due to the death of the fetus and hemorrhage.³⁻⁵ Even at the end of the pregnancy, a low-lying fetus papyraceus may block the cervix and require a cesarean section to deliver the living twin.

We present a rare case of fetus papyraceus to revisit the clinical presentation and management.

Case Report

A 34-year woman, G₅P₃₊₁L₂ at 38 weeks of gestation, presented to our emergency department with the chief complaint of abdominal pain of 4-h duration, increasing in intensity and severity. She had been on regular antenatal checkup since first trimester. Her first trimester was uneventful and was diagnosed with monochorionic diamniotic twin at 12 w. During her second visit at 17 week of gestation the ultrasound scan showed a live fetus, breech presentation with adequate liquor and another twin with missed abortion.

Patient and her family members were well counseled about the risks upon continuation of pregnancy. She was doing her regular antenatal care (ANC) checkups and taking iron and calcium tablets daily. Ultrasound at 25 weeks showed twin pregnancy, with a live fetus with adequate liquor, and a second fetus as missed abortion. Routine blood investigations were normal. Her last visit was at 37⁺⁶ weeks, uterus size corresponded to 36 weeks, with fetal heart beats of 142 per minute.

On arrival in emergency two days after her last ANC checkup for increasing abdomen pain, the per vaginal examination showed cervical dilatation of 4 cm and intact membrane. She was allowed for vaginal delivery. A live female fetus of 2.1 Kg was delivered first, followed by delivery of a small papyraceus fetus, Figure 1. Patient was under observed for 24 h and then discharged.

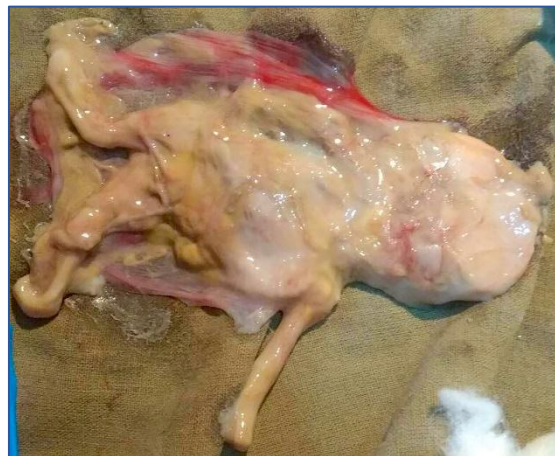

Figure 1. Fetus Papyraceus

Discussion

Our case arrived in active stage of labor, her uterine contractions and fetal heart sounds were monitored throughout the labor. She had successful vaginal delivery of a live female baby of 2.1 Kg, followed by delivery of a small papyraceus fetus.

Fetus papyraceus, in twin or multiple pregnancies occurs when growth of one is limited, resulting in early death and is

compressed into thin sheets by other fetuses. This kind of paper fetus mostly occurs in twin-twin transfusion syndrome. Prenatal monitoring is necessary for the diagnosis of twin-twin transfusion syndrome, and intervention to reduce the perinatal mortality.

Fetus papyraceus can occur in monochorionic and dichorionic multiple pregnancies. The causative factors in many cases remain unknown. In most cases death occurs in the second trimester.^{6,7} Velamentous cord insertion has been suggested for fetus papyraceus. Fetus papyraceus is reported to result from lethal nuchal cord. This condition is seen more frequently with monozygotic twin pregnancies than dizygotic twins. No connection is found with maternal age, parity or gravidity. Congenital anomalies with congenital abnormalities in second twin is found with intestinal atresia, gastroschisis, absent ear, aplasia cutis, central nervous system damage and anomalies of the heart in child.⁸ There are no complications to the mother or to the surviving twin in many cases, similar to the situation described in the case here.

Fetus papyraceus may be easily apparent at delivery but can appear only as a localized area of thickening within the membranes. Occasionally a fetus papyraceus is sufficiently large to cause obstruction during labor.⁹ Sometimes the dead fetus shrinks and is compressed against the membranes, eventually resembling amorphous necrotic tissue. Careful exploration of the placenta and membranes should be performed as many fetus papyraceus are diagnosed after delivery.¹⁰ After termination of twin pregnancies the thorough inspection of the newborn baby and histopathological investigation of the placenta is crucial.⁷

In twin-twin transfusion syndrome, there is blood circulation between the placentas of monozygotic twins, including anastomosis between arteries, veins and arteries and veins.¹¹ The first two kinds of blood distribute evenly without abnormality, and the blood circulation between arteries and veins

anastomoses. The arteriovenous communication between the two fetuses results in the blood communication between the two fetuses. Through the arteriovenous anastomotic branches between the fetuses, the blood is diverted unidirectionally from the artery to the vein, which makes one fetus become a blood supplier and the other as a result. The fetus becomes a recipient of blood, resulting in weight loss, dehydration, nutritional deficiency and death; while the recipient may have increased blood volume, cardiac hypertrophy, liver and kidney enlargement and other complications.¹²

When twin-twin transfusion syndrome is found by ultrasound, the amniotic fluid of the recipient could be extracted repeatedly, or the placental anastomosis vessels could be blocked by laser guided fetoscope. Ultrasonography is performed regularly for early detection and treatment.¹³

In our case, there was uneventful term pregnancy, presenting in emergency in active stage of labor, progressing with successful vaginal delivery of a live female baby, followed by delivery of a small papyraceus fetus. Patient was observed for 24 hours and discharged.

Conclusion

This rare case of fetus papyraceus in a 34-year woman had uneventful term delivery. Ultrasound diagnosed monochorionic diamniotic twin at 12 w and at 17 w showed a live fetus, with missed abortion of another twin. She had successful vaginal delivery of a live female baby, followed by delivery of a small papyraceus fetus.

Acknowledgement

We thank the doctors of the Dept. of Gynecology and Obstetrics, Paropakar Maternity and Women's Hospital, for providing the image and necessary information.

Conflict of Interest

None

Funding

None

Authors Contribution

All authors read and approved final draft, NS collected data, AB and NS wrote manuscript, SR and DG helped revise the manuscript.

Reference

1. Upadhyaya I, Pradhan M, Sharma R. Twin pregnancy with fetus papyraceus. *JNMA J Nepal Med Assoc.* 2009;48(175):246-8. DOI [PubMed](#) [GoogleScholar](#)
2. Chaudhary R, Verma S, Dadhich S, Meena A, Sehra RN. Delayed diagnosis of fetus papyraceus with microcephaly of surviving co-twin. *Indian J Clin Pract.* 2012;22(11):590-2. [Weblink](#)
3. Mittal PS, Khanna M. Two Papyraceus fetuses in a triplet pregnancy. *J Obstet Gynecol India.* 2007;57(1):77-8. [GoogleScholar](#) [Weblink](#)
4. Sinclair R. Foetus papyraceus. *S Afr Med J.* 1952;26(4):69-71. [PubMed](#) [GoogleScholar](#) [Weblink](#)
5. Kramer RL, Izquierdo LA, Gilson G, Curet L. The vanishing twin. *TheFetus.net* [Internet]. 1994. [Weblink](#)
6. Saier F, Burden L, Cavanagh D. Fetus papyraceus: an unusual case with congenital anomaly of the surviving fetus. *Obstet Gynecol.* 1975;45(2):217-20. DOI [PubMed](#) [GoogleScholar](#)
7. Csécssei K, Tóth Z, Szeifert GT, Papp Z. Pathological consequences of the vanishing twin. *Acta Chir Hung.* 1988;29(2):173-82. [PubMed](#) [GoogleScholar](#)
8. Daw E. Fetus papyraceus--11 cases. *Postgrad Med J.* 1983;59(695):598-600. DOI [PubMed](#) [GoogleScholar](#)
9. Mifsud W, Sebire NJ. Placental pathology in early-onset and late-onset fetal growth restriction. *Fetal Diagn Ther.* 2014;36(2):117-28. DOI [GoogleScholar](#)
10. Manjula NV, Sujani BK, Shetty S. Fetus papyraceus: a case report of preterm premature rupture of membranes with adherent placenta. *Proc Obstet Gynecol.* 2011;2(2):16. DOI [GoogleScholar](#) [Weblink](#)
11. De Paepe ME, Shapiro S, Greco D, Luks VL, Abellar RG, Luks CH, Luks FI. Placental markers of twin-to-twin transfusion syndrome in diamniotic-monochorionic twins: a morphometric analysis of deep artery-to-vein anastomoses. *Placenta.* 2010;31(4):269-76. DOI [PubMed](#) [GoogleScholar](#)
12. Holmes LB. *Common malformations.* Oxford: Oxford University Press; 2012. 470p.
13. Baud D, Windrim R, Van Mieghem T, Keunen J, Seaward G, Ryan G. Twin-twin transfusion syndrome: a frequently missed diagnosis with important consequences. *Ultrasound Obstet Gynecol.* 2014;44(2):205-9. DOI [PubMed](#) [GoogleScholar](#)