



ISSN: 2091-2749 (Print)
2091-2757 (Online)

Correspondence

Dr. Pradeep Raj Regmi
Department of Radiology and
Imaging, Hospital for Advanced
Medicine and Surgery (HAMS)
Kathmandu, Nepal
Email: pradeep.iom@gmail.com

Peer Reviewers

Dr. Rose House
Indiana University, US

Asst. Prof. Dr. Sumana
Bajracharya
Patan Academy of Health
Sciences

Submitted

20 Jan 2019

Accepted

25 Apr 2019

How to cite this article

Pradeep Raj Regmi, Isha
Amatya, Prajwal Dhakal, Ranjit
Kumar Chaudhary, Prakash
Kayastha, Sharma Poudel, Ram
Kumar Ghimire. Computed
tomography diagnosis of
truncus arteriosus type IV: a
case report. Journal of Patan
Academy of Health Sciences.
2019Jun;6(1):37-40.

Computed tomography diagnosis of truncus arteriosus type IV: a case report

Pradeep Raj Regmi¹, Isha Amatya², Prajwal Dhakal¹, Ranjit Kumar Chaudhary³,
Prakash Kayastha⁴, Sharma Poudel⁴, Ram Kumar Ghimire⁵

¹Radiologist, Hospital for Advanced Medicine and Surgery, Kathmandu; ²Resident, Kathmandu Medical College, Kathmandu; ³Grande International Hospital, Kathmandu; ⁴Asst. Prof. Tribhuvan University Teaching Hospital (TUTH), Kathmandu; ⁵Prof., TUTH, Kathmandu, Nepal

Abstract

Truncus arteriosus (TA) is an uncommon congenital cardiac anomaly of which type IV is considered a rare variant. Recognition is crucial for proper treatment planning. The prognosis without treatment is poor. Echocardiography alone may not be useful in evaluation. Computed tomography (CT) finding is complicated. We report an 18 months child with ventricular septal defect (VSD), diagnosed on echocardiography, and further review by CT showed VSD with descending thoracic aorta giving rise to the pulmonary arteries suggestive of pseudo truncus (Collet and Edwards Truncus arteriosus Type IV) and right sided aortic arch with mirror image branching.

Keywords: echocardiography, Collet and Edwards, computed tomography (CT), truncus arteriosus, ventricular septal defect (VSD)

Introductions

Truncus arteriosus (TA) is an uncommon congenital cardiac anomaly of which type IV is considered rarest of rare variant.¹ It is defined by a common origin of the aorta and the pulmonary arteries, resulting from an incomplete embryologic septation and separation of the aorta and the pulmonary trunk. This congenital cardiac anomaly was first described in 1798 by Wilson.

The prognosis without treatment is poor. Echocardiography alone may not be useful in evaluation of such congenital anomalies. Computed tomography (CT) imaging appearance of this anomaly is complicated and recognition of this rare variant is crucial for proper treatment planning.

In this case report we discuss about a case of type IV truncus arteriosus and its imaging appearance and other types of TA.

Case Report

A child of 18 months diagnosed with ventricular septal defect (VSD) presented for follow up of congenital heart disease. The child had mild cyanosis and dyspnea with recurrent episodes of fever and cough. Earlier echocardiography confirmed findings of VSD. For further evaluation, child was sent to our department for CT.

The CT imaging findings showed situs solitus with levocardia and VSD measuring 12 mm. Aortic arch was coursing anterior to lower trachea and carina to the right side. Common origin for left common carotid and left subclavian artery by formation of left brachiocephalic trunk was seen. Right common carotid artery and subclavian artery had separate origins from aortic arch. The left brachiocephalic artery was the first branch arising from the aortic arch. Descending thoracic aorta was seen giving rise to a collateral which was coursing anterior to the vertebra and posterior to esophagus.

It measured approximately 4 mm in diameter and spanned a length of approximately 3 cm. This branch gave rise to two other branches which were seen on either side of chest perfusing bilateral lung fields. There were also multiple collaterals arising from lower descending aorta which were giving rise to main pulmonary arteries on both sides. With the above findings, the provisional diagnosis was made for TA type IV. This was a case of VSD with descending thoracic aorta giving rise to the pulmonary arteries suggestive of pseudotruncus (Collet and Edwards Truncus arteriosus Type IV) and right sided aortic arch with mirror image branching.

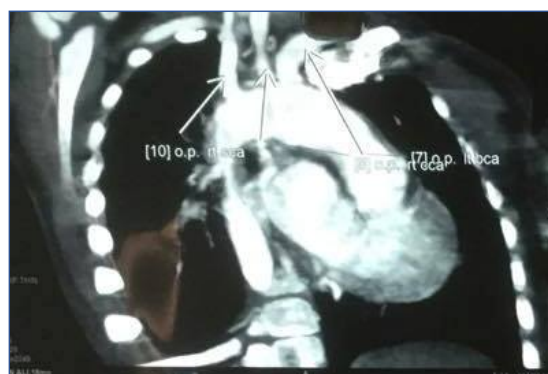


Figure 1. Right sided aortic arch with mirror image branching (left brachiocephalic artery arising as first branch of the arch)

Discussions

The TA accounts for 0.7-1.4% of all congenital heart diseases in live born infants. It is caused by the failure of the aortic-pulmonary septum to develop and separate the embryonic truncus into the aorta and main pulmonary artery. Etiology is multifactorial and 22q112 deletion (DiGeorge syndrome), maternal diabetes mellitus in pregnancy and teratogens such as retinoic acid have been reported with this condition.¹ It is commonly associated with the other cardiac anomalies in approximately 35%, and include right aortic arch, interrupted aortic arch, aberrant right subclavian artery, atrial septal defect, VSD, etc.¹

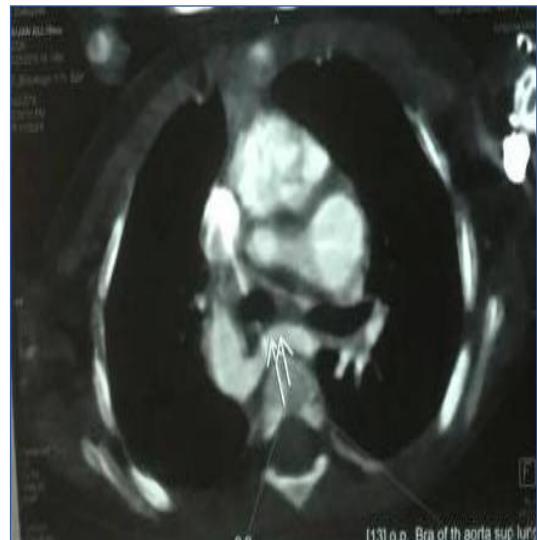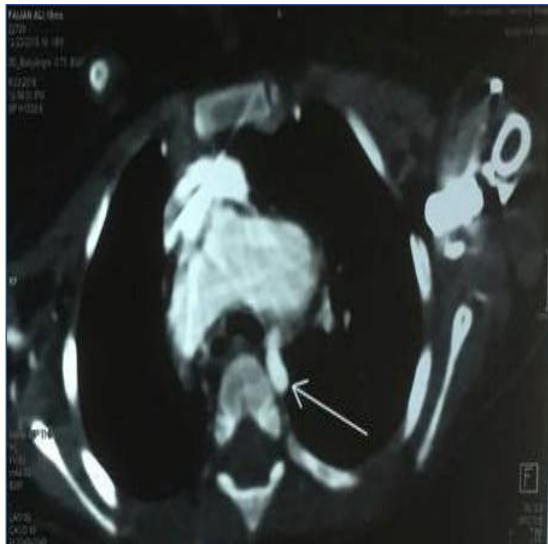


Figure 2 and 3. Two branches from the descending thoracic aorta are perfusing bilateral lung fields

Two systems of classification have been proposed for truncus arteriosus:

1. Collett and Edwards system² Type I-IV

Type I: (most common) both aorta and main pulmonary artery arise from a common trunk

Type II: pulmonary arteries arise separately from the posterior aspect of trunk, close to each other just above the truncal valve (negligible main pulmonary artery segment)

Type III: (least common) pulmonary arteries arise independently from either side of the trunk

Type IV: neither pulmonary arterial branch arising from the common trunk (pseudotruncus), currently considered a form of pulmonary atresia with a VSD; Pulmonary arteries are absent and the pulmonary circulation is supplied by multiple aorto-pulmonary collateral arteries (MAPCA) arising from descending aorta.

2. Van Praagh system³ type A1 - A4

Type A1: identical to the type I of Collett and Edwards

Type A2: separate origins of the branch pulmonary arteries from the common trunk

Type A3: origin of one branch pulmonary artery (usually the right) from the common trunk, with other lung supplied either by collaterals or a pulmonary artery arising from the aortic arch.

Type A4: presence of associated interrupted aortic arch.

Because the conus cordis is not partitioned properly below the truncal valve, a VSD usually exists at the infundibular septum beneath the truncal valve. This VSD is often large and nonrestrictive. The right ventricle, subjected to the systemic pressure generated by the left ventricle, becomes hypertrophic. In most instances (68-83%), the common arterial trunk and the truncal valve straddle the ventricular septum in a manner resembling the overriding aorta in tetralogy of Fallot or pulmonary atresia with VSD. Uncommonly (11-29%), the truncal valve aligns exclusively with the right ventricle. Rarely (4-6%), it aligns with the left ventricle. In the two latter situations, the VSD may be small or absent.⁴

Chest radiographs often show moderate cardiomegaly with pulmonary plethora (mainly as a result of collateral formation) and widened mediastinum. However, the main pulmonary artery (arising from common trunk) may be small or unusual in position which may result in a narrow mediastinum. This along with moderate cardiomegaly and

pulmonary plethora gives an appearance that is similar to D-loop transposition of great arteries.

Cardiac catheterization with angiography is indicated when pulmonary vascular disease is suspected and to define great vessels and coronary artery anatomy.

Prognosis is poor without treatment. Corrective operation i.e. closure of VSD, separation of pulmonary arteries from primitive truncus and right ventricular to pulmonary artery conduit-Rastelli's procedure) is indicated before 3 months of age to avoid development of severe pulmonary vascular obstructive disease.¹

Differential diagnosis of this condition⁵ include- Aortopulmonary septal defect (APSD), also known as aortopulmonary window (APW), is a congenital anomaly where there is an abnormal communication between the proximal aorta and the pulmonary trunk in the presence of separate aortic and pulmonary valves. The APSD has four types⁵: Type I: proximal APSD located just above the sinus of Valsalva, a few millimeters above the semilunar valve; Type II: distal APSD located in the uppermost portion of the ascending aorta; Type III: total defect involving the entire aortopulmonary septum or ascending aorta; Type IV: intermediate defect.

Conclusions

A child of 18 months of age with VSD was found to have Truncus Arteriosus Type IV on CT scan during follow-up visit for congenital heart disease.

References

1. Mittal SK, Mangal Y, Kumar S, Yadav RR. Truncus arteriosus type 1: a case report. *Indian Journal of Radiology and Imaging*. 2006;16(2):229-31. [GoogleScholar](#) [Weblink](#)
2. Collett RW, Edwards JE. Persistent truncus arteriosus: a classification according to anatomic types. *Surgical Clinics of North America*. 1949;29(4):1245-70. [DOI](#) [PubMed](#) [GoogleScholar](#)
3. Van Praagh R, Van Praagh S. The anatomy of common aorticopulmonary trunk (truncus arteriosus communis) and its embryologic implications: a study of 57 necropsy cases. *American Journal of Cardiology*. 1965;16(3):406-25. [DOI](#) [PubMed](#) [GoogleScholar](#)
4. Hanneman K, Newman B, Chan F. Congenital variants and anomalies of the aortic arch. *Radiographics*. 2017;37(1):32-51. [DOI](#) [PubMed](#) [GoogleScholar](#)
5. Kutsche LM, Van Mierop LH. Anatomy and pathogenesis of aorticopulmonary septal defect. *American Journal of Cardiology*. 1987;59(5):443-7. [DOI](#) [PubMed](#) [GoogleScholar](#)