



ISSN: 2091-2749 (Print)  
2091-2757 (Online)

#### Correspondence

Dr. Rajendra Sanjel Chhetri  
Department of Orthopedics  
Lumbini Zonal Hospital  
Butwal, Nepal  
Email: sanjelr@gmail.com

#### Peer Reviewers

Prof. Dr. Nabees MS Pradhan  
Patan Academy of Health  
Sciences

Prof. Dr. Jay N Shah  
Patan Academy of Health  
Sciences

#### Submitted

21 Mar 2019

#### Accepted

7 Jun 2019

#### How to cite this article

Rajendra Sanjel Chhetri, Kishor Prashad Khatri, Krishna Kharel. Outcome of fibular strut graft and two cannulated hip screws in neglected fracture neck of femur in adults - 10 years review. Journal of Patan Academy of Health Sciences. 2019Jun;6(1):25-30.

## Outcome of fibular strut graft and two cannulated hip screws in neglected fracture neck of femur in adults - 10 years review

Rajendra Sanjel Chhetri<sup>1</sup>, Kishor Prashad Khatri<sup>1</sup>, Krishna Kharel<sup>2</sup>

<sup>1</sup>Department of Orthopedics, Lumbini Zonal Hospital, Butwal, Nepal

<sup>2</sup>Department of Orthopedics, Lumbini Hospital and Technical College, Butwal Nepal

### Abstract

**Introductions:** Avascular necrosis and non-union are common but when the neck of femur fracture in adult is neglected, the chances of complications rises. Among various treatment options, we report the outcome of free fibular strut graft along with two cannulated hip screws in neglected fracture neck of femur.

**Methods:** The outcome analysis of 'fibular strut graft and two cannulated hip screws' was conducted in patients with fracture neck of femur who presented at least three weeks after the time of injury, during August 2008 to December 2017, at Lumbini Zonal Hospital and Lumbini Hospital Technical College, Butwal, Nepal. All adult patients aged 18 to 60 years were included. Outcome variables were healing of fracture (union, delayed union, non-union), avascular necrosis and Harris Hip Score (HHS).

**Results:** Out of 20 fractures, 17 (85%) united uneventfully, 2 (10%) had delayed union and 1 (5%) nonunion. We had 3 (15%) avascular necrosis of femoral head. The HHS was excellent in 8 (40%), good in 4 (20%), fair in 6 (30%) and poor in 2 (10%).

**Conclusions:** Fibular Strut graft with two hip screws resulted in fracture union and improved hip functions in patients with neglected fracture of neck of femur.

**Keywords:** avascular necrosis, fibular Strut graft, Harris hip score, neglected fracture neck of femur

## Introductions

Fracture neck of femur was traditionally known as an unsolved fracture.<sup>1</sup> In younger adults, less than 60 years old, aim is to save natural head. If presents late after three weeks or more from initial trauma then rate of complications, like avascular necrosis (AVN) and nonunion rises.

Results varies among various modalities to achieve osteosynthesis in order to salvage the head, for example, the muscle pedicle bone grafting, avascular or vascular fibular grafting, varieties of osteotomies along with various implants.<sup>2-4</sup> There is no agreed uniform modality to address the problem, accuracy of reduction and rigidity of fixation affects the final outcome.<sup>5,6</sup>

We analyzed the result of free fibular strut graft along with two cannulated cancellous screws in fracture neck of femur presenting late, three weeks or more from initial trauma.

## Methods

This retrospective outcome analysis included 10 years of data on fracture neck of femur presenting at least three weeks from time of injury and underwent surgery with 'fibular strut graft and two cannulated hip screws' during August 2008 to December 2017 at Lumbini Zonal Hospital and Lumbini Hospital Technical College, Butwal, Nepal. Adult patients aged 18 to 60 years were included. Patients with hip dislocation, seizure disorder, neurological deficit, pathological fracture and more than 2 cm gap between fragments were excluded. Ethical permission was obtained from the institutional review committee. Outcome variables were healing of fracture (union, delayed union, non-union), Harris Hip Score and complications (avascular necrosis, infection, screw displacement, shortening, donor site discomfort). Union of fracture was based on radiological findings.

Patients were admitted in orthopedic ward and proximal tibial skeletal traction was applied. Operation was carried out under spinal anesthesia. Close reduction was done

on fracture table with Whitman<sup>7</sup> technique and verified for acceptable reduction on image intensifier following Garden alignment index of 160-180<sup>0</sup> angle in anteroposterior view between medial femoral cortex and central axis of medial compressive trabeculae. Angle of 180<sup>0</sup> with deviation of less than 20<sup>0</sup> was accepted in X-ray of hip in lateral view.<sup>8</sup>

Fibula was harvested at middle third, sub periosteal and multiple nibbling done at interosseous boarder. Drilling was not done to avoid weakening the strength of graft. Under image control, reduction stabilized temporally with a 3 mm Kirschner wire (K wire) placed superior most in neck. First guide wire inserted inferiorly and slight anteriorly just above the inferior cortex of neck. Second guide wire placed at middle and slight posteriorly and third superiorly and slight anterior, below the 3 mm K-wire making an inverted triangular configuration as far as feasible. Thus, four wires were placed inside neck. Over the inferior guide wire, 6.5 mm cannulated hip screw was used to fix the fracture, and then with dynamic hip screw (DHS) triple channel reamer, hole reamed over second guide wire, length measured and fibula inserted over guide wire, impaction done with Kuntschner nail (K-Nail) impactor. Extra stump of fibula outside femoral cortex was sawed off and multiple pieces of thus excised fibula were used to impact the grafted fibula around the outer hole on femur to prevent back out. Finally, after placement of cannulated hip screw over superior guide wire, the superior most K wire was removed and wound closed in layers over a suction drain.

Non-weight bearing crutch walking was encouraged until sign of bridging callus and then gradual weight bearing allowed. Patients were asked for regular follow up. Study variables recorded were pain, ability to walk distance, gait, hip range of motion (ROM), deformity, any complications, radiological status of fracture union and sign of AVN. Harris hip score (HHS)<sup>9</sup> at final follow up was used to evaluate the outcome, Figure 1. Data were analyzed descriptively using Microsoft Excel.

**Results**

There were 20 patients, 14 male and 6 female, average age 38.6 years (range 18-55).

Delay of operation from time of injury was 4.8 weeks (range 3-14), time of union 21.6 weeks (range 14-48) and average follow up 39.4 months (range 22-80 months).

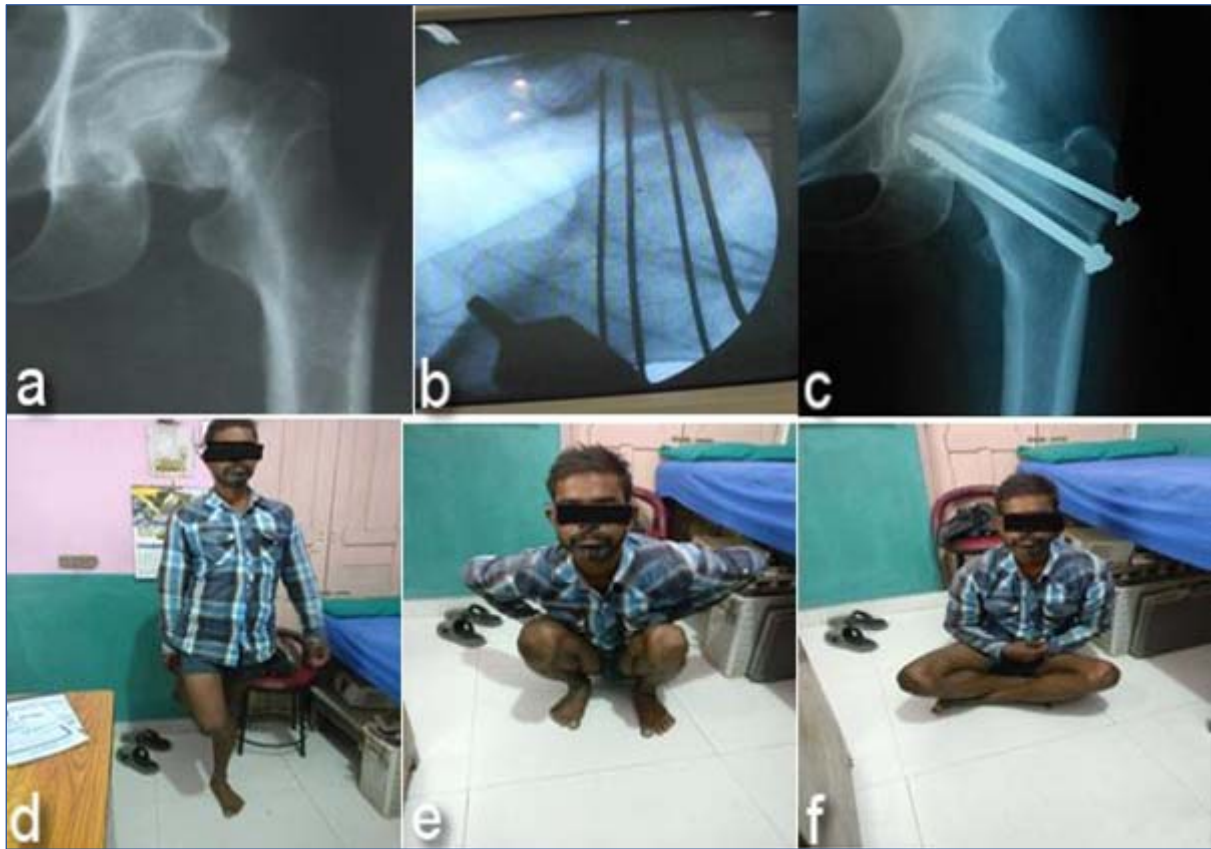

Figure 1. Fracture neck of femur (a), Superior most K-wire and three guide wires (b), Post-operative X-ray (c), Follow up at thirty months- standing on operated leg (d), Squatting (e), Sitting crossed leg (f).

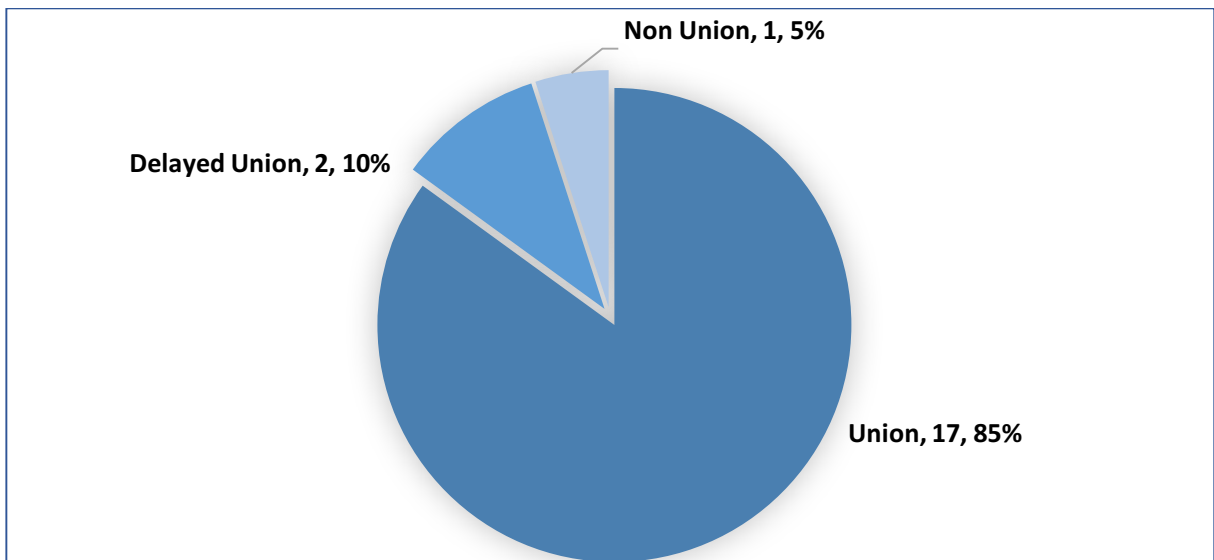


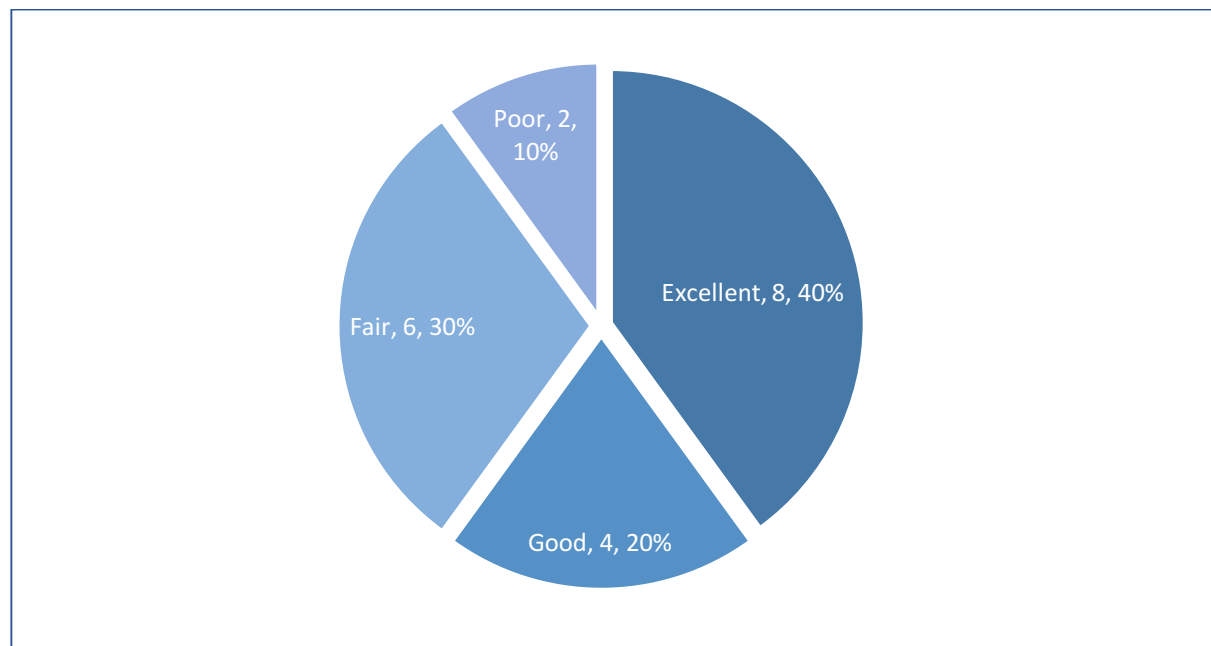
Figure 2. Fracture Union of neck of femur presenting late after three weeks of trauma managed with free fibular strut graft along with two cannulated cancellous screws

Seventeen of 20 (85%) fracture united uneventfully, 2 (10%) had delayed union and 1 (5%) who failed to unite had late deep infection and underwent Girdlestone type of excision arthroplasty, Figure 2. Among two delayed union, one who had postero-superior comminution and slight varus reduction took 36 weeks to unite; another had broken fibula,

screw back out and shortening of 2 cm, fracture united in 48 weeks. We had 3 (15%) AVN, two of them complained of occasional pain on exertion but were satisfied from operation, and one had poor outcome with HHS of 52. The HHS showed overall satisfactory (excellent, fair and good) results in 18 (90%), Figure 3.

**Table 1. Complications in neck of femur fracture (n=22) presenting late after three weeks of trauma managed with free fibular strut graft along with two cannulated cancellous screws**

SN	Nature of complications	Frequency	Remarks
1	Non Union	1	Late infection, excision arthroplasty done
2	Delayed Union	2	Took 9 and 12 months to unite
3	Avascular Necrosis	3	2 have mild symptoms, no revision required till final follow up, 1 HHS 52 -revision discussed
4	Broken fibular graft	1	With delayed union
5	Shortening (< 2.0 cm)	5	Resorption at fracture site
6	Hip Screws backing out	3	Resorption and delayed union
7	Head cut through by screw	1	Superior screw, removed later
8	Varus alignment (<10 <sup>0</sup> )	1	Posterosuperior comminution
9	Late Infection	1	Alcoholic patient, Girdlestone Excision
10	Superficial infections	3	Cured by few dressings
11	Donor site discomfort	4	Mild weakness of toe extension, on and off pain and discomfort, one had abscess required drainage



**Figure 3. Final Harris Hip Score in neck of femur fracture (n=20) managed with free fibular strut graft along with two cannulated cancellous**

**Discussions**

Overall, our study shows satisfactory (excellent 8, fair 6 and good 4) HSS 10 in 18 (90%) out of 20 patients after free fibular strut graft along with two cannulated

cancellous screws in fracture neck of femur presenting late after three weeks from initial trauma. Fracture united uneventfully in 17 (85%), had delayed union in 2 (10%) and failed to unite in 1 (5%). Various studies have shown that fibular strut graft along with two hip

screws gives rigidity in construct achieving high rate of union and painless stable hip. Accuracy of reduction and rigidity of fixation affects the final outcome.<sup>10</sup>

The neglected femoral neck fracture in young adults is difficult to treat and salvaging the head is a challenge. Dickson's epithet of the "unsolved fracture" is especially applicable.<sup>1,11</sup> There is no uniform consensus, but most agree for salvaging the head in young adults presenting late.<sup>5,6</sup> Treatment options include valgus osteotomy with or without bone graft and osteosynthesis using various implants and bone grafting techniques (muscle pedicle, vascularized, or free fibula) with variable outcome, union rate of 60-95%.<sup>2,3,5</sup> Osteosynthesis approaches help achieve union. McMurray or valgus trochanteric osteotomy alter the biomechanics of hip, decreasing abductor lever arm thus creating a possible limp.<sup>5</sup> Vascular graft is technically demanding.

In our study the high rate of uneventful union in 17 (85%) and overall union in 19 (95%), could be due to stable fixation with upper and lower two screws and fibula in between acting as biological implant. Furthermore, the inverted triangular construct add rigidity and enhance healing as reported in other studies.<sup>12</sup> Delayed union in two of our cases may be due to posterosuperior comminution in one and resorption at fracture site with backing out of screws in another. Avascular necrosis seen in three cases in our study, all fractures eventually united, showing no correlation between AVN and fracture union. The systemic review shows AVN and fracture site resorption of less than 2.5 cm can be successfully treated by fibular strut grafting.<sup>13</sup> The study in stage one and two neglected fracture neck of femur with fracture gap less than 2.5 cm has reported good results of osteosynthesis.<sup>14</sup> One case of nonunion in our series was in alcoholic patient who developed late deep infection and had to go Girdlestone type of excision arthroplasty.

Overall our result is comparable with published series reporting 86.7% union, 13.3% AVN and final satisfactory HSS 86.7%.<sup>15</sup>

Similarly, double fibular graft reports 92.3% union, and quadratus femoris muscle pedicle bone graft with two hip screws reports 90.1% union.<sup>16,2</sup>

We nibbled interosseous boarder of fibula but avoided drilling the graft that may have given us less amount of graft fracture. In view of successful salvage of natural head in young adults, the concern of donor site morbidity is less important, and have few if any serious morbidity.<sup>17</sup> Mild discomfort and weakness of toes extension in three cases was seen in our series.

We did not specifically analysed the cost, but in developing countries like Nepal, financial constrain may be an issue for implants in hemiarthroplasty. Thus, adults with posterior comminution can benefit from primary fibular osteosynthesis even in fresh fracture neck of femur as reported in leterature.<sup>18-20</sup> Our result shows this simple procedure can be done at simple orthopedic facilities with image intensifier.

## Conclusions

Osteosynthesis with fibular strut graft and two cancellous hip screws, one screw above and another below the graft, gives good results in neglected fracture neck of femur in young adults. The procedure is simple and effective with high rate of fracture union, painless, stable and mobile hip.

## Conflict of Interests

None. No Financial aid or other benefit received from any source.

## Fundings

None.

## References

1. Dickson JA. The unsolved fracture: a protest against defeatism. *J Bone Joint Surg Am.* 1953;35(4):805-22. [PubMed](#) [GoogleScholar](#) [Weblink](#)

2. Baksi DD, Pal AK, Baksi DP. Osteosynthesis of ununited femoral neck fracture by internal fixation combined with iliac crest bone chips and muscle pedicle bone grafting. *Indian J Orthop.* 2016;50(4):366-73. DOI PubMed GoogleScholar Weblink
3. Kainth GS, Yuvarajan P, Maini L, Kumar V. Neglected femoral neck fractures in adults. *J Orthop Surg (Hong Kong).* 2011;19(1):13-7. DOI PubMed GoogleScholar
4. Nagi ON, Dhillon MS. Management of neglected/ununited fractures of the femoral neck in young adults. *Current Orthopaedics.* 2003;17(5):394-402. DOI GoogleScholar
5. Azam MQ, Iraqi AA, Sherwani MK, Sabir AB, Abbas M, Asif N. Free fibular strut graft in neglected femoral neck fractures in adult. *Indian J Orthop.* 2009;43(1):62-6. DOI PubMed GoogleScholar Weblink
6. Slobogean GP, Sprague SA, Scott T, McKee M, Bhandari M. Management of young femoral neck fractures: is there a consensus? *Injury.* 2015;46(3):435-40. DOI PubMed GoogleScholar
7. Whitman R. A critical analysis of the treatment of fracture of the neck of the femur. *Ann Surg.* 1914;60(4):485-92. DOI PubMed
8. Weinlein JC. Fractures and dislocations of hip. In: Azar FM, Beaty JH, Canale ST (eds.) *Campbell's operative orthopaedics.* 13th ed. Vol 3. Philadelphia: Elsevier; 2017. p. 2818-20.
9. Nilsson A, Bremander A. Measures of hip function and symptoms: Harris Hip Score (HHS), Hip Disability and Osteoarthritis Outcome Score (HOOS), Oxford Hip Score (OHS), Lequesne Index of Severity for Osteoarthritis of the Hip (LISOH), and American Academy of Orthopedic Surgeons (AAOS) Hip and Knee Questionnaire. *Arthritis Care Res.* 2011;63(Suppl 11):S200-7. DOI PubMed GoogleScholar Weblink
10. RK Goyal, Chandra H, Pruthi KK, Nirvikalp. Fibular grafting with cannulated hip screw fixation in late femoral neck fracture in young adults. *Indian J Orthop.* 2006;40(2):94-6. DOI GoogleScholar Weblink
11. Roshan A, Ram S. The neglected femoral neck fracture in young adults: review of a challenging problem. *Clin Med Res.* 2008;6(1):33-9. DOI PubMed GoogleScholar Weblink
12. Mohapatra NC, Jain G, Panigrahi TK. Results of nonvascular fibula grafting with osteosynthesis in neglected fracture neck of femur. *J Orthop Traumatol Rehabil.* 2014;7(2):150-6. DOI GoogleScholar Weblink
13. Tripathy SK, Sen RK, Goyal T. Nonvascularized fibular grafting in nonunion of femoral neck fracture: a systematic review. *Indian J Orthop.* 2016;50(4):345-51. DOI PubMed GoogleScholar Weblink
14. Sandhu HS. Management of fracture neck of femur. *Indian J Orthop.* 2005;39(2):130-6. DOI GoogleScholar Weblink
15. Khani GM, Hafeez K, Bux M, Rasheed N, Ahmed N, Anjum MP. Use of fibular bone graft and cancellous screw fixation in the management of neglected femur neck fractures in young patients. *Int J of Health Sci.* 2017;11(5):7-10. DOI PubMed GoogleScholar Weblink
16. Jaiswal A, Pruthi KK, Goyal RK, Pathak V, Habib M, Tanwar YS, et al. Evaluation of osteosynthesis with dual fibular bone grafting for neglected femoral neck fractures. *J Clin Orthop Trauma.* 2013;4(2):58-69. DOI PubMed GoogleScholar
17. Anderson AF, Green NE. Residual functional deficit after partial fibulectomy for bone graft. *Clin Orthop Relat Res.* 1991;267:137-40. PubMed Weblink
18. Nagi ON, Gautam VK, Marya SK. Treatment of femoral neck fractures with a cancellous screw and fibular graft. *J Bone Joint Surg Br.* 1986;68(3):387-91. DOI PubMed GoogleScholar Weblink
19. Singh S, Kumar D, Kumar S. Long term results of fresh femoral neck fractures treated by cancellous screw and fibular autograft. *MOJ Orthop Rheumatol.* 2014;1(3):00020. DOI GoogleScholar Weblink
20. Zahid M, Sabir AB, Asif N, Julfiqar M, Khan AQ, Ahmad S, Siddiqui YS. Fixation using cannulated screws and fibular strut grafts for fresh femoral neck fractures with posterior comminution. *J Orthop Surg (Hong Kong).* 2012;20(2):191-5. DOI PubMed GoogleScholar Weblink