



ISSN: 2091-2749 (Print)
2091-2757 (Online)

Correspondence

Dr. Yuba Raj Sharma
Associate professor, Department of
Internal medicine
Patan Hospital, Patan Academy of
Health Sciences, Lalitpur, Nepal
Email: dryubarajsharma@yahoo.com

Peer reviewed by

Mr. Shital Bhandary
Patan Academy of Health Sciences

Dr. Reetu Baral
Patan Academy of Health Sciences

Extra intestinal manifestation of Crohn's disease in a university teaching hospital, Nepal

Yuba Raj Sharma

Associate professor
Department of Internal Medicine, Patan Academy of Health Sciences, Lalitpur,
Nepal

ABSTRACT

Introductions: Crohn's disease relatively uncommon gastrointestinal disease in Asia pacific region. There is increasing reports of this disease in the region. Aim of this study was analyze the demographics and extraintestinal manifestation of Crohn's disease in tertiary care hospital setup in Nepal.

Methods: This was a retrospective study of patients with Chron's disease seen in gastroenterology unit of Patan Hospital from 2009 to 2014. Case records were analyzed for age, gender, geography and extra intestinal manifestations.

Results: Eighteen patients with Crohn's disease were identified, 13 male and five female. Age ranged from 14 to 70 years, with peak during 21-30 years. There were seven (39%) patients with extra intestinal manifestations of arthritis, aphthous ulcer in oral cavity, erythema nodosum and episcleritis in descending order.

Conclusions: There were 18 cases in five years from in our tertiary care hospital and seven patients had extra intestinal presentation mainly arthritis and oral aphthous ulcer. Clinicians in Asian region need to be vigilant of Chron's, once thought be the disease of developed countries.

Keywords: crohn's disease, extra intestinal manifestation, inflammatory bowel disease

Plain Language Summary

This study was done to see if extra intestinal manifestations are present in patients with Crohn's disease. Arthritis and oral ulceration were found to be more common than other extra intestinal manifestations in consistent with the Western and Asian studies and in contrast to some other Asian studies.

INTRODUCTIONS

Crohn's disease is an inflammatory bowel disease which may affect any part of gastrointestinal tract (GIT) with more common involvement of small intestine and colon. Extra intestinal manifestations of inflammatory bowel disease (IBD) is common and may involve up to 25% of patients with IBD. These manifestations are common during active as well as inactive phase of the disease.¹ It has traditionally been considered that Crohn's disease is more common in developed countries and low incidence in Asia pacific region. Recent reports from India, China and Japan have shown it as an emerging disease in part of the world where tuberculosis and infective colitis have been thought predominant.²

The aim of the study was to find out the extraintestinal manifestations of Crohn's disease among a sample of Nepalese population and to identify any difference between the result in our population and other Asian and Western population.

METHODS

This was a retrospective study of the patients diagnosed with Crohn's disease in GI unit at Patan Hospital, Patan Academy of Health Sciences, Lalitpur, Nepal, between 2009 January to 2014 December. Patients file were retrieved from record section collect data on demographics (age, gender, residents of Kathmandu or outside) and clinical presentations (intestinal and extraintestinal manifestations). Microsoft Excel 2013 was used for the descriptive analysis of numbers and percentages.

RESULTS

During four years period, 18 patients were diagnosed with Chron's disease. Among 18 Chron's disease, male gender was 13 (72%) and female five (18%) with age ranging from 14 to 70 years.

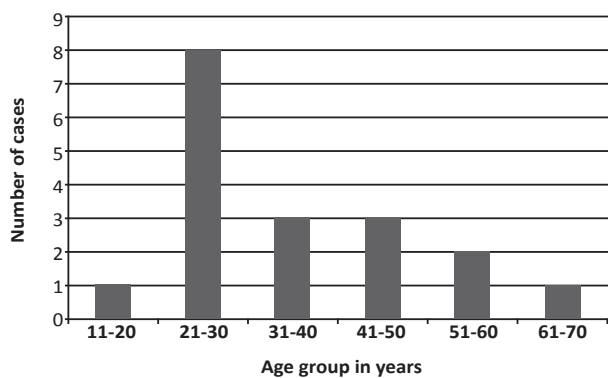


Figure 1. Age distribution of patients with Crohn's disease (n=18)

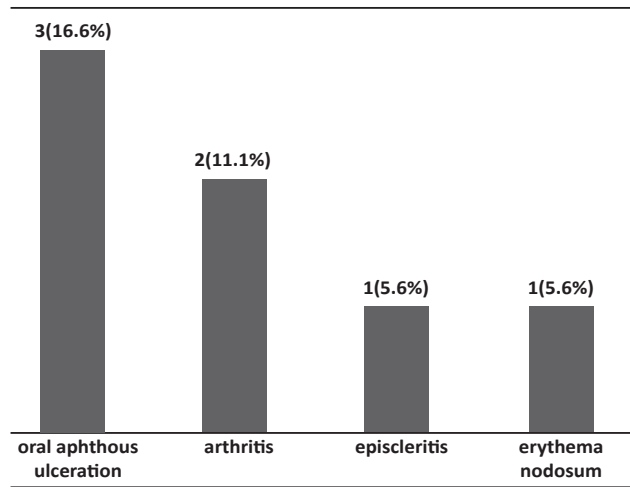


Figure 2. Seven patients with extra intestinal manifestations of Crohn's disease (n=18)

DISCUSSIONS

In this study, seven (38.9%) patients out of 18 Chron's disease had extra gastrointestinal manifestations, more than studies from other Asian countries, with 6.1% from China and Singapore.³ Some other studies have shown association with ethnicity, Jewish (35%) being more affected than Ashkenazi (17%).⁴ Our findings is in contrast to the reports of uncommon occurrence Chron's in a study from Pakistan.⁵ This is an area which could be looked into in future in our society. Our patients had aphthous ulceration of mouth in three (16.3%), more common than 3.1% in 'APDW 2004 Chinese IBD Working Group' with 515 cases of Crohn's disease. Chinese.⁶ Others have revealed up to 70% oral ulceration.⁷ We had two patients (11.11%) with arthritis, similar to the 9.1% of Chinese patients and 10-20% of patients in developed countries.⁸ Similarly, erythema nodosum in one (5.55%) of our patients was slightly higher than 3.1% of Chinese and less than from developed countries 6-15%.⁸ Episcleritis seen in one (5.55%) of our patients was higher than 2.3% in Chinese series and similar to Orchard etal report of episcleritis in five percent of 483 cases of Crohn's.

Despite the reports that Crohn's disease is relatively uncommon in Asian countries, our findings shows it is not so uncommon and we need to give more importance to the recording and reporting of its incidence, demographic profiling and clinical manifestation for early diagnosis and management of the disease in Nepal and region.

CONCLUSIONS

Cronh's disease is increasingly detected in developing Asian countries like Nepal, with 18 cases in five years from one tertiary hospital in this study. Oral aphthous

ulcer and arthritis were common extra intestinal manifestations. Clinician need to be vigilant of this once thought be the disease of developed countries.

REFERENCES

1. Judge TA, Lichtenstein GR. Inflammatory bowel disease. In: Friedman SL, McQuaid KR, Grendell JH. Editors. Current diagnosis and treatment in gastroenterology. 2nd ed. New York: Mc Graw Hill; 2003. p.536-45.
2. Goh K, Xiao SD. Inflammatory bowel disease: a survey of the epidemiology in Asia. *J Dig Dis*. 2009;10(1):1-6.
3. Wang YF, Zhang H, Ouyang Q. Clinical manifestations of inflammatory bowel disease: East and west differences. *J Dig Dis*. 2007;8(3):121-7.
4. Fidder HH, Avidan B, Lahav M, Bar-Meir S, Chowers Y. Clinical and demographic characterization of Jewish Crohn's disease patients in Israel. *J Clin Gastroenterol*. 2003;36(1):8-12.
5. Abbas Z, Khan R, Abid S, Hamid S, Shah S, Jafri W . Is Crohn's disease less severe in Pakistan than in the West? *Trop Doct*. 2004Jan;34(1):39-41.
6. APDW2004 Chinese IBD Working Group. Retrospective analysis of 515 cases of Crohn's disease hospitalization in china: nationwide study from 1990 to 2003. *J Gastroenterol Hepatol*. 2006;21(6):1009-15.
7. Fujimara Y, Kamoï R, Iida M. Pathogenesis of aphthous ulcers in Crohn's disease: correlative findings by magnifying colonoscopy , electron microscopy and immunohistochemistry. *Gut*. 1996;38(5):724-32.
8. Orchard TR, Chua H, Jewell DP. Clinical features of erythema nodosum (EN) and uveitis associated with inflammatory bowel disease. *Gastroenterolo*. 2000;118:755.