

Bleeding Meckel's Diverticulum in an Infant

Shrestha MK¹, Gurubacharya RL², Devkota K³, Agarwal N⁴

Abstract

Meckel's diverticulum is a congenital diverticulum. Mostly it is asymptomatic. In children the commonest complication is lower GI bleeding. High index of suspicion is required for its diagnosis. Technetium-99m pertechnetate scan is useful to detect ectopic gastric mucosa. Surgical treatment of symptomatic Meckel's diverticulum is diverticulectomy or ileal resection.

Key words: Meckel's diverticulum, painless per rectal bleeding, anemia

Introduction

Meckel's diverticulum is a congenital diverticulum that results from failure of obliteration of vitellointestinal (omphalomesenteric) duct. It is present in about 2% population, located at the anti-mesenteric border of the ileum about 2 feet proximal to the ileocecal junction and about 2 inches long. Mostly Meckel's diverticulum is asymptomatic. However, the complications like lower GI bleeding, intestinal obstruction, diverticulitis, persistent vitellointestinal duct fistula, intussusception, ulceration or perforation may occur.

The Case

A one year old boy from Kathmandu was admitted at Kathmandu Model Hospital with the complaints of two episodes of per rectal bleeding in two days and mild fever, cough and running nose for two days.

The bleeding was painless in nature, moderate in amount, bright red in colour and was mixed with stool. The child had no complaints of abdominal pain, distention and vomiting. There was no history of bleeding from any other sites and no petechiae and echymosis were seen. There was no history of bleeding disorder in the family. The child had no history of milk allergy.

The child was born at home out of non consanguineous marriage. He was immunized according to EPI schedule. His developmental milestones were appropriate for age. His height, weight and head circumference were within normal limits.

On examination, the child was active, playful, with moderate anaemia. The vitals were normal. The abdomen was soft, non-

¹Dr. Manoj Krishna Shrestha MBBS, MS Pediatric Surgery, Consultant Paediatric Surgeon, Kathmandu Model Hospital, ²Dr. Rajesh Lal Gurubacharya, MBBS, MD, Consultant Paediatrician, Kathmandu Model Hospital, Kathmandu, ³Dr. Kriti Devkota, MBBS, Medical Officer, Kathmandu Model Hospital, ⁴Dr. Nandan Agarwal, MBBS, Medical Officer, Kathmandu Model Hospital, Kathmandu, Nepal.

Address for correspondence

Dr. Manoj Krishna Shrestha
E-mail: shresthamanoj@hotmail.com

How to cite

Shrestha MK, Gurubacharya RL, Devkota K, Agarwal N. Bleeding Meckel's Diverticulum in an Infant. *J Nepal Paediatr Soc* 2014;34(1):54-56.

doi: <http://dx.doi.org/10.3126/jnps.v34i1.9523>

This work is licensed under a Creative Commons Attribution 3.0 License.



tender and there was no organomegaly. Rest of systemic examination findings was also normal.

On digital rectal examination, no fissure was seen, the anus was adequate and rectum was empty. No polyp or intussusception was palpated and bright red coloured blood stained the examining finger.

His haemoglobin was 5.3 gm/dl and total count was 19,300/cumm. Differential count, ESR, platelet count, Na⁺/K⁺, urea/creatinine were within normal limits. His bleeding and coagulation profile were normal. An ultrasound scan of abdomen was done to rule out intussusception which showed no intraabdominal pathology.

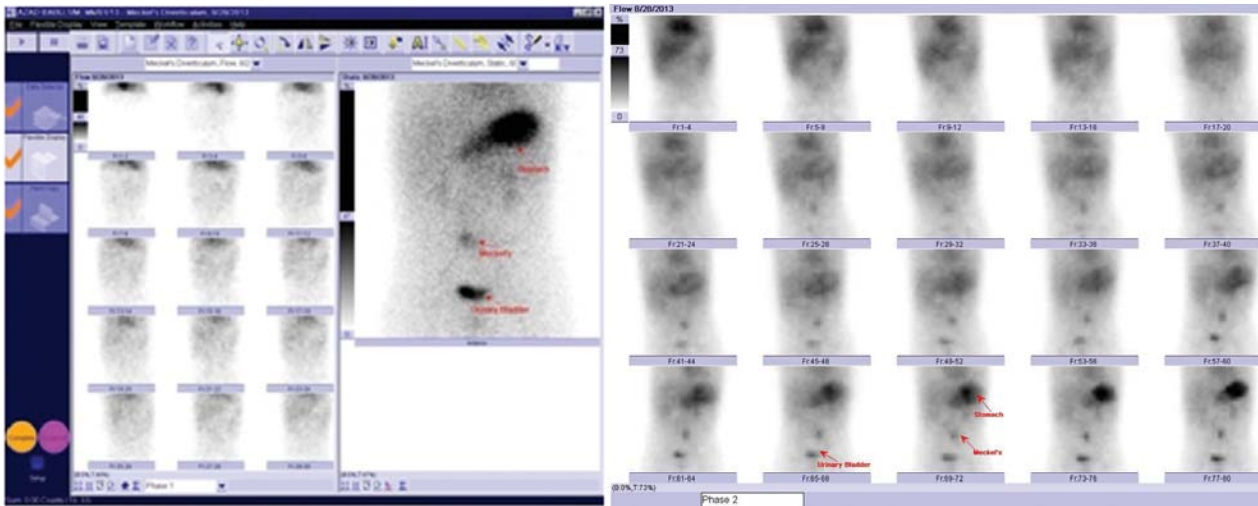


Fig 1: Meckel's (99m Tc Pertechnetate) scan showing increased uptake of radiotracer in left upper quadrant (gastric mucosa) and lower right quadrant near midline (ectopic gastric mucosa in Meckel's diverticulum) above the urinary bladder region.

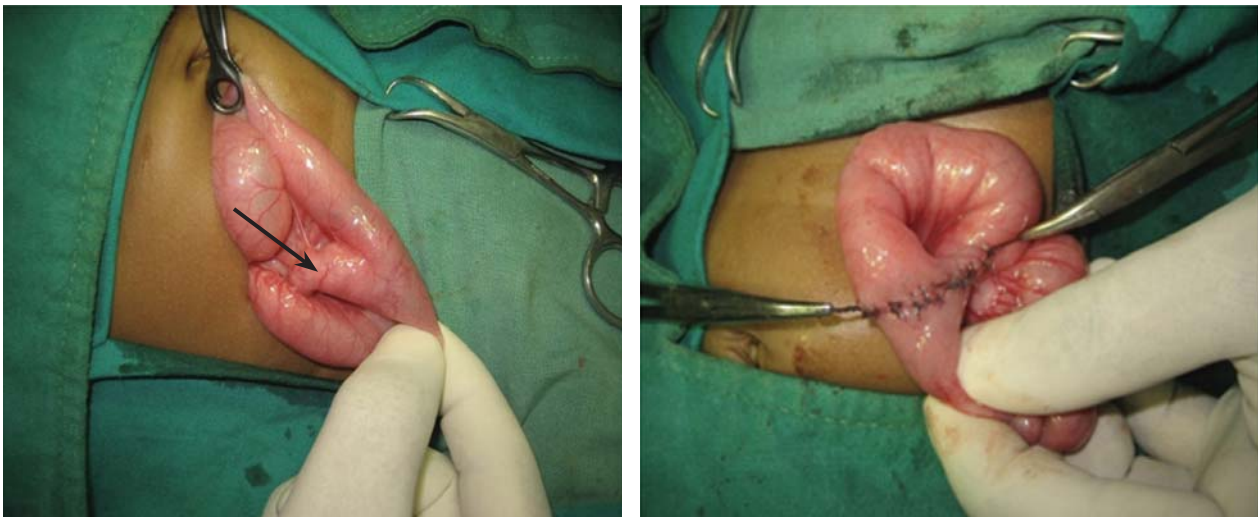


Fig 2: Peroperative finding of Meckel's diverticulum (arrow) and wedge resection of the diverticulum

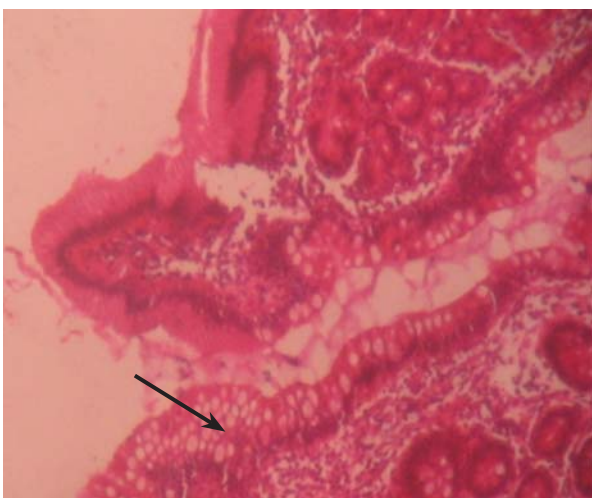


Fig 3: Photomicrograph showing gastric type of mucosa in the Meckel's diverticulum.

After excluding common and rare possibilities, Meckel's diverticulum was suspected and Meckel's scan was performed which was positive for Meckel's diverticulum (Fig. 1). Laparotomy and wedge resection of Meckel's diverticulum was done (Fig. 2). The postoperative period was uneventful. The histopathology of resected Meckel's diverticulum showed small intestinal mucosa with focal gastric mucosa (Fig. 3).

Discussion

Meckel's diverticulum results due to failure of obliteration of vitellointestinal duct (omphalomesenteric duct). The condition was first described by Fabricius Hildanus in 1598 but derives its name from a German anatomist Johann Friedrich Meckel who described the

embryological and pathological features¹. It is a true diverticulum as it contains all the layers of intestine and has its own blood supply. The blood supply is derived from persistent vitelline vessels supplied from the SMA². A general rule of 2 is followed: present in 2 % population, 2 feet away from ileocaecal valve and 2 inches long although many anatomical variations exist. In many cases Meckel's diverticulum is asymptomatic. Cullen et al reported in a population based study that the lifetime risk of developing a complication of Meckel's diverticulum was estimated to be 6.4%³. The complications like painless per rectal bleeding, intestinal obstruction, diverticulitis, persistent vitellointestinal duct fistula, intussusception, ulceration or perforation may occur⁴. It mimics various abdominal disorders like appendicitis, peptic ulcer disease or chrohn's disease which makes its diagnosis difficult.

It is stated that Meckel's diverticulum is frequently suspected, often looked and seldom found. However it should be suspected in any young child who presents with significant amount of painless rectal bleeding⁵. The diagnosis cannot be made with plain radiographs. Contrast studies such as upper gastrointestinal series with small bowel follow-through are of limited value. Computed tomographic scans are often nonspecific but occasionally helpful. The most useful method of detection of a Meckel's diverticulum is technetium-99m pertechnetate scanning⁶. However, the technetium scan depends on uptake by heterotopic gastric mucosa. Meckel's scan has 85% sensitivity and 95% specificity⁷. The sensitivity and specificity of the scan can be improved by pentagastrin and glucagon or cimetidine⁸.

Conclusion

Meckel's diverticulum is present in 2% of the population. Mostly it is asymptomatic with lifetime complication rate of around 6.4%. A high index of suspicion is required for the diagnosis of Meckel's diverticulum in case of painless per rectal

bleeding with significant anemia. Technetium-99m pertechnetate scan is useful in presence of ectopic mucosa. When symptomatic, Meckel's diverticulum needs diverticulectomy or ileal resection.

Acknowledgement: Sincere thanks to Dr Sagar Maharjan for the scan picture and Dr. Anjani Tuladhar, Pathologist for the photomicrograph.

References

1. Opitz JM, Schultka R, Gobbel L. Meckel on developmental pathology. *Am J Med Genet A* 2006; 140(2):115-28.
2. Sagar J, Kumar V, Shah D K. Meckel's diverticulum: a systematic review. *J R Soc Med* 2006;99:501-505.
3. Cullen JJ, Kelly KA, Moir CR, Hodge DO, Zinsmeister AR, Melton LJ 3rd. Surgical management of Meckel's diverticulum. An epidemiologic, population-based study. *Ann Surg.* Oct 1994;220(4):564-8; discussion 568-9.
4. Dumper J, Mackenzie S, Mitchell P, Sutherland F, Quan ML, Mew D. Complications of Meckel's diverticula in adults. *Can J Surg.* Oct 2006;49(5):353-7.
5. St-Vil D, Brandt ML, Panic S, et al. Meckel's diverticulum in children: a 20 year review. *J Pediatr Surg* 1991; 26:1289-1292.
6. Sfakianakis GN, Haase GM. Abdominal scintigraphy for ectopic gastric mucosa: a retrospective analysis of 143 studies. *AJR Am J Roentgenol* 1982; 138:7-12.
7. Cooney DR, Duszynski DO, Camboa E, et al. The abdominal technetium scan - a decade of experience. *J Pediatr Surg* 1982; 17:611.
8. Petrokubi RJ, Baum S, Rohrer GV. Cimetidine administration resulting in improved pertechnetate imaging of Meckel's diverticulum. *Clin Nucl Med* 1978;3(10):385-8.