

Pasmodium Vivax Malaria Complicated by Neurological, Jaundice and Haemophagocytic Syndrome

Ram Kumar TV¹, Baghmar S²

¹Dr. T.V. Ram Kumar, MBBS, MD. (Paediatrics), Senior Resident, ²Dr. Shilpa Baghmar, MBBS, MD (Paediatrics), Senior Resident. Both from Maulana Azad Medical College, New Delhi, India.

Address for Correspondence: Dr. TV Ram Kumar, E-mail: starringam@gmail.com

Abstract

We are describing a case of plasmodium vivax malaria in a child with complications including pancytopenia secondary to marrow involvement, jaundice and neurological features. The child improved with antimalarial treatment.

Introduction

Hemophagocytic syndrome (HS) is a disease of mononuclear phagocytic system, which is characterised by benign, generalized histiocytic proliferation, with hemophagocytosis (phagocytosis of haematopoietic cells) observed in bone marrow¹. This syndrome is commonly associated with haematological malignancies, autoimmune conditions, viral, bacterial or parasitic infections^{1,2}. There are infrequent reports of plasmodium vivax presenting with neurological features in adults and few of them in children^{3,4,5,6,7}. There are rare case reports of falciparum malaria presenting as HS^{7,8} and few with p. vivax in adults^{9,10}. We are describing a case of plasmodium vivax infection in a 9 yr female child complicated by hemophagocytosis, jaundice and neurological features that resolved by antimalarial treatment.

Case Report

A 9- year female child presented to out-patient department of Lok Nayak Hospital, Delhi, India with history of high grade fever associated with chills and rigors and generalised headache for seven days. The parents noticed petechiae over the arms, legs and abdomen for one day and altered sensorium for eight hours. There were 3-4 episodes of non-bilious or non-projectile vomiting. This was not associated with any weight loss, frequent infections or bone pains. There was no history of contact with a case of tuberculosis. There was no history of seizures in this child. There was no history of any previous blood transfusions. Clinically, the child was in stupor. The vitals were maintained.

There was severe pallor, icterus and petechiae. This child had liver 5 cm below costal margin (span 8 cm) and spleen 6 cm along long axis. There was terminal neck rigidity. On investigation, Hb: 4.8%, TLC: 3200/cu mm, DLC: 55% polymorphs, 40% lymphocytes, 5% of eosinophils (normal for this geographic region), platelet count: 30,000/ mm³, peripheral smear was positive for ring forms and gametocytes of plasmodium vivax as shown in Fig 1.

Antigen test (OptiMAL) was positive for p. vivax and negative for p. falciparum. Blood cultures were sterile and widal titres were < 1:40. CSF was acellular with normal biochemistry and LATEX test negative for meningococcus. Dengue serology was negative. Liver function tests: Total Bilirubin = 3.8 mg/dl, ALT = 234 IU/L, AST = 428 IU/L and ALP = 580 IU/L. The serum was negative for anti HAV, HBsAg, anti HBc, anti HCV and anti HIV. Serum LDH was 890 IU/L (reference: 115-250 IU/L), ferritin level = 897 ng/ml (reference 15-332 ng/ml) and fasting triglyceride levels = 387 mg/dl (reference: 30-160 mg/dl). Prothrombin time was normal. The patient could not afford for fibrinogen levels and D-dimer assay. Bone marrow study was done and it showed hypercellular marrow, M:E=1:2 with normoblastic reaction. Histiocytes were increased in marrow with hemophagocytosis and brown pigment of p vivax as shown in Fig 2.

She did not have G6PD deficiency. The child was treated with standard dosage of chloroquine, fluids, ranitidine and metoclopramide. The sensorium improved

in 8 hours and child accepted diet by 12 hours. The counts repeated after 3 days showed an improvement with Hb: 8.3%, TLC: 6750/mm, platelet count: 1.4 lakhs/cu mm. Repeat smears were negative for *p. vivax*. Serum ferritin and LDH levels normalised during follow up. The child was discharged in a hemodynamically stable state with 14 days of primaquine.

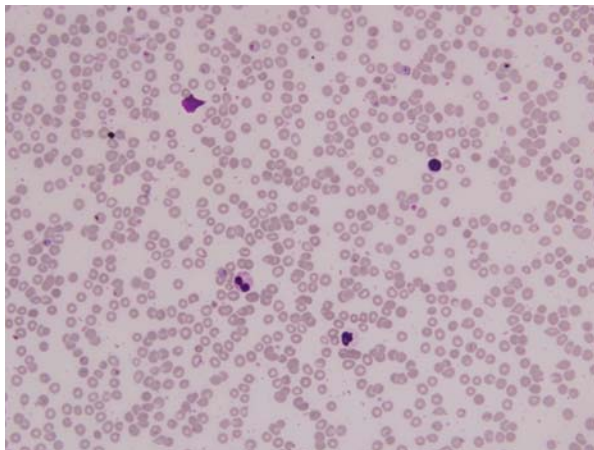


Fig 1: Showing ring forms of *p. vivax* in the peripheral smear of the patient.

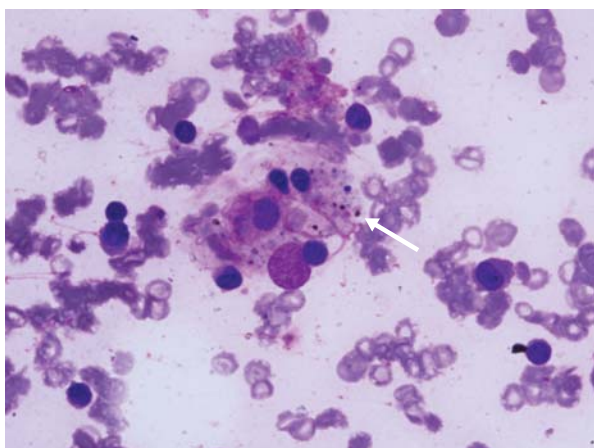


Fig 2: Bone marrow smear of patient showing hemophagocytosis and malarial pigment (arrow).

Discussion

There has been increasing reports of *p. vivax* in children during last few years causing several complications. There are 2 recent cases of *p. vivax* implicated in cerebral malaria³. Any patient infected with *p. vivax* exhibiting severe malaria should be presumed to be suffering from mixed infection^{3,4}. However, there are increasing reports *vivax* can present with both sequestration and non-sequestration related complications, which were commonly associated with *p. falciparum* infection⁶.

The patient in our case in addition to neurological features had pancytopenia as a result of

hemophagocytosis (marrow picture). In the marrow, there were increased histiocytes and phagocytosis of R.B.C., leukocytes and platelets. There is presence of malarial pigment in the cytoplasm. There was clinical jaundice with derranged liver functions. The mechanism of HS is not known, but high serum levels of cytokines (IL – 18, 1 α , TNF- α) have been reported in various studies. This has been studied in animal models and humans, that there is hyperactivity of TH1-cells and their mediated production of aforesaid cytokines^{11,12,13,14}. The levels of high TNF- α have been seen in cerebral malaria progressing to coma and death¹⁵. HS is one of the causes of pancytopenia in these infections. Bone marrow examination is not usually under-taken for the purpose of a diagnosis of malarial infection that may result in under diagnosis.

In various literatures, HS has been treated with prednisolone or plasma exchange^{7,8,16,17,18,19}. However, in our case, there was good clinical and haematological improvement with chloroquine alone. We recommend a marrow examination in malarial cases with severe or persistent decrease in haemoglobin or pancytopenia.

References

1. Imashuku S. Differential diagnosis of hemophagocytic syndrome: underlying disorders and selection of the most effective treatment. *Int J Hematol* 1997;66:135–151.
2. Fisman DN. Hemophagocytic syndromes and infection. *Emerg Infect Dis* 2000;6:601–608.
3. Ozen M, Gungor S, Atambay M, Daldal N. Cerebral malaria owing to *Plasmodium vivax*: case report. *Ann J Pediatr* 2006;26:141-144.
4. White NJ. Malaria. In: Cook GC, Zumla AI, eds. *Manson's Tropical Diseases*. 21st edn. London: Elsevier Saunders; 2002;1205-1278.
5. Sachdev H, Mohan M. *Vivax* cerebral malaria. *J Trop Pediatr* 1985;31:213-215.
6. Kochar D, Saxena V, Singh N, Kochar S, Kumar S, Das A. *Plasmodium vivax* malaria. *Emerg Infect Dis* 2005;11:132-134.
7. Thapa R, Patra V, Kundu R. *plasmodium vivax* cerebral malaria. *Indian Pediatr* 2007;433-434.
8. Sermet-Gaudelus I, Abadie V, Stambouli F, Hennequin C, Lenoir G, Gendrel D. Haemophagocytic syndrome in *plasmodium falciparum* malaria. *Acta Pediatr* 2000;89:368-369.

9. Ohnishi K, Mitsui K, Komiya N, Iwasaki N, Akashi A, Hamabe Y. Clinical case report: Falciparum malaria with hemophagocytosis syndrome. *Am J Trop Med Hyg* 2007;76(6):1016-1018.
10. Aouba A, Noguera M, Clauvel J, Quint L. Haemophagocytic syndrome associated with plasmodium vivax. *Br J Haematol* 2000;108:832-833.
11. Kwiatkowski D, Hill A, Sambou I, Twumasi P, Castracane J, Manogue et al. TNF concentration in fatal cerebral, non-fatal cerebral and uncomplicated Plasmodium falciparum malaria. *Lancet* 1990;336:1201-4.
12. Morris Jones MR, Goodier R, Langhorne J. The response of $\gamma\delta$ T cells to *Plasmodium falciparum* is dependent on activated CD4 T cells and the recognition of MHC class I molecules. *Immunology* 1996;89:405-12.
13. Clark LA, Chaudhri G. Tumor necrosis factor may contribute to the anemia of malaria by causing dyserythropoiesis and erythrophagocytosis. *Br J Haematol* 1988;70:99-103.
14. Takada H, Ohga S, Mizuno Y, Suminoe A, Matsuzaki A, Ihara K et al. Oversecretion of IL-18 in haemophagocytic lymphohistiocytosis: A novel marker of disease activity. *Br J Haematol* 1999;106:182-189.
15. Grau G, Taylor T, Molyneux M, Wirima J, Vassalli P, Hommel M, et al. Tumor necrosis factor and disease severity in children with falciparum malaria. *N Engl J Med* 1989;320:1586-91.
16. Koizumi K, Yokoyama K, Nishio M, Shibata S, Ozutumi K, Yamaguchi M et al. A case with virus-associated hemophagocytic syndrome (VAHS) complicated by rhabdomyolysis which were associated with herpes-simplex virus infection. *Jpn J Clin Hematol* 1996;37:40-45.
17. Fujiki R, Shiraishi K, Noda K, Ohshita Y, Fukahori S, Johjima H et al. A case of hemophagocytic syndrome associated with military tuberculosis. *Kekkaku* 2003;78(6):443-448.
18. Goto S, Aoike I, Shibasaki Y, Morita T, Miyazaki S, Shimizu T et al. A successfully treated case of disseminated tuberculosis-associated hemophagocytic syndrome and multiple organ dysfunction syndrome. *Am J Kid Dis* 2001;38:E19.
19. Sanada S, Ookawara S, Shindo T, Morino K, Ishikawa H, Suzuki M. A case report of the effect of plasma exchange on reactive hemophagocytic syndrome associated with Toxic shock syndrome. *Therap Aphre Dialy* 2004;8:503-506.

.....
How to cite this article ?

Ram Kumar TV, Baghmar S. Plasmodium Vivax Malaria Complicated by Neurological, Jaundice and Haemophagocytic Syndrome. *J Nep Paedtr Soc* 2010;30(3):168-170.
