

# Chylolymphatic Cyst - Presenting as Acute Intestinal Obstruction – A Case Report

Sunita Arora, Taranjeet Kaur, Harwinder Singh Rana

<sup>1</sup>Department of Paediatrics, Sri Guru Ram Das Institute of Medical Sciences & Research, Sri Amritsar, Punjab, India.

## Article History

Received On : Jul 28, 2021

Accepted On : Apr 05, 2022

**Funding sources:** None

**Conflict of Interest:** None

## Keywords:

Chylolymphatic cysts, Intestinal obstruction, Mesenteric cysts.

## Abstract

Chylolymphatic cyst is one of the rare variants of mesenteric cysts. These cysts are present within mesentery and contain chylous or lymphatic fluid. Chylolymphatic cysts are rare in paediatric age group. We present a case of a four years old boy who presented with features of acute intestinal obstruction. CECT abdomen revealed a hypodense cystic mass in the peritoneal cavity. Exploratory laparotomy of the abdomen revealed a solitary cyst measuring 10.7 cm x 9.4 cm x 10.5 cm which was adherent to the loops of small intestine and right kidney. Complete excision of cyst along with resection of the adjacent gut and end to end anastomosis was done. Histopathology of the excised cyst was suggestive of chylolymphatic cyst. It has been highlighted that chylolymphatic cyst can be a rare cause of intestinal obstruction in children.

## Introduction

Chylolymphatic cysts are benign proliferation of the lymphatic vessels which results from an obstruction in the lymphatic system. They account for approximately 3% to 9.2% of all paediatric lymphangiomas, although their exact incidence is unknown.<sup>1,2</sup> These lesions can present with symptoms such as abdominal pain, nausea, vomiting, anorexia and changes in the bowel habits. However, most of them are asymptomatic and are detected incidentally on physical examination or imaging. Occasionally, they can cause complications such as intestinal obstruction, volvulus or even torsion.<sup>3</sup>

## Case Report

Four years old boy was admitted with complaints of abdominal pain, vomiting, abdominal distension and constipation of three days duration. He had a history of recurrent abdominal pain associated with abdominal distension for last one month. Pain was intermittent, colicky and mild to moderate in intensity and was poorly localized. There was no history of passing blood or worms in stool. On clinical examination, child was under-nourished weighing 12 kg. Abdomen was distended, tense and tender with fullness of the right lower abdomen. An ill-defined lump measuring 10.5 cm x 11.5 cm was palpable in the right iliac and hypogastric region. Bowel sound was absent. Rest of systemic examination was normal. CBC, serum electrolytes, RFT were within normal limits. X-ray abdomen showed multiple air fluid levels suggestive of intestinal obstruction. USG of the abdomen revealed a solitary, cystic mass measuring 10 cm x 8 cm in the peritoneum on right side of abdomen with dilated loops of bowel. CECT abdomen was suggestive of hypodense cystic lesion with few thin enhancing internal septations in the peritoneum on right side of abdomen measuring 10.7 cm x 9.4 cm x 10.5 cm (Figure 1).

## Online Access



DOI: <https://doi.org/10.3126/jnps.v42i1.38679>

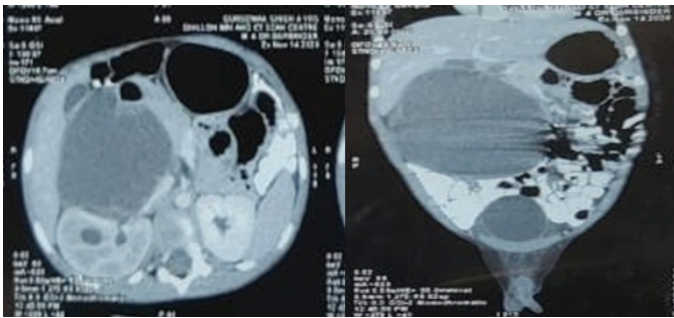
## \*Corresponding Author

Taranjeet kaur  
Department of Pediatrics,  
Sri Guru Ram Das Institute of Medical  
Sciences & Research,  
Sri Amritsar, Punjab, India.  
Email: drtaranjeet93@gmail.com

Copyrights & Licensing © 2022 by author(s). This is an Open Access article distributed under Creative Commons Attribution License (CC BY NC)



Figure 1: CECT abdomen showing mesenteric cyst.



Exploratory laparotomy revealed a solitary cyst measuring 10.7 cm x 9.4 cm x 10.5 cm which was adherent to loops of small intestine and right kidney. Complete excision of cyst along with gut resection and end to end anastomosis was done. Rest of the viscera were normal and there was no mesenteric lymphadenopathy. Intra peritoneal drain was inserted and abdomen was closed. The cyst was filled with chylous fluid. Histopathology of the excised cyst wall was suggestive of chylolympatic cyst (Figure 2).

Post-operative recovery was uneventful and patient was discharged.

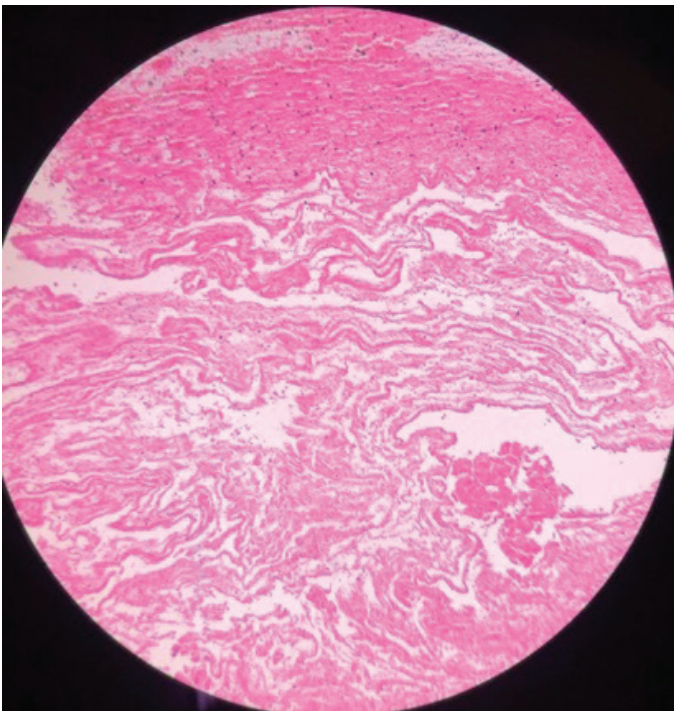


Figure 2: Histopathology of the cyst (section show presence of variable size vascular spaces lined by flattened cells with surrounding stromal tissue showing collagen and inflammatory infiltrate)

## Discussion

Chylolympatic cysts are rare variants of mesenteric cysts and constitute 7.3% to 9.5% of all abdominal cysts.<sup>4</sup> Mesenteric cysts are rare intra - abdominal tumor with prevalence of about 1:100,000 in adults and 1:20,000 in pediatric age group. They can occur in the mesentery of the gastrointestinal tract from the duodenum to the rectum but most commonly are localized in the mesentery of the small intestine, large intestine and retroperitoneum. They occur due to gross proliferation of ectopic lymphatics in mesentery that lack communication with rest of the lymphatic system. They can be single or multiple, unilocular or multilocular; can have serous, chylous, hemorrhagic or mixed fluid. Fluid can be serous when the cyst involves the distal small bowel or colonic mesentery and chylous when it is located in the proximal small bowel mesentery.<sup>5</sup> Mesenteric cysts have been classified based on etiology into: embryonic or developmental, traumatic or acquired, neoplastic or non-neoplastic and infective or degenerative by Beahrs et al.<sup>4</sup> Pathology classification includes type 1 (Pedicled) and type 2 (Sessile), which are limited to the mesentery, hence can be excised completely with or without resection of the involved gut. Type 3 and type 4 are multicentric. They require complex surgery and often sclerotherapy because of their extension into retroperitoneum. Mesenteric cyst can be divided into serous, chylous, hemorrhagic and chylolympatic cyst based on their contents.<sup>6</sup>

The chylolympatic cyst can contain both chyle and lymph which accumulate due to imbalance between the inflow and outflow of fluid.<sup>3</sup> Mesenteric cysts may present as asymptomatic abdominal mass or incidental finding on imaging or laparotomy for other abdominal conditions. Mesenteric cysts may cause acute abdomen from cyst rupture, infection, hemorrhage, intestinal obstruction, volvulus and obstruction of urinary or biliary tract. Histopathological examination is confirmatory and differentiates chylolympatic cysts from all the other lesions.<sup>7</sup> The preoperative diagnosis may be achieved with abdominal X-ray, ultrasonography and computed tomography. Plain X- ray abdomen may show gasless, homogenous mass displacing bowel loops. Multiple air fluid levels may be seen in erect film. Abdomen ultrasonography is the imaging procedure of choice. Ultrasonography usually demonstrates a cystic tumour.<sup>8</sup> A fluid filled level can be seen comprising of upper fluid level by lighter chyle over lower fluid level of heavier lymph.<sup>9</sup> CECT abdomen can show the relationship of the bowel and other vital structures to the lesion. Characteristic appearance shows fluid levels of differing echodensities, upper fatty echodensity of chyle on top of the water echodensity of lymph in a well - defined cystic lesion.<sup>9,10</sup> Differential diagnosis includes cystic lymphangioma, retroperitoneal cystic teratoma, caseating tubercular lymph nodes, hydatid cysts, lymphoma and duplication cysts. The different surgical approaches used are marsupialization, sclerotherapy, drainage, enucleation, percutaneous aspiration and excision of the cyst with or without resection of the involved gut.<sup>10</sup> Laproscopic approach is safe and feasible.

## Conclusions

Although a rare entity, chylolymphatic cyst should be considered in the differential diagnosis of cystic intraabdominal masses. Ultrasonography and computed tomography suggest the diagnosis but histopathological examination is required for confirmation. It can present with features of acute intestinal obstruction when it involves the mesentery of terminal ileum. Complete excision of the cyst yields excellent results. Bowel resection may be needed if involved by the cyst and may rarely need an ileostomy.

## References

1. Muramori K, Zaizen Y, Noguchi S. Abdominal lymphangioma in children: report of three cases. *Surg Today*. 2009;39(5):414-7. DOI: 10.1007/s00595-008-3854-z. PMID: 19408079.
2. Gümü ta OG, Sanal M, Güner O, Tümay V. Retroperitoneal cystic lymphangioma: a diagnostic and surgical challenge. *Case Rep Pediatr*. 2013;2013:292053. DOI: 10.1155/2013/292053.
3. Hardin WJ, Hardy JD. Mesenteric cysts. *Am J Surg*. 1970 Jun;119(6):640-5. PMID: 5445987. DOI: 10.1016/0002-9610(70)90232-1.
3. Engel S, Clagett OT, Harrison EG Jr. Chylous cysts of the abdomen. *Surgery*. 1961 Oct;50:593-9. PMID: 13890225.
4. Ricketts RR. Mesenteric and omental cysts. In: Grosfeld Jay L, O'Neill JA, Fonkalsrud EW, Coran AG, Caldamone AA (eds), *Pediatric Surgery*. Chapter 89. Mosby Inc. Ed 6th; 2006 (Vol II), pp 1399-1406. PMID: 21204665
5. Takiff H, Calabria R, Yin L, Stabile BE. Mesenteric cysts and intra-abdominal cystic lymphangiomas. *Arch Surg*. 1985 Nov;120(11):1266-9. DOI: 10.1001/archsurg.1985.01390350048010.
6. Rattan KN, Nair VJ, Pathak M, Kumar S. Pediatric chylolymphatic mesenteric cyst-a separate entity from cystic lymphangioma: a case series. *J Med Case Rep*. 2009 Dec;3(1):1-4. DOI: 10.1186/1752-1947-3-111
7. Sahin DA, Akbulut G, Saykol V, San O, Tokyol C, Dilek ON. Laparoscopic enucleation of mesenteric cyst: a case report. *Mt Sinai J Med*. 2006 Nov;73(7):1019-20. PMID: 17195889.
8. Fujita N, Noda Y, Kobayashi G, Kimura K, Watanabe H, Masu K, et al. Chylous cyst of the mesentery: US and CT diagnosis. *Abdom Imaging*. 1995 May-Jun;20(3):259-61. DOI: 10.1007/BF00200410.
9. Hebra A, Brown MF, McGeehin KM, Ross AJ. Mesenteric, omental, and retroperitoneal cysts in children: a clinical study of 22 cases. *South Med J*. 1993 Feb;86(2):173-6. DOI: 10.1097/00007611-199302000-00005.