

Neonatal Adenoviral Myocarditis – A Case Report and Review of Literature

Amrita Roy, Labanya Chowdhuri, Debadatta Mukhopadhyay and Alokanda Das Datta

Department of Paediatrics, Apollo Gleneagles Hospitals, Kolkata, India

Correspondence:

Amrita Roy
Neonatal Intensive Care Unit,
Department of Paediatrics,
Apollo Gleneagles Hospitals,
58 Canal Circular Road, Kolkata -700054,
Kolkata, West Bengal, India.
E-mail - preences.amri3107@gmail.com

DOI: 10.3126/jnps.v41i3.38138

Submitted on: 2020-08-06

Accepted on: 2021-02-26

Acknowledgements: parents of the neonate for providing consent, Neonatal ICU nursing staff at Apollo Gleneagles Hospital, Kolkata, West Bengal, India.

Funding: Nil

Conflict of Interest: None declared

Permission from IRB: Yes

To cite this article: Roy A, Chowdhuri L, Mukhopadhyay D, Datta AD. Neonatal Adenoviral Myocarditis – A Case Report and Review of Literature.. J Nepal Paediatr Soc. 2021;41(3):454-7.

ABSTRACT

Adenoviruses are DNA viruses that typically cause mild self-limited disease mostly involving the respiratory tract, gastrointestinal tract or conjunctiva. Typical respiratory symptoms include fever, pharyngitis, tonsillitis, cough, and sore throat but rare associations with severe disease such as myocarditis have been reported. Current treatment options are limited to usage of intravenous immunoglobulins (IVIGs) or antiviral agent Cidofovir, however usage of the latter is limited due to reports on drug induced adverse reactions. In this case report we describe an infant with severe myocarditis in whom Adenovirus was revealed to be the identifiable cause. The infant was treated with IVIG which is believed to act as an immunomodulatory agent. The infant recovered completely. Our conclusion is that patients with myocarditis caused by adenovirus are likely to benefit from early treatment with IVIGs.

Key-words: Cardiac viral infection; Intravenous Immunoglobulins; Myocarditis



This work is licensed under creative common attribution 3.0 license



INTRODUCTION

Human adenoviruses are double stranded non - enveloped DNA viruses of genus Mastadenovirus of the Adenoviridae family. Although adenovirus infection can occur at all ages, more than 80% of infection occurs among children less than four years age. Symptoms include fever, pharyngotonsillitis, disseminated infection, encephalitis, meningitis, myocarditis, cardiomyopathy, sudden infant death. Myocarditis is an uncommon diagnosis accounting for 0.05% of paediatric admissions according to a study done by Tunuguntla et al.¹ Treatment is mostly supportive. In this case report we describe a 28 day old male neonate with adenoviral myocarditis who was successfully treated with IVIG.

CASE REPORT

A 28 day old male neonate presented with poor feeding and respiratory difficulty for four days. On admission, baby was tachypneic (Respiratory rate = 80 / min), tachycardic (Heart rate = 180 / min) with audible grunting, subcostal and intercostal recessions, hepatomegaly (3 cm below right costal margin) and capillary refill time was prolonged. There was no history of rash. Mother had conjunctivitis and coryza. Baby was born by normal vaginal delivery at term with birth weight of 2.7 kg, had uneventful perinatal period and was exclusively breast-fed.

Initial arterial blood gas showed metabolic acidosis (pH = 7.17) with high lactate levels (13.30 mmol/L). An initial fluid bolus (10 ml/kg) with nasal continuous positive airway pressure was started. Empiric first line antibiotics were started after sending sepsis screen. Chest radiograph showed cardiomegaly with perihilar infiltrates. ECG showed low voltage QRS complexes. Respiratory distress gradually worsened and baby was to be intubated. Initial echocardiogram showed dilated left heart with ejection fraction (LVEF) of ~ 33% (Simpsons method) as shown in figure 1 and figure 2. Within 12 hours of admission, baby was hypotensive and was started on dopamine and milrinone.

Initial investigations showed high total leukocyte count (13900 / mm³ with 70% lymphocytes), c-

reactive protein and procalcitonin were negative. Blood for n-terminal pro b-type natriuretic peptide (NT-pro-BNP) was high (> 35000 pg/ml) and creatine phosphokinase-MB (CPK-MB) was high (338 U/L). Thyroid function and vitamin D₃ levels were normal. Nasopharyngeal swab for respiratory viral polymerase chain reaction (detects 12 viruses) was positive for adenovirus. Repeat echocardiography after 24 hours of admission showed LVEF~25%. IVIG was given at 1 gm/kg/day for two days along with escalating infusion of milrinone. As blood culture was sterile, IV antibiotics were stopped after 48 hours.

Echocardiography on fourth day of admission showed slightly improved EF~35%. Baby also improved clinically and was extubated to nasal prongs oxygen for next two days. Injection milrinone was gradually tapered off by day seven and enalapril tablet was added along with frusemide drops. Baby was discharged after ten days with LVEF 45%. On follow up after two weeks, LVEF had improved to ~ 58% with normalization of CPK-MB levels. At six months follow up cardiac function normalized with intact neurodevelopmental outcome.

DISCUSSION

Myocarditis, an inflammation of the myocardium, is characterized histologically by Dallas classification as “an inflammatory infiltrate of the myocardium with necrosis and / or degeneration of adjacent myocyte” or the WHO Marburg criterion as “≥ 14 infiltrating leucocytes / mm²”.² Majority of cases of myocarditis are due to viral etiologies like adenovirus 59%, enterovirus 35%, cytomegalovirus (CMV) 7%, parvovirus 2.5%, influenza A, herpes simplex virus type 1 (HSV 1) 2%, epstein barr virus (EBV) 1%, respiratory syncytial virus (RSV) 1%.² Due to patchy nature of the inflammatory infiltrate and difficulty in pathogen culture / isolation, identification of etiological agents can be difficult.

Although acute myocarditis is initiated by viral infection, subsequent myocardial damage is presumed to be autoimmune mediated.³ Ronchi et al reviewed 26 neonates who had adenoviral infection over 17 years. Of them, 88% had

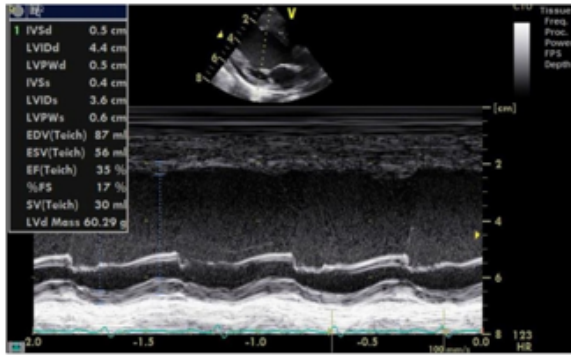


Figure 1. Parasternal Long axis view showing severe LV dysfunction (EF 35 %)+

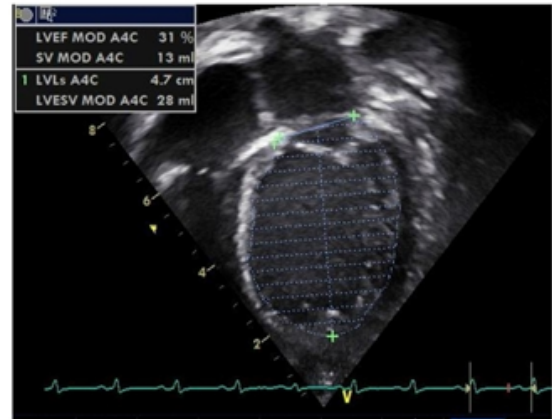


Figure 2. Severe LV dysfunction and dilation LVEF 31% (Simpsons method).

respiratory signs and 66% had temperature instability. Four (80%) of infants with disseminated disease have died. Ribavirin / cidofovir or IVIG did not improve outcomes except in one neonate. On literature review (n = 72), disseminated infection was associated with death (68% vs 21% with localized infection, $P < .001$).⁴ Drucker et al studied 46 children with acute myocarditis among which 45.7% were treated with high dose IVIG. Prednisone was given to 10.9% patients. Higher 12 months survival and earlier LVEF normalization was seen among IVIG treated patients. No adverse event was observed with IVIG administration.⁵

In a study by Freund et al, there was 31% mortality among the 35 neonates with enterovirus myocarditis and 66% of the survivors (16 / 24) developed severe cardiac sequelae thereafter. Eight babies were treated with pleconaril while four neonates received IVIG additionally. Extracorporeal membrane oxygenation (ECMO) support was given to four neonates and three of them died.⁶

In our patient, the timely usage of IVIG highlights the possibility of earlier recovery of left ventricular function in acute myocarditis. IVIG could possibly act by providing specific antibodies to viruses. It may modulate the immune response leading to decreased myocardial inflammation. It causes down- regulation of proinflammatory cytokines which have a negative inotropic effect from the generation of nitric oxide. IVIG engages the low affinity Fc gamma receptors and induces the

synthesis of IL-1 antagonist leading to down regulation of nitric oxide synthase.⁷

Ribavirin for RSV pneumonitis and ganciclovir and acyclovir for CMV disease have been used in transplanted patients. Benefits of IVIG are still inconclusive due to limited data. Paediatric Cardiomyopathy Registry (PCMR) study found that there was no association of corticosteroids or IVIG with survival or Left ventricle normalization.⁸ Similar result was obtained in a meta-analysis done by Yu Yen et al on role of IVIG on acute myocarditis.⁹ However, a study by Drucker et al showed an improvement in LVEF and improved survival outcome.⁵

Currently, treatment options for adenovirus infections are limited to Cidofovir with or without IVIG. Cidofovir usage is mostly restricted due to dose limiting nephrotoxicity commoner in neonates than paediatric.¹⁰ Thus, alternate drugs or adenoviral vaccines will result in decreased incidence of myocarditis and dilated cardiomyopathy, thereby decreasing neonatal cardiac transplantation and overall neonatal mortality.

CONCLUSIONS

In our patient the timely usage of IVIG highlights the possibility of earlier recovery of left ventricular function in acute myocarditis due to adenovirus. This entity should be kept in mind in any sick neonate with cardiovascular compromise.

REFERENCES

1. Tunuguntla H, Jeewa A, Denfield SW. Acute Myocarditis and Pericarditis in Children. *Pediatr Rev.* 2019 Jan;40(1):14-25. doi: 10.1542/pir.2018-0044. PMID: 30600275.
2. Dennert R, Crijns HJ, Heymans S. Acute viral myocarditis. *Eur Heart J.* 2008 Sep;29(17):2073-82. doi: 10.1093/eurheartj/ehn296. Epub 2008 Jul 9. PMID: 18617482; PMCID: PMC2519249.
3. Kishimoto C, Abelmann WH. In vivo significance of T cells in the development of Coxsackievirus B3 myocarditis in mice. Immature but antigen-specific T cells aggravate cardiac injury. *Circ Res.* 1990 Sep;67(3):589-98. DOI: 10.1161/01.res.67.3.589. PMID: 1697791.
4. Ronchi A, Doern C, Brock E, Pugni L, Sánchez PJ. Neonatal adenoviral infection: a seventeen year experience and review of the literature. *J Pediatr.* 2014 Mar; 164(3) : 529-35. e1-4. DOI: 10.1016/j.jpeds.2013.11.009.
5. Drucker NA, Colan SD, Lewis AB, Beiser AS, Wessel DL, Takahashi M, et al. Gamma-globulin treatment of acute myocarditis in the pediatric population. *Circulation.* 1994 Jan;89(1):252-7. DOI: 10.1161/01.cir.89.1.252.
6. Freund MW, Kleinveld G, Krediet TG, Van Loon AM, Verboon-Maciolek MA. Prognosis for neonates with enterovirus myocarditis. *Arch Dis Child Fetal Neonatal Ed.* 2010 May; 95(3):F206-12. DOI: 10.1136/adc.2009.165183.
7. Arend WP, Smith MF Jr, Janson RW, Joslin FG. IL-1 receptor antagonist and IL-1 beta production in human monocytes are regulated differently. *J Immunol.* 1991 Sep 1;147(5):1530-6. PMID: 1831827.
8. Foerster SR, Canter CE, Cinar A, Sleeper LA, Webber SA, Pahl E, et al. Ventricular remodeling and survival are more favorable for myocarditis than for idiopathic dilated cardiomyopathy in childhood: an outcomes study from the Pediatric Cardiomyopathy Registry. *Circulation: Heart Failure.* 2010 Nov;3(6):689-97. DOI: org/10.1161/CIRCHEARTFAILURE.109.902833.
9. Yen CY, Hung MC, Wong YC, Chang CY, Lai CC, Wu KG. Role of intravenous immunoglobulin therapy in the survival rate of pediatric patients with acute myocarditis: A systematic review and meta-analysis. *Sci Rep* 9, 10459 (2019). doi.org/10.1038/s41598-019-46888-0.
10. Vora SB, Brothers AW, Englund JA. Renal Toxicity in Pediatric Patients Receiving Cidofovir for the Treatment of Adenovirus Infection. *J Pediatric Infect Dis Soc.* 2017 Nov 24;6(4):399-402. DOI: 10.1093/jpids/pix011. PMID: 28419263.