

# De Novo Robertsonian Translocation t(21; 21) in a Child with Down Syndrome

Anil V Israni<sup>1</sup>, Anirban Mandal<sup>2</sup>

## Abstract

The phenotypic expression in DS is determined by the type of underlying cytogenetic abnormality. Almost 90-95% cases of DS are due to pure trisomy of the 21<sup>st</sup> chromosome; 6-7% is the result of mosaicism and in only 3-5% of cases it results from Robertsonian translocation (ROB). About 1/3<sup>rd</sup> cases of unbalanced Robertsonian translocation causing DS are inherited. We report a 1-year-old-boy with DS secondary to *rea*(21;21) ROB.

**Key words:** Aneuploidy, pre-conception genetic diagnosis, genetic counselling, trisomy

<sup>1</sup>Dr. Anil V Israni, MBBS, MD, MD, Consultant Paediatric Neurologist Department of Paediatrics, Maxcure Suyesha Woman and Child Hospital, Hyderabad, India, <sup>2</sup>Dr. Anirban Mandal, MBBS, MD, Department of Paediatrics, Sitaram Bhartia Institute of Science and Research, New Delhi, India.

## Address for correspondence

Dr. Anil V Israni  
E-mail: anilisrani@ymail.com

## Introduction

Aneuploidy is the most frequently observed chromosomal abnormality in humans with Down syndrome (DS) being the commonest autosomal aneuploidy. DS results from whole or part of third copy of chromosome 21. It is the commonest recognizable genetic cause of intellectual disability. Overall incidence of DS is 1 in 691 births but it varies widely influenced by advancing maternal age and differs between populations (1 in 300 to 1 in 1000 live births)<sup>1</sup>. The overall prevalence however, varies from 1 per 800-1,200 live births depending upon the acceptability and availability of prenatal screening, foetal survival and medical termination of Down syndrome pregnancies. Interestingly, the prevalence of DS is not related to race, nationality, religion or socioeconomic status<sup>2</sup>. The estimated incidence of DS in India is 1.4 per 1000 live births. With an expected birth of 26,00,000 new-borns in a year, the annual birth of DS babies is around 37,000 approximately<sup>3</sup>.

Almost 90-95% cases of DS are due to pure trisomy of the 21<sup>st</sup> chromosome; 6-7% is the result of mosaicism with varying percentage of normal and trisomy cells. In a small proportion (3-5%) of cases the extra chromosome 21 attaches itself to another acrocentric chromosome; this is known as Robertsonian translocation (ROB)<sup>2</sup>. These translocations are commonly balanced chromosomal rearrangements with an estimated incidence of 1 in 1000 making them the most common structural chromosomal abnormalities in the general population. The carriers of these translocations are usually phenotypically normal<sup>4</sup>. Although all human acrocentric chromosomes (chromosomes 13, 14, 15, 21, and 22) are capable of participating in ROB formation, *der*(13q14q) and *der*(14q21q) constitutes 85% of

## How to cite

Anil V Israni, Anirban Mandal. De Novo Robertsonian Translocation t(21; 21) in a Child with Down Syndrome. J Nepal Paediatr Soc 2017;37(1):92-94.

doi: <http://dx.doi.org/10.3126/jnps.v37i1.16184>

This work is licensed under a Creative Commons Attribution 3.0 License.



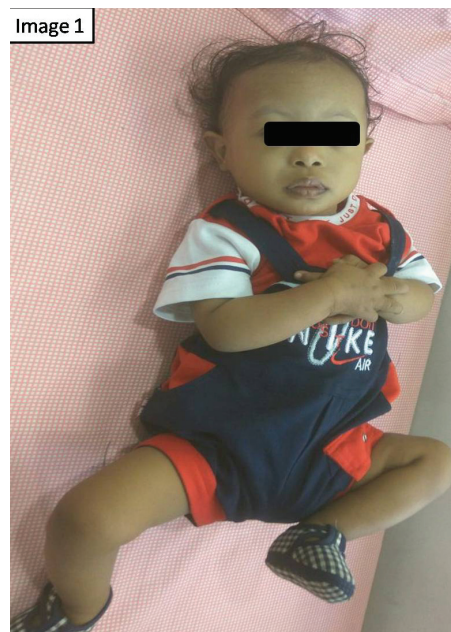all ROBs making others extremely rare<sup>4</sup>. This report describes a boy with DS due to a de novo  $rob(21;21)$  ROB.

## The Case

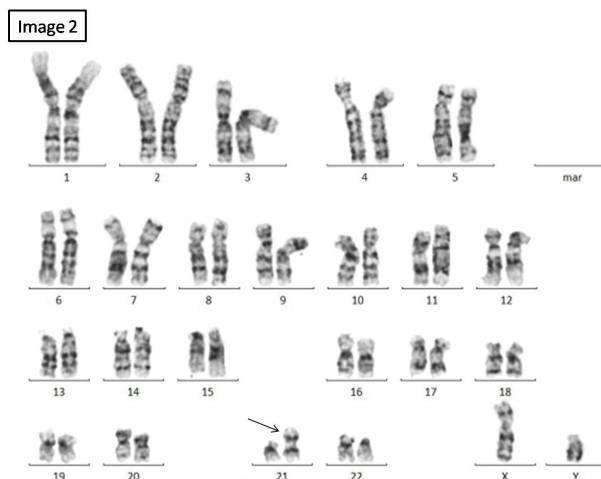
A one year old boy was brought with complaint of developmental delay. The child was second born to a 25 year old third gravida mother by normal vaginal delivery at term. He was a product of non-consanguineous marriage and his father aged 28 years. His mother conceived spontaneously and there were no antenatal or immediate perinatal concerns. The parents noticed a delay in achieving neck control even at six months of age. The child could only roll-over but was not able to sit, stand or even crawl. Pincer grasp was not attained till now. He started speaking bisyllables only since last one month. His hearing and vision was intact. There was no history of seizure, abnormal movements, frequent respiratory infections, or regression of any milestones. His mother had a previous first trimester spontaneous abortion and his only elder male sibling was healthy. There was no history of similar illness in the family. On examination, the child had flat occiput, flat facial profile, depressed nasal bridge, upward slant of palpebral fissures, large tongue, low set ears, short and broad hands and fingers, simian crease on palm and sandal gap (Figure 1). Developmental assessment was suggestive of global developmental delay with developmental age corresponding to approximately 6 months. Neurological examination was remarkable with generalized hypotonia but power and reflexes were normal. Examination of other systems was essentially normal. Thyroid profile and echocardiography were done to rule out associated hypothyroidism and structural heart defects respectively, and they were normal. Suspecting a diagnosis of Down syndrome (DS), karyotyping was ordered. It revealed  $46, XY, rob(21;21)(q10;q10), +21$  karyotype (Figure 2) confirming the diagnosis and also the responsible Robertsonian unbalanced translocation. The elder sibling was phenotypically normal. Genetic counselling of the parents was done along with karyotyping. Both parents' karyotype was normal, so this was a de novo  $rob(21;21)$  translocation in the child.

## Discussion

The phenotypic expression in DS is determined by the type of underlying cytogenetic abnormality. Those with mosaicism tend to have less typical characteristic features and also to function at a higher intellectual level compared to those with complete trisomy 21<sup>5</sup>. Prasher found that DS patients with translocation had less severe learning disability, less obesity and increased frequency of psychiatric disorders; however, they had significantly



**Fig 1:** Showing patient with flat facial profile, depressed nasal bridge, upward slant of palpebral fissures, low set ears, short and broad hands and fingers



**Fig 2:** Karyogram of the child showing a male karyotype with a derivative chromosome 21 formed as a result of Robertsonian translocation between two homologous chromosome 21 (arrow);  $46,XY, +21,rob(21;21)(q10;q10)$

poorer independent functioning skills and more maladaptive behaviors, possibly secondary to higher incidence of dementia and depression<sup>5</sup>. Our patient being only a year old, these functions were difficult to assess. Again, extra copy of Hsa21 gene is proposed to result in increased levels of expression of many genes encoded in chromosome 21 thereby producing varying degrees of DS phenotypes<sup>6</sup>.

The majority of heterologous ROB's are inherited from a carrier parent and the minority of them is formed de novo mainly in the stage of meiosis I of oogenesis, whereas almost all homologous ROB's form de novo mitotically<sup>4</sup>. About 2/3<sup>rd</sup> cases of unbalanced Robertsonian translocation causing DS are de novo, while the rest are inherited. Therefore, the presence of an unbalanced translocation in a child with DS warrants parental chromosome analysis to rule out balanced translocation<sup>2</sup>. The parents of our patient did not carry such translocations. The importance of determining whether a translocation is either de novo or inherited from either parent lies in its possibility of recurrence in subsequent pregnancies for "at risk" couples and thus forms the cornerstone in genetic counselling. For de novo translocations the recurrence risk in future pregnancies for is low (overall 1 %) which is similar to complete trisomy 21. On the other hand, for familial translocations, the recurrence risk varies between 1-15% depending upon the type of translocation and whether the mother or the father is the carrier; but for

t(21; 21) the risk is 100% for both male and female carriers<sup>2</sup>.

Interestingly, Herve et al<sup>7</sup> have reported a case of recurrent trisomy 21 caused by an isochromosome 21q {i(21q)} very likely secondary to a maternal germline cell mosaicism. They hypothesize that vast majority of apparently de novo cases of rea(21;21) may be due to an i(21q) with maternal or paternal inheritance. It is also suggested to perform DNA microsatellite marker analysis in cases of rea(21;21) as conventional cytogenetic analysis is unable to distinguish between rob(21;21) and i(21q)<sup>8</sup>.

## Conclusion

The risk of recurrence of Down syndrome for a couple varies with the underlying translocation. Especially, in a case of Robertsonian translocation, it is necessary to perform karyotyping of both parents before genetic counselling.

## References

- O'Nualláin S, Flanagan O, Raffat I, Avalos G, Dineen B. The prevalence of Down syndrome in County Galway. *Ir Med J* 2007;100(1):329-31.
- Agarwal Gupta N, Kabra M. Diagnosis and management of Down syndrome. *Indian J Pediatr* 2014;81(6):560-7. DOI: 10.1007/s12098-013-1249-7.
- Sharma R. Birth defects in India: Hidden truth, need for urgent attention. *Indian J Hum Genet* 2013;19(2):125-129. DOI: 10.4103/0971-6866.116101.
- Zhao WW, Wu M, Chen F, Jiang S, Su H, Liang J, et al. Robertsonian translocations: an overview of 872 Robertsonian translocations identified in a diagnostic laboratory in China. *PLoS One* 2015;10(5):e0122647. DOI: 10.1371/journal.pone.0122647.
- Prasher VP. Comparison of physical and psychiatric status in individuals with translocation and trisomy 21 Down syndrome. *Downs Syndr Res Pract* 1995;3(1):9-13. DOI:10.3104/reports.45.
- AitYahya-Graison E, Aubert J, Dauphinot L, Rivals I, Prieur M, Golfier G, et al. Classification of human chromosome 21 gene-expression variations in Down syndrome: impact on disease phenotypes. *Am J Hum Genet* 2007;81(3):475-91. DOI: 10.1086/520000.
- Hervé B, Quibel T, Taieb S, Ruiz M, Molina-Gomes D, Vialard F. Are de novo rea(21;21) chromosomes really de novo? *Clin Case Rep* 2015;3(10):786-9. DOI: 10.1002/ccr3.341.
- Kovaleva NV, Shaffer LG. Underascertainment of mosaic carriers of balanced homologous acrocentric translocations and isochromosomes. *Am J Med Genet A*. 2003 Aug 30;121A(2):180-7. DOI: 10.1002/ajmg.a.20156.