

# Isolated Unilateral Left Upper Lobe Agenesis Causing Recurrent Pneumonia

Agrawal J<sup>1</sup>, Gupta M<sup>2</sup>

## Abstract

Lung agenesis is a rare developmental anomaly. It can range from total bronchial and parenchymal agenesis to mild pulmonary parenchymal hypoplasia of one or both lungs. A case of lobar agenesis of the left upper lung in a three month old girl causing recurrent chest infection is presented.

**Key words:** Lung Agenesis

## Introduction

The development of the lung follows the pattern of a tubular-acinous ductal system. Disturbance of the developing pulmonary anlage in early embryonic life may give rise to some uncommon anomalies like pulmonary agenesis or in very rare occasions, atresia of a segment of respiratory tract associated with development of normal pulmonary tissue distal to the atresia<sup>1</sup>. Developmental anomalies of the lung are usually detected in the neonatal period and in early childhood. Lung agenesis, a rare congenital anomaly, is sometimes associated with multiple congenital anomalies<sup>2</sup>. We report a case of isolated unilateral left upper lobe agenesis causing recurrent pneumonia in a three month old child.

## The Case

A girl with low birth-weight (2000g) was born uneventfully to a healthy mother at term gestation. Her two siblings were asymptomatic. The perinatal history was normal. No parental consanguinity was present. She had recurrent chest infection and was admitted and managed twice before at BPKIHS for pneumonia. This time she presented at three month of age with high grade fever, cough and difficulty in breathing for four days.

On admission at BPKIHS, she was conscious but irritable, weighing three kilograms with length 50cm. she was not pale, afebrile without cyanosis with regular pulse rate of 132 beats per minute. She was in severe respiratory distress having stridor with diminished movements over left side of chest. Auscultation showed no breath sound over interscapular and left supra-scapular region with coarse crackles over left infra-scapular region and right upper lobe. Cardiovascular and rest of the examination was unremarkable.

<sup>1</sup>Dr. Jyoti Agrawal, Department of Paediatrics and Adolescent Medicine, <sup>2</sup>Dr. Mukesh Gupta, Department of Radiodiagnosis and Imaging. Both from the BP Koirala Institute of Health Sciences, Dharan, Nepal.

## Address for correspondence:

Dr. Jyoti Agrawal  
E-mail: jyoti\_doctor@yahoo.com

## How to cite

Agrawal J, Gupta M. Isolated Unilateral Left Upper Lobe Agenesis Causing Recurrent Pneumonia. J Nepal Paediatr Soc 2015;35(2):175-176.

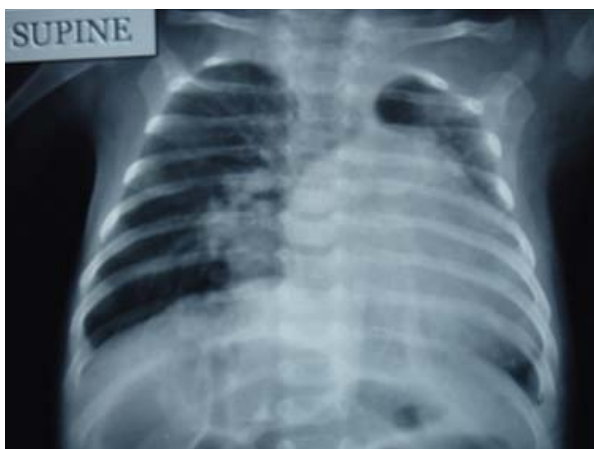doi: <http://dx.doi.org/10.3126/jnps.v35i2.13307>

This work is licensed under a Creative Commons Attribution 3.0 License.

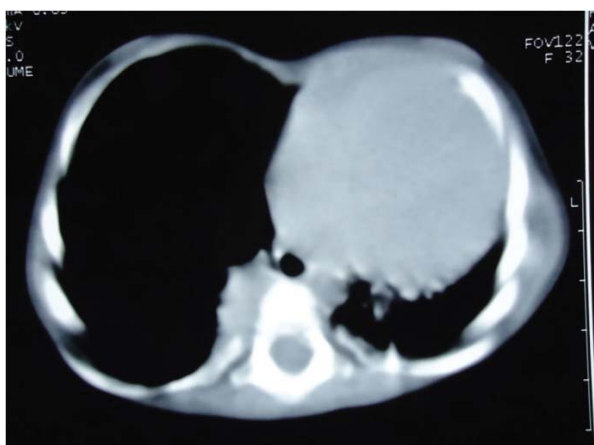


Her investigations read hemoglobin 10.5gm/dl, total leukocyte count was 21800/cmm, with normal readings of routine urine analysis, platelet count, and hepatic and renal function tests. Chest radiograph showed hyperinflation of right lung with opacified left upper and lower lung fields (Fig-1). Echocardiographic examination showed dextroposition of the heart with no other cardiac anomaly. Ultrasound abdomen, X-rays of hands, face, spine, pelvis and lower limbs were normal. Because of the suspected left lung agenesis, chest computed tomography was performed which confirmed left upper lobe agenesis with hyperinflation of left lower lobe and right lung field with segmental

consolidation of bilateral lower lobes (Fig-2). She was managed conservatively in our centre and was discharged. After which she is on regular follow up and doing well.



**Fig 1:** Showing complete opacification of left hemithorax with hyperinflation of right lung.



**Fig 2:** Showing upper lobe agenesis with hyperinflation of left lower lobe and right lung field

### Discussion

Pulmonary agenesis usually presents in childhood but may present in later life. If not complicated by other anomalies it is quite compatible with normal living. The diagnosis may be suspected on chest radiography; in rare cases, however, it may be associated with cross ectopic lung, which may cause misinterpretation of chest radiography<sup>3</sup>. Chest computed tomography is therefore necessary for definitive diagnosis. There have been some reports of combination of lung agenesis and complex congenital heart disease like of tricuspid atresia and severe right ventricular hypoplasia for which operations to establish single-ventricle circulation

physiology may be feasible<sup>4</sup>. Pulmonary agenesis needs to be differentiated from pulmonary hypoplasia by the absence of bronchial tree on bronchoscopy and the absence of lung tissue on radiological investigations<sup>5</sup>. The condition is asymptomatic unless compromised by infection, which can be bacterial like in our case or even mycobacterial. Differential diagnosis is from atelectasis, diaphragmatic hernia which can be differentiated with the help of tomography (HRCT), bronchography, and angiography<sup>6</sup>. Asymptomatic cases do not require any treatment especially when no other anomalies are present. Chest infections are to be treated energetically. These cases are high-risk cases for any surgery because of low respiratory reserve and anesthetist and surgeon should take appropriate precautions<sup>6</sup>.

### Conclusion

In the children presenting with recurrent chest infection and abnormal chest radiograph, a congenital malformation of lung may be considered in the differential diagnosis.

### References

1. Carmel JA, Friedman F, Adams FH. Fetal tracheal ligation and lung development. *Am J Dis Child* 1965;109:452.
2. Gabarre JA, Galindo Izquierdo A, Rasero Ponferrada M, Orbea Gallardo C, Puente Agueda JM, de la Fuente Pérez P. Isolated unilateral pulmonary agenesis: early prenatal diagnosis and long-term follow-up. *J Ultrasound Med* 2005;24:8656-8.
3. Chen SJ, Li YW, Wu MH, Wang JK, Hsu JC, Lue HC. Crossed ectopic left lung with fusion to the right lung: a variant of horseshoe lung? *Am J Roentgenol* 1997;168:1347-48.
4. Chiang LL, Chiu SN, Huang SC, Chen SJ. Unilateral left lung agenesis with crossed-ectopic right lower lobe combined tricuspid atresia diagnosed by ECG gated computed tomography. *J Thorac Cardiovasc Surg* 2010;139:e110-1.
5. Landing BH, Dixon LG. Congenital malformations and genetic disorders of respiratory tract (larynx, trachea, bronchi and lungs). *Am Rev Resp Dis* 1979;120:151-85.
6. Thangjam N, Desai N, Menon RK, Gupta GK, Mukhopadhyaya S, Srivastava S, et al. Unilateral pulmonary agenesis with skeletal anomalies. *Indian Pediatr* 1983;20:775-79.