

Gall Bladder Perforation by Typhoid Complication

Bhandari RS,¹ Singh KP²

¹Department of surgery, T U Teaching Hospital, Kathmandu, Nepal

ABSTRACT

Surgical complications of typhoid fever are uncommon and usually when it occurs, it commonly involves gut than the gallbladder. We present a case report of 20 years old gentleman who presented with ten days duration of fever and one day history of sudden severe generalized pain abdomen. Patient was evaluated and investigated and undergone laparotomy in the line of peritonitis. Operative finding was gallbladder perforation and he underwent cholecystectomy. Other investigations were supportive of typhoid fever. Patient improved and was discharged after seven days.

Key words: gallbladder, perforation, typhoid

INTRODUCTION

Typhoid fever is a common infection in the tropics and a common cause of intestinal perforation, resulting in high morbidity and mortality.¹ Among various complication of typhoid fever, acute cholecystitis is rare one, while perforation of gall bladder is extremely uncommon and dreaded complication.² Surgical complications of typhoid more commonly involve the gut than the gallbladder and commoner than those of parathyroid fever.³

CASE REPORT

We report a case of 20 year male who with history of fever for 10 days. Fever was high grade, continuous without chills and rigor. Initially he had mild to moderate abdominal discomfort but one day prior to admission he developed severe generalized pain abdomen which was exacerbated by movements suggesting peritonism. Pain was associated with multiple episodes of vomiting. He denied any history of drug abuse, alcoholism, and jaundice. There was no history suggestive of

recurrent biliary colic or chronic cholecystitis in the past. On examination, patient was very toxic looking with tachycardia, tachypnea and was febrile. Blood pressure was maintained. Abdomen was distended, rigid with tenderness and rebound tenderness all over the abdomen. Bowel sound was absent. Investigation revealed leucocytosis. X Ray chest couldn't reveal gas under the dome of diaphragm to support bowel perforation as a complication of typhoid fever. USG abdomen revealed gross fluid collection in the peritoneal cavity with mild splenomegaly. On the background of history, examination finding and USG finding, provisional diagnosis of typhoid fever induced small bowel perforation was made. Patient was resuscitated and planned for laparotomy after necessary preoperative preparation.

Patient underwent midline laparotomy. On opening the abdomen almost around 2 liters of clear bilious fluid was sucked out. Full evaluation of the bowel loops and other parts of the gastrointestinal tract was done to find out the site of perforation. While evaluating the duodenum,

Correspondence: Dr. Ramesh Singh Bhandari, Department of surgery, TUTH, Maharajgunj, Kathmandu, Nepal. Phone: 9841270203, E-mail: rameshbhandari2000@yahoo.com

we could see grossly inflamed gallbladder with a small perforation of around 0.5cmX 0.5cm perforation near the fundus. (Figure 1, 2). After thorough evaluation of the peritoneal cavity, it was confirmed that the primary pathology leading to peritonitis was gallbladder perforation. Cholecystectomy was performed. Postoperative period was uneventful. Patient received complete course of Antibiotics. In the mean time reports of Widal test was available which was strongly positive for type O and S typhi. But blood and bile couldn't grow any organism in culture. Patient was discharged on tenth postoperative day.

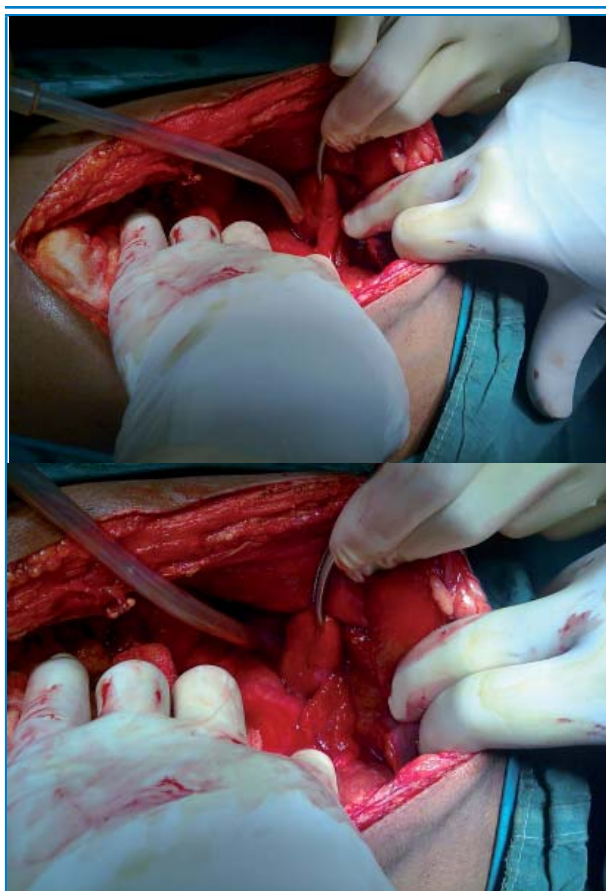


Figure 1, 2. Showing Gallbladder perforation and cholecystectomy being done.

DISCUSSION

Perforation of gallbladder was first noticed by J Duncan of royal Infirmary Edinburgh (quoted Gonsalves in 1979) about 135 years ago.⁴ Perforation occurs in the presence of gallstone disease with incidence varying 5- 12%. Typhoid fever is also occasionally known to cause gallbladder perforation in the absence gallstone disease.⁵

Typhoid cholecystitis usually present in the first week of illness². Clinical features suggestive of gallbladder

perforation are nonspecific. Abdominal paracentesis may reveal bile stained ascetic fluid.⁶ X ray Chest may not show gas under the diaphragm, like in our case and hence they are not always helpful. In around 70% case Ultrasound may detect collapsed gallbladder and a perforation or defect in the gallbladder wall. It can Show free fluid or collection close to the gallbladder wall.⁷

A high index of suspicion is needed to diagnose the condition. Surgical options include cholecystectomy or cholecystostomy.² However cholecystectomy may be desirable to prevent the carrier state of typhoid fever.⁸ Perforation of gallbladder usually occurs due to inflammatory reaction and weakness of the wall in the course of disease.⁸ Histopathological examination of cholecystectomy specimens shows inflammatory changes in the gallbladder that were also seen in our case.

Gallbladder perforation due to typhoid fever is a well known entity but an unusual complication. Patient present with sudden onset of pain abdomen in the background history of fever usually of one to two weeks duration. Clinically it is difficult to predict the diagnosis as gut perforation is usually thought when patient present with such features. It is evident only when abdomen is explored. Usually cholecystectomy is indicated to prevent the carrier state and outcome is excellent most of the time.

REFERENCES

1. Ugwa BT, Yiltok SJ, Kidmas AT, Opaluwa AS. Typhoid intestinal perforation in north central Nigeria. *West Afr J med* 2005; 24:1-6.
2. Jaramillo Samaniego JG. Acalculous acute cholecystitis during the course of typhoid fever in children. *Rev Gastroenterol Peru* 2001; 21:36-41
3. Memon AA. Perforated gallbladder: A case report. *J Surg Pak* 2001; 6:37-8.
4. Gonsalves HJ. Spontaneous perforation of gallbladder due to acute noncalculus ulcerative cholecystitis. *J R Coll Surg Edinb* 1979; 24:159-61.
5. Sarda DK, Chaudhury N, Hetwar S. Gall bladder perforation in typhoid fever. *J Indian Assoc Pediatr Surg* 2003; 8:249-50.
6. Sharma SB, Gupta V, Sharma V. Spontaneous gall bladder perforation. A rare entity in infants. *Indian J Gastroenterol* 2004; 23:75-76.
7. Sood BP, Karla N, Gupta S et al. Role of sonography in the diagnosis of gall bladder perforation. *J Clin Ultrasound* 2002; 30:270-4.
8. Pandey A, Gangopadhy AN, Kumar V. Gall bladder perforation as a complication of typhoid fever. *Saudi J Gastroenterol* 2008; 14:213.