

Postoperative Analgesic Effect of Dexamethasone Added To Ropivacaine for Fascia Iliaca Compartment Block Following Femoral Fracture Surgeries

Sharma S¹, Baral P², Shah P³, Raymajhi A⁴

ABSTRACT

Introduction: Pain is associated with higher perioperative morbidity in fracture patients. Fascia iliaca compartment block is a simple, inexpensive, and effective method of analgesia for femoral fracture surgeries. Many adjuvants have been used with local anaesthetics to prolong post-operative analgesia. **Aims:** To assess the effects of dexamethasone as an adjuvant to fascia iliaca compartment block on prolongation of post-operative analgesia in patients undergoing femoral fracture surgeries. **Methods:** Seventy patients aged, 18-65 years with American Society of Anaesthesiologist-Physical Status I and II, undergoing femoral fracture surgery, were randomly assigned to two groups, n=35 each, who received standard subarachnoid block. Ultrasound guided Fascia iliaca compartment block was given after completion of surgery with 20ml of 0.35% ropivacaine + 2ml normal saline to group one or 20ml of 0.35% ropivacaine + 2ml dexamethasone(4mg/ml) to group 2. Total duration of analgesia and total rescue analgesic requirement in the first post operative day were noted after successful block. **Results:**The demographic information for the two groups was comparable. The duration of postoperative analgesia was prolonged in patients receiving dexamethasone adjuvant (541 ± 167 vs. 638± 165 mins, p = 0.018; Mean difference -97). Patients receiving dexamethasone adjuvant required significantly less postoperative rescue analgesics for the first 24 hours (tramadol 88 ± 32 vs 65 ± 23 mg, p = 0.001; Mean difference 23). **Conclusion:** Dexamethasone, added to Fascia Iliaca Compartment Block, as an adjuvant, significantly prolongs the postoperative analgesic effect thereby, reducing the need for rescue analgesic in the first postoperative day.

Keywords: Dexamethasone, Fascia Iliaca Compartment Block, Postoperative analgesia, Ropivacaine

Authors:

1. Dr. Sagun Sharma
2. Dr. Pankaj Baral
3. Dr. Parasmani Shah
4. Ms. Asmita Rayamajhi

¹Department of Anaesthesiology, Nepalgunj Medical College and Teaching Hospital, Banke, Nepal

²Department of Anesthesiology, Pokhara Academy of Health Sciences, Pokhara, Kaski, Nepal

³Department of Anesthesiology, Nobel Medical College and Teaching Hospital, Biratnagar, Nepal

⁴Kapilvastu Integrated Development Services (KIDS)

Address for Correspondence:

Dr. Sagun Sharma

Lecturer

Department of Anaesthesiology

Nepalgunj Medical College and Teaching Hospital

Kohalpur, Banke, Nepal

Email: sharmasagun001@gmail.com

INTRODUCTION

Pain is one of the important factors associated with higher perioperative morbidity in fracture patients.¹ Negative clinical outcomes associated with inadequately managed postoperative pain include atelectasis and pulmonary infection, tachycardia and hypertension, delayed normal process of healing, myocardial ischemia / infarct, cardiac failure, deep vein thrombosis, postoperative ileus, postoperative urinary retention and infection related complications in surgical patients.²⁻⁵ Postoperative pain relief can be achieved by various methods including parenteral NSAIDs, neuraxial local analgesics and narcotics, epidural analgesia, peripheral nerve block, wound infiltration and patient controlled IV analgesia

with opioids.¹ The fascia iliaca compartment block (FICB) is a simple, inexpensive, and effective method of analgesia for femoral shaft fracture.⁸ Compared to bupivacaine, ropivacaine, is less cardio/neurotoxic and produces more intense analgesia with lesser motor blockade.⁹ Many adjuvants like epinephrine, clonidine, opioids, ketamine, dexamethasone and dexmedetomidine have been used with local anaesthetics to prolong the post-operative analgesia.¹⁰ However, dexamethasone has been shown to be effective in a small number of preclinical¹¹ and clinical studies¹² hence, we designed this prospective, randomized double blinded study to investigate it's analgesic effects as an adjuvant to ropivacaine on FICB. The aim of this study was to assess the duration of post-

operative analgesic effect of dexamethasone as an adjunct to ropivacaine in FICB in patients undergoing open reduction and internal fixation for fracture femur under spinal anaesthesia.

METHODS

This is an analytical, prospective, hospital based study, which was carried out from December 2022 to October 2023 in Nepalgunj Medical College Teaching Hospital, a tertiary care hospital of western Nepal. A sample size of 35 was taken in each group, as in a previous study conducted by Baral et al.¹ After obtaining Institutional ethical committee approval and informed written consent from the patients, 70 patients were studied.

Inclusion Criteria: ASA grade I and II patients aged between 18 to 65 years who were planned for ORIF of fracture femur under spinal anaesthesia.

Exclusion Criteria: Patients not willing to participate, allergy to local anaesthetics, peripheral neuropathy, bleeding diathesis, inflammation or infection over injection site, morbid obesity, psychiatric disorders, polytrauma, use of other modes of anesthesia or analgesia besides spinal anesthesia

We enrolled a total of 70 patients. Based on the computer-generated random number sequence, patients were assigned to either group 1 or group 2. Group 1 patients received ropivacaine 0.35% 20 ml with normal saline 2ml and group 2 patients received ropivacaine 0.35% 20 ml with dexamethasone (4mg/ml) 2ml for Fascia Iliaca Compartment Block (FICB).¹ Ultrasound guidance was used for location of the site and injection of the drug. Sequentially numbered opaque white envelopes were used with study medication mentioned inside. The investigator observing and recording the outcome parameter as well as the patients were made unaware about the medication used in the study. The group allocation was revealed only after analysis of the data. All the patients were pre-medicated with tablet clonidine 0.1mg given orally the night before and in the morning of surgery. During the preoperative assessment, patients were explained and made familiar to Numeric Rating Scale (NRS) for pain in simple comprehensible language. On arrival to operation theatre, venous access was established on the dorsum of non-dominant hand with 18 Gintravenous (IV) cannula and Ringer's lactate solution was infused. Electrocardiogram, heart rate, oxygen saturation and non-invasive blood pressure were monitored in the operating table. Spinal anesthesia was conducted in sitting position using 3ml 0.5% hyperbaric bupivacaine. The level of sensory block was checked using sterile needle. Motor block was evaluated by grading the motor power of the muscles (0 to 5). After the completion of surgery, patients were given injection paracetamol 15mg/ kg, (not exceeding 1 gm) after the surgery and then every six hours postoperatively. Dressing of the surgical wound was done, thereafter, the patients were positioned supine. Then, the skin was disinfected and femoral artery, iliopsoas muscle and fascia iliaca were identified with linear transducer (13-16MHz) of a sonosite USG machine, positioned over the inguinal crease. The transducer was moved laterally to identify the sartorius

muscle. After a skin wheal was made, a short beveled 25G Quincke needle was inserted in-plane as it is easily available and affordable to the patient. As the needle eventually pierced through the fascia, a pop was felt and the fascia was seen to "snap" back on the ultrasound image. The block was performed by injecting the drug in 5ml aliquots. This time point was considered as zero hour for our study. NRS for pain were recorded at 0 h, 4 h, 8 h, 12 h and 24 h postoperatively.

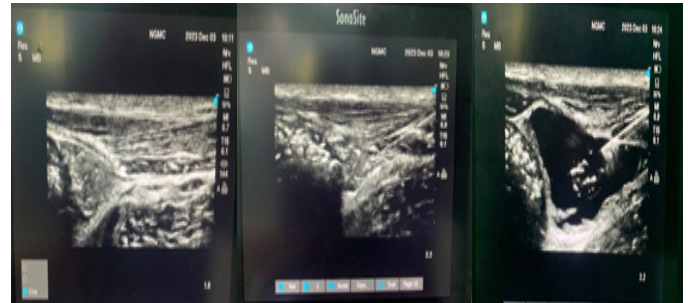


Figure 1: Ultrasound Image of front of the thigh at the level of groin crease, demonstrating the landmark, injection and drug deposition for FICB

Inj. tramadol 50mg IV was administered slowly when Numerical Rating Scale (NRS) was more than 3 (rescue analgesia). Inj. ondansetron 4mg IV was administered at the same time to offset nausea and vomiting caused by tramadol. The time between the block and the first analgesic request was recorded as the duration of analgesia. Total dose of rescue analgesic (tramadol) consumed in the postoperative period was recorded. Data was entered in excel and analysed using IBM SPSS Statistics Version 25. Comparison between the groups was done using the appropriate statistical test (Independent Sample T-test for normal distribution). Categorical data were presented as numbers with a percentage (%). Significance was assessed at a 5% level of significance. Appropriate graphs were used to visualize the findings.

RESULTS

The inclusion criteria were fulfilled by 70 patients, who completed the study (Figure 2). The demographic patient characteristics (age, gender, weight) were comparable between the groups. (Table I).

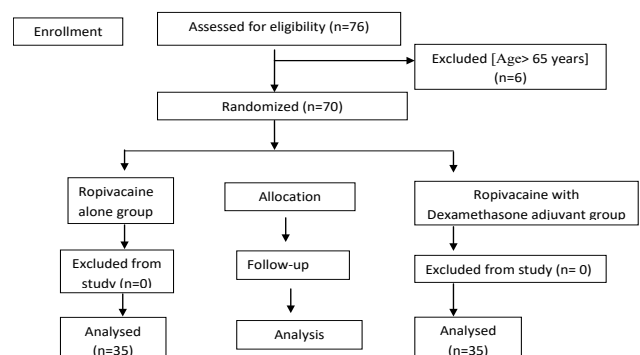


Figure 2: Flow diagram of the study

Characteristics	Group 1 (n=35) (Ropivacaine alone)	Group 2 (n=35) (Ropivacaine with Dexamethasone)	P value
Gender (M/F)	19/16	21/14	0.23
ASA-PS(I/II)	20/15	25/10	0.085
Age (yrs)	44.17 ± 15.947	43.06 ± 12.218	0.744
Weight (kg)	57.74 ± 9.847	58.69 ± 9.216	0.68
Duration of surgery in (min)	102.14 ± 22.139	103.14 ± 32.744	0.881

Table I: Baseline demographic patient characteristics, values represented as number as mean ± SD

The mean duration of analgesia with FICB was higher in group 2 as compared to group 1 with Mean difference being 96.72 minutes and the total dose of rescue analgesics (tramadol) required in the first postoperative 24 hrs was found to be lower in group 2 as compared to group 1 with the mean difference of 22.86 (Table II).

Parameter	Group 1 (n=35) (Ropivacaine alone)	Group 2 (n=35) (Ropivacaine with Dexamethasone)	P value
Duration of Analgesia	541.71 ± 167.573	638.43 ± 165.884	0.018*
Total Dose of Tramadol IV (mg)	88.57 ± 32.280	65.71 ± 23.550	0.001*

Table II: Duration of Analgesia and Total Dose of IV Tramadol (mg) as mean ± SD

The intensity of pain (Figure 3) remained statistically comparable at all observation time points between the groups (p value 0.9).

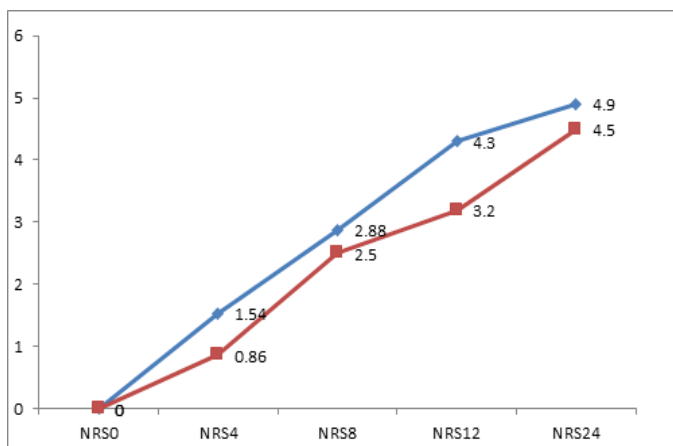


Figure 3: Mean NRS scores at different time interval

DISCUSSION

Femoral fractures are associated with a higher risk of perioperative morbidity,¹³ especially in geriatric patients. Pain has many undesirable effects on several physiological processes including pulmonary dysfunction, tachycardia and hyperten-

sion, negative effects on the immune system, and delayed wound healing.¹⁴ The frequent use of adequate parenteral analgesic is being reduced to these patients for fear of worsening intercurrent disease or of precipitating adverse effects.¹⁵ The field of regional anesthesia has evolved tremendously in the last 16 years.¹⁶ Regional anaesthesia and analgesia techniques are used to effectively manage acute pain after a variety of orthopedic surgeries.¹⁷ The fascia-iliaca compartment block(FICB), first described in 1989, is easy to perform and is associated with minimal risk as the analgesic is injected at a safe distance from the femoral artery and femoral nerve.¹² It is more effective in blocking lateral cutaneous nerve of thigh and femoral nerve.¹⁹ FICB is routinely used to provide analgesia following surgical procedures in the hip, femur, and knee, as well as treatment of burns on the thigh.^{8,18} FICB also prevents delirium, allows increased mobility and a shorter hospital stay.²⁰ Our study has shown that dexamethasone added to ropivacaine for FICB significantly prolongs the duration of analgesia by 96.71 minutes, following femoral fracture surgeries with reduced 24-hour postoperative analgesic requirement compared to ropivacaine alone. Similar result was obtained in a study done by Suresh et al, in which the duration of analgesia was significantly longer in group receiving dexamethasone as an adjuvant in FICB with reduced requirement of total doses of rescue analgesics. However, VAS scores during positioning for spinal anaesthesia were similar in both groups¹² as found in our study.

Similarly, study done by Acharya et al, revealed that dexamethasone, in a dose of 8 mg, was superior to 4mg when used as an adjuvant with levobupivacaine in the FICB. Both doses of dexamethasone prolonged analgesia and were effective in reducing oral/intravenous analgesics, with higher postoperative analgesic requirement (amount of tramadol in mg) in group receiving 4mg dexamethasone.²¹

Kumar J et al, too, concluded that, the addition of dexamethasone to FICB provided adequate postoperative analgesia with prolonged time to first analgesic requirement after femur fracture surgeries.²² Compared to clonidine, dexamethasone added to FICB had analgesia for a noticeably longer period of time, 11.2 ± 2.19 hours vs 12.44 ± 2.54 hours (p-value = 0.010). There was less consumption of rescue analgesics in dexamethasone group as compared to clonidine group which was statistically significant and there was significant difference noted in both groups in terms of mean VAS score at rest with mean difference of 0.94 (p value of 0.006) and during movement at 12 hours after surgery with mean difference of 0.62 (p value of 0.015).²⁷ Block prolongation was also observed when dexamethasone was combined with mepivacaine for supra-clavicular blocks²³ which was statistically significant with a p value of 0.008 in a study done by Parrington et al. Similarly, Cummings et al¹⁵ also noted that dexamethasone significantly prolonged the duration of ropivacaine and bupivacaine when used for the inter-scalene block.²⁴ More recent publications also suggest that 8mg dexamethasone added to perineural local anesthetic injections augments the duration of peripheral nerve block analgesia.²⁵ A systematic review by Choi et al demonstrated the beneficial effects of the addition of

dexamethasone to LA for peripheral nerve blocks too.²⁶ There are several theories to explain this effect of dexamethasone; Steroids induce a degree of vasoconstriction and thereby acting to reduce local anesthetic absorption. Secondly, it increases the inhibitory activity of potassium channels on pain sensory nerves. Another theory refers to anti-inflammatory action of dexamethasone and blocking the transmission of nociceptive C fibers.²⁵

Meanwhile, there was no statistically meaningful reduction in opioid consumption shown by pooled results of four trials yielding a point estimate of 14.7 mg less oral morphine equivalent (95% CI 238.0 to 8.6, P=0.22) in the use of opioids which reported opioid intake for up to 72 hours.²⁶ In all four trials, the duration of time at which opioid use was evaluated ranged from 24 hours to two weeks. The duration of analgesia was prolonged when dexamethasone was added to bupivacaine, according to a study by Vieira et al.²⁸ However, there was no additional assessment conducted on the degree of pain or the amount of analgesic medication used following surgery. The duration of analgesia and motor block were similarly affected by the addition of dexamethasone to lidocaine in a study by Movafegh et al, but no information about the degree of pain or the use of analgesics after surgery was provided.

LIMITATIONS

Patients above 65 years and those of ASA PS III or greater were excluded, though femur fractures are more common in these groups. Patient controlled analgesia for postoperative pain was not used which would be better for pain relief in these patients.

CONCLUSION

Our study concludes that, addition of dexamethasone to plain ropivacaine for FICB would significantly prolong postoperative analgesia and decrease the need of oral and iv analgesics in the postoperative period undergoing femoral fracture surgeries.

REFERENCES

1. Baral P, Ghimire A, Sah BP, Bhattarai B, Khatiwada S, Prasad JN. postoperative analgesic effect of morphine added to ropivacaine for fascia iliaca compartment block following femoral fracture surgeries: A Randomized Controlled Trial. *J BP Koirala Inst Heal Sci.* 2021;4(2):13–8.
2. Follin SL, Charland SL. Acute pain management: Operative or medical procedures and trauma. *Annals of Pharmacotherapy.* 1997;3(1):1068–76.
3. Breivik H, Hgstrm H, Niemi G, Stalder B, Hofer S, Fjellstad B, et al. 2 Safe and effective post-operative pain relief: introduction and continuous quality-improvement of comprehensive post-operative pain management programmes. *Baillieres Clin Anaesthesiol.* 1995;9(3):423–60.
4. Merskey H, Bogduk (Eds) N. Classification of chronic pain. Descriptions of chronic pain syndromes and definitions of pain terms. Prepared by the International Association for the Study of Pain, Subcommittee on Taxonomy. *Pain Suppl.* 1986;3:S1-226.
5. Strassels SA, McNicol E, Suleman R. Postoperative pain management: a practical review, part 2. *Am J Heal Pharm AJHP Off J Am Soc Heal Pharm.* 2005;62(19):2019–25.
6. Carr DB, Goudas LC. Acute pain. *Lancet.* 1999;353(9169):2051-8.
7. Ali M. Comparison of clonidine & dexamethasone as additive to bupivacaine in fascia iliaca compartment block for postoperative analgesia in patients undergoing lower limb orthopaedic surgery. *J Med Sci Clin Res.* 2019;7(5):120–6.
8. Lopez S, Gros T, Bernard N, Plasse C, Capdevila X. Fascia iliaca compartment block for femoral bone fractures in prehospital care. *Reg Anesth Pain Med.* 2003;28(3):203-207
9. Kuthiala G, Chaudhary G. Ropivacaine: A review of its pharmacology and clinical use. *Indian J Anaesth.* 2011;55(2):104–10.
10. Swain A, Nag DS, Sahu S, Samaddar DP. Adjuvants to local anesthetics: Current understanding and future trends. *World J Clin Cases.* 2017;5(8):307.
11. Colombo G, Padera R, Langer R, Kohane DS. Prolonged duration local anesthesia with lipid-protein-sugar particles containing bupivacaine and dexamethasone. *J Biomed Mater Res - Part A.* 2005;75(2):458–64.
12. Suresh Kumar N, Kiran N, Ravi M, Sebastian D, Punith Gowda RM. Dexamethasone as an additive to bupivacaine in fascia iliaca compartment block: A prospective, Randomized and double blind study. *J Clin Diagnostic Res.* 2014;8(8):5–8.
13. Soles GLS, Ferguson TA. Fragility fractures of the pelvis. *Curr Rev Musculoskelet Med.* 2012;5(3):222–8.
14. Desai PM. Pain management and pulmonary dysfunction. *Crit Care Clin [Internet].* 1999;15(1):151–66.
15. Finlayson BJ, Underhill TJ. Femoral nerve block for analgesia in fractures of the femoral neck. *Arch Emerg Med.* 1988;5(3):173–6.
16. Macías AA, Finneran JJ. Regional Anesthesia Techniques for Pain Management for Laparoscopic Surgery: a Review of the Current Literature. *Curr Pain Headache Rep.* 2022;26(1):33–42.
17. Eroglu A, Erturk E, Apan A, Eichenberger U, Cuvas Apan O. Regional anesthesia for postoperative pain control. *Biomed Res Int.* 2014;2014:2–3.
18. Candal-Couto JJ, McVie JL, Haslam N, Innes AR, Rushmer J. Pre-operative analgesia for patients with femoral neck fractures using a modified fascia iliaca block technique. *Injury.* 2005;36(4):505–10.
19. Morau D, Lopez S, Biboulet P, Bernard N, Amar J, Capdevila X. Comparison of continuous 3-in-1 and fascia iliaca compartment blocks for postoperative analgesia: Feasibility, catheter migration, distribution of sensory block, and analgesic efficacy. *Reg Anesth Pain Med.* 2003;28(4):309–14.
20. Mouzopoulos G, Vasiliadis G, Lasanianos N, Nikolaras G, Morakis E, Kaminaris M. Fascia iliaca block prophylaxis for hip fracture patients at risk for delirium: A randomized placebo-controlled study. *J Orthop Traumatol.* 2009;10(3):127–33.
21. Acharya R, Sriramka B, Panigrahi S. Comparison of 4 mg dexamethasone versus 8 mg dexamethasone as an adjuvant to levobupivacaine in fascia iliaca block - A prospective study.

Korean J Pain. 2018;31(4):261–7.

22. Kumar J V, Adithan J, B B. A Prospective comparative study of efficacy of bupivacaine alone or in combination with dexamethasone in fascia iliaca compartment block prior to subarachnoid block for fracture femur surgeries. *Indian J Anesth Analg.* 2019;6(2):2212–8.
23. Parrington SJ, O'Donnell D, Chan VWS, Brown-Shreves D, Subramanyam R, Qu M, et al. Dexamethasone added to ropivacaine prolongs the duration of analgesia after supraclavicular brachial plexus blockade. *Reg Anesth Pain Med.* 2010;35(5):422–6.
24. Cummings KC, Napierkowski DE, Parra-Sanchez I, Kurz A, Dalton JE, Brems JJ, et al. Effect of dexamethasone on the duration of interscalene nerve blocks with ropivacaine or bupivacaine. *Br J Anaesth.* 2011;107(3):446–53.
25. Yaghoobi S, Seddighi M, Yazdi Z, Ghafouri R, Khezri MB. Comparison of postoperative analgesic effect of dexamethasone and fentanyl added to lidocaine through axillary block in forearm fracture. *Pain Res Treat.* 2013;2013.
26. Choi S, Rodseth R, McCartney CJL. Effects of dexamethasone as a local anaesthetic adjuvant for brachial plexus block: A systematic review and meta-analysis of randomized trials. *Br J Anaesth.* 2014;112(3):427–39.
27. Ali M. Comparison of clonidine & dexamethasone as additive to bupivacaine in fascia iliaca compartment block for postoperative analgesia in patients undergoing lower limb orthopaedic surgery. *J Med Sci Clin Res.* 2019;7(5):120–6.
28. P. A. Vieira, I. Pulai, G. C. Tsao, P. Manikantan, B. Kelle, and N. R. Connelly, "Dexamethasone with bupivacaine increases duration of analgesia in ultrasound-guided interscalene brachial plexus blockade," *European Journal of Anaesthesiology.* 2010;27(3):285–288. 2015;27(3):158–62. DOI: 10.5455/msm.2015.27.158-162