

A Rare Incidence of Poland's Syndrome in a Female Child: A Case Report

Bist A¹, Bhandari N¹, Kanodia P², Chaulagain P³

ABSTRACT

Poland's syndrome is a rare condition characterized by the underdevelopment or absence of chest muscles on one side of the body and malformation of the hand and arm. This condition affects males more frequently than females and its cause is still unknown. The diagnosis is usually made in childhood, but in some cases, it may not be evident until adolescence or adulthood. Treatment options include surgical reconstruction and prosthetic devices to improve arm and hand function and appearance. While this syndrome can have a significant impact on a person's physical and emotional well-being, early intervention and appropriate management can lead to improved quality of life. In our case it was an accidental finding in a 7 months old female with severe pneumonia for whom conservative management was done. We are interested in reporting this case because of its rare presentation, so cases would not get missed by the treating clinician.

Keywords: Musculo-skeletal anomalies, Pectoralis muscle, Poland Syndrome

Authors:

1. Dr. Aayush Bist
2. Dr. Nirajan Bhandari
3. Prof. Dr. Piush Kanodia
4. Dr. Pratima Chaulagain

¹Nepalgunj Medical College and Teaching Hospital, Kohalpur, Banke, Nepal

²Department of Pediatrics, Nepalgunj Medical College and Teaching Hospital, Nepalgunj, Banke, Nepal

³Gandaki Medical College and Teaching Hospital, Pokhara, Kaski, Nepal

Address for Correspondence:

Dr. Aayush Bist
Nepalgunj Medical College and Teaching Hospital
Kohalpur, Banke, Nepal
Email : bist.aayush001@gmail.com

INTRODUCTION

Poland Syndrome is a rare condition characterized by the absence of chest wall muscles and abnormally short, webbed fingers on one side of the body.¹ Studies have proposed three theories for its etiology: genetic, teratogenic, or fetal vascular compromise. Subclavian artery supply disruption sequence occurring around 7 to 8 weeks of gestation is reported to cause unilateral visceral hypoplasia.² A 2:1 to 3:1 ratio affects men more frequently. The right side of the body was involved in 60% to 75% of patients, bilateral involvement occurring in less than 1% of cases.³ It manifests itself in a variety of ways; Type-1 (minimal form) refers an isolated pectoral muscle defect, type-2 (partial form) refers a pectoral muscle defect associated with either an upper limb (2a, upper limb variant), or a rib (2b, thoracic variant) anomaly, and type-3 (complete form) refers a pectoral muscle defect with both upper limb and rib anomalies.⁴

CASE PRESENTATION

A 7-month-old girl from Ghorahi-11, Dang, presented to the pediatrics department at Nepalgunj Medical College Teaching

Hospital, Nepalgunj with chief complaints of fever and cough for 10 days and fast breathing for 3 days, which was associated with chest subcostal indrawing, nasal flaring, and grunting. The final diagnosis was severe pneumonia. There was no past history of a similar illness. On examination, the patient appeared to be conscious, ill-looking, mildly dehydrated, and crying. There was no pallor, icterus, lymphadenopathy, cyanosis, clubbing, edema. She had fever (101.2°F), a pulse rate of 164 beats per minute, and a respiratory rate of 44 breaths per minute. Physical examination on inspection showed chest asymmetry with right anterior chest wall depression in the 2-4 intercostal space with the absence of a nipple (figure 1).

On palpation, ribs were present, but costal cartilage and a portion of the pectoralis major muscle were not. On auscultation, there was decreased air entry in the right middle and lower zones, as well as bilateral crepitations. Hand examination revealed no signs of digital abnormality, and no other musculoskeletal anomalies were discovered throughout the body. WBC count increased to 14,000 cells/cumm, and CRP was 19.49 mg/dL. The X-ray shows a hyper-translucent right-sided hemithorax with rib crowding (figure 2). On ultrasound, the absence of corresponding costal cartilage and intercostal

muscle was confirmed. The CT scan revealed that the pectoralis major, minor, and serratus anterior on the right side were completely invisible. The pectoralis major, minor, and serratus anterior muscles on the left side of the thoracic spine were all normal. We present a case of Poland syndrome in an infant female, emphasizing the fact that Poland syndrome can manifest without classic hand deformity.

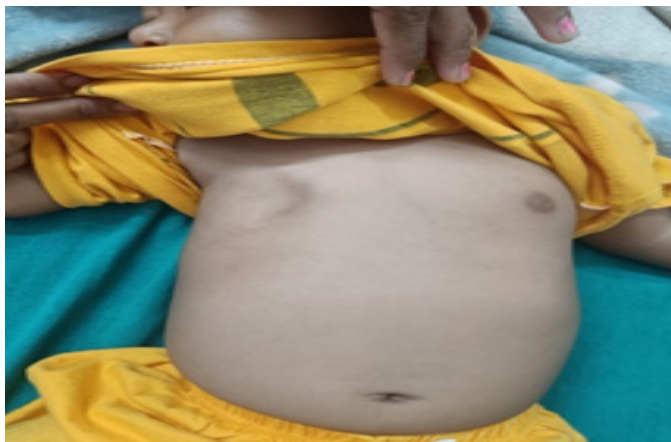

Figure 1: Anterior chest wall

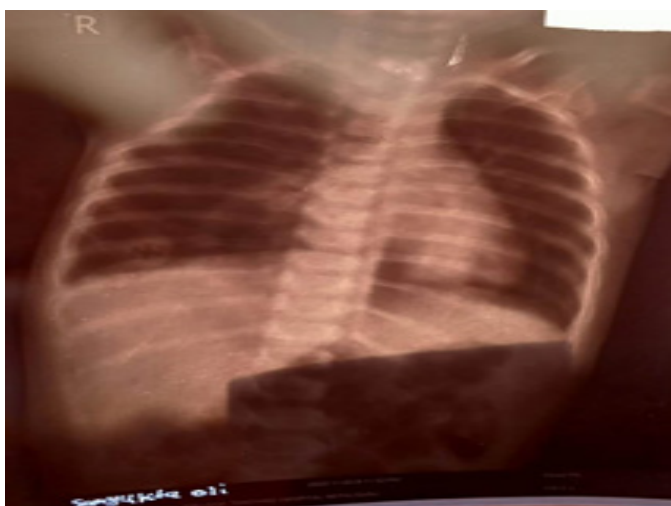


Figure 2: X-ray Chest

DISCUSSION

Poland syndrome (PS) are rarely reported in our setting and documented. The risk factor for Poland syndrome is hypothesized as in utero exposure of drugs like thalidomide, aspirin, cocaine or tobacco.⁵ Previous history of threatened abortions in first trimester is also found associated with Poland syndrome in subsequent birth. Poland syndrome can also be found in association with other anomalies as visceral defects like renal agenesis, hernia, blood dyscrasias like leukemias, and dermatological condition like congenital hemangioma, psoriasis vulgaris, cutaneous diffuse neurofibroma, café-au-lait spots. Some study highlights association of Poland syndrome with malignancy like Leukemia

and carcinoma of the hypoplastic breast and other tumors.⁶ In very cases, it can present with obvious scoliosis, rib and sternum deformity, which causes cardiopulmonary symptoms such as shortness of breath or difficulty of breathing.

The ideal case of Poland syndrome is presented as unilateral hypoplasia or aplasia of the sternocostal head of pectoralis major and an ipsilateral limb deformity. Our case of 7 month old girl has absence breast tissue in right side which matches with finding of "Amazone syndrome" described by Muhlbauer in 1977.⁷ He suggest that the extremity bud damage and the proximity of the lacteal mound during embryogenesis result in the lack of development of breast tissue. On Foucras's classification, our case falls on grade II which involves marked pectoralis major aplasia, hypoplasia, or other chest wall muscles, with possible rib deformity.⁸

Treatment of Poland syndrome differs depending on the symptoms which may include reconstruction by placement of an implant and /or transfer of the latissimus dorsi muscle. Report are found surgeon using free, contralateral latissimus dorsi muscle flap in 2 year old patient. Prognosis following surgical treatment has been found good.

With increasing rate of pregnant mother smoking it is important to rule out Poland syndrome if asymmetry is noted during chest examination. PS association with dermal disease, blood dyscrasias and breast cancer shows importance of screening other associated anomaly if PS is suspected.

Treatment of Poland syndrome depends upon various factors such as age, sex, type of deformity, and associated functional restriction. Most common indication for surgery is cosmetic reason, Paroxysmal chest wall motion and increasing lung herniation are additional indication for surgery. Reports shows that functional and anatomical defects of the chest can be corrected using a variety of reconstructive techniques, including lipofilling, tailored silicone prosthesis, and muscle flaps (latissimus dorsi, rectus abdominis, and omentals).

REFERENCES

1. Nord. Poland syndrome - symptoms, causes, treatment. National Organization for Rare Disorders [Internet]. 2015 June [cited 2023 April 26]. Available from: <https://rarediseases.org/rare-diseases/poland-syndrome/>
2. Poland's syndrome revisited - The annals of thoracic surgery [Internet]. [cited 2023 April 26]. Available from: [https://www.annalsthoracicsurgery.org/article/S0003-4975\(02\)04161-9/fulltext](https://www.annalsthoracicsurgery.org/article/S0003-4975(02)04161-9/fulltext)
3. Gonda, K. et al. (2018) Poland syndrome accompanied by internal iliac artery supply disruption sequence: A case report - Journal of Medical Case Reports. BioMed Central. 2018 Oct; 12(312). Available from: <https://doi.org/10.1186/s13256-018-1823-8>
4. Orphanet: Poland syndrome. [cited 2023 April 26]. Available from: https://www.orpha.net/consor/cgi-bin/OC_Exp.php?lng=EN&Expert=2911

5. Friedman JM. Genetics and epidemiology, congenital anomalies and cancer. *Am J Hum Genet.* 1997 Mar; 60(3): 469-73.
6. Mojallal A, La Marca S, Shipkov C, Sinna R, Braye F. Poland Syndrome and Breast Tumor: A Case Report and Review of the Literature. *Aesthetic Surgery Journal.* 2012; 32(1), 77–83. doi:10.1177/1090820x11430499
7. Mühlbauer W, Wangerin K. Embryology and etiology of the Poland and Amazone syndromes. *Handchirurgie.* 1977; 9(3): 147-52.
8. Fekih M, Mansouri-Hattab N, Bergaoui D, Chaieb A, Fikry T, Khairi H. Correction of breast Poland's anomalies. About eight cases and literature review. *Annales Chirurgie Plastique Esthetique.* 2010 Jun; 55(3): 211-8.