

Kirschner's Wires Fixation of Unstable Distal Radius Fractures in Children with the Kapandji Technique

Shrestha S¹, Shrestha DK¹, K.C D¹, Karki P¹, Yogi S¹

ABSTRACT

Introduction: Unstable distal radius fractures in children have more tendencies to get displaced with conservative management resulting into deformity. This Kapandji technique of K-wire fixation is on rise to reduce and maintain these fractures in recent days.

Aims: The aim of this study was to evaluate the effectiveness of the K-wires fixation in unstable distal radius fracture with Kapandji techniques. **Methods:** A cross-sectional observational study was conducted in Nepalgunj Medical College and Teaching Hospital, Kohalpur, Banke in unstable distal radius fracture in children with K-wires fixation using Kapandji method. **Results:** Twenty eight unstable distal radius fractures in children between 6 to 14 years of age were treated with one intrafocal K-wire and one or two extra focal K-wires to augment fixation. Immobilization of forearm with above elbow slab/cast for four to six weeks was enforced. K-wires were removed between four to six weeks of operation depending upon the union and followed prospectively for four months. The mean age of patients presented was 8.57 ± 1.79 years. This technique brought near anatomical reduction in all fractures. There was no reduction loss or remanipulation in any case. All fractures achieved union and functional outcome was excellent in 24 cases based on Modified Mayo Wrist Score. There was fewer complications like pin tract infection. **Conclusion:** This Kapandji technique of K-wire fixation, leverage reduction method, being an additional tool helps to achieve near anatomical alignment, and maintain reduction throughout the duration of healing. So it is an advantageous technique.

Keywords: Kapandji technique, Leverage technique, Unstable distal radius fracture

Authors:

1. Dr. Sabin Shrestha
2. Dr. Dinesh Kumar Shrestha
3. Dr. Dipendra K.C.
4. Dr. Prateek Karki
5. Dr. Sushil Yogi

¹ Department of Orthopedics, Nepalgunj Medical College & Teaching Hospital, Kohalpur, Banke.

Address for Correspondence:

Dr. Sabin Shrestha
Department Of Orthopedics
Nepalgunj Medical College & Teaching Hospital
Kohalpur, Banke
Email: shtdsabin@gmail.com

INTRODUCTION

Fractures in children (9%), being common health problem that present in emergency each year, has a significant burden to health care system.^{1, 2} Among them wrist fracture is the commonest fracture and distal radius fracture accounts for around 35% of them, resulting from fall on an outstretched hand or direct blow to arm.^{3, 4} Displaced distal radius fracture is often subjected to close reduction and cast immobilization but the risk of redisplacement is there (21 to 39 %).⁵⁻⁷ So, operative treatment with closed reduction under fluoroscopy and percutaneous K-wire fixation has evolved.⁸ Recommendation for operative treatment varies e.g. unreduced distal radius fracture, completely displaced fracture.⁹⁻¹¹ However, there are risks of pin tract infection, neuropraxia and premature closure of physis. The aim of this cross-sectional observational study

was to evaluate the outcome of unstable distal radius fracture in children treated with Kapandji technique in the tertiary care center, Nepalgunj Medical College and Teaching Hospital, Kohalpur, Banke, in the western part of Nepal.

METHODS

This study is a cross-sectional observational study done in 28 children between 6 to 14 years of age, who were admitted in Nepalgunj Medical Teaching Hospital, Kohalpur, Banke from August 2018 to October 2019 who had unstable distal radius fractures. Unstable distal radius fracture includes; translation of more than half the diameter of bone, with or without ulna fracture at the same level, bayoneting and volar angulations.¹²⁻¹⁴ All of them underwent closed reduction with Kapandji technique and fixed with K-wires. Informed written consent was taken from the parents/guardians and those who

meet the inclusion criteria and willing to take part in this study were included.

Inclusion criteria:

1. Age between 6 to 14 years.
2. Translation of distal radius more than half the diameter of bone with or without ulna fracture.
3. Bayoneting and Volar angulation.
4. Open fractures.

Exclusion criteria:

1. Age less than 6 years and more than 14 years.
2. Translation less than half diameter of bone.
3. Pathological fractures.

Surgical techniques

Under general anesthesia or brachial block, the forearm was positioned on the radiolucent table. Aseptic technique was followed and traction was applied to maintain the radial length. In a lateral position of the forearm and under fluoroscopy intrafocal K-wire, of 1.5 to 2.5mm diameter depending upon the bone diameter, was inserted dorsally at the fracture site and it was guided towards the proximal fragment. The posterior cortex of the proximal fragment was levered out posteriorly.¹⁵ After the posterior cortex was aligned, the K-wire was passed into the proximal fragment which reduced the fracture and it was confirmed with fluoroscopy. Depending upon the stability one or two extrafocal K-wires were passed from the lateral side into the proximal medial direction, from the radial styloid, or proximal to the physeal line. K-wires were left outside with sterile dressing. The associated ulna fractures were treated with percutaneous or intramedullary K-wires. Above elbow slab/cast was applied in pronation and ulnar deviation.

Postoperative X-ray was observed and patients with closed fracture were discharged on next day. Those with associated ulna fracture treated with K-wires, they were kept for three days to give intravenous antibiotics (cefuroxime) and alternate dressing and they were discharged on the third post-operative day in oral antibiotics (cefuroxime) for seven days more. Those with open fracture, they had iv antibiotics for five days and they were changed into oral and discharged on seventh day. Patients were reviewed after seven days for pin tract infection at the site of entry of K wires, discharge and displacement with radiograph. Slab/cast and K-wires were removed after the X ray showed the features of union, usually after 28 days. Otherwise, K- wires were continued for two weeks more in cast. Patients were encouraged to mobilize the wrist after removal of slab/cast and K-wires and followed for four months period. Wrist function was accessed at 12 to 16 weeks of treatment, on the basis of "Modified Mayo Wrist Score" which analyze these parameters; pain, mobility, strength of grip and level of satisfaction.

Statistical analysis:

SPSS version 25 was used to perform statistical analysis and p value<0.05 was considered statistically significant. Chi square test was used to analyze functional outcome. Mean and standard deviation were calculated for all measured and calculated values.

RESULTS

Twenty-eight patients completed the follow-up. The mean age of children was 8.57 ± 1.79 years (range, 6 to 14 years) with male predominance of 17 (60.7 %) as shown on table I.

		Sex		Total
		Female	Male	
Age in years	6- <10	8	13	21
	≥10-14	3	4	7
Total		11	17	28

Table I: Age and sex distribution.

Fall on out stretch hand was the common mechanism of injury, 20 (71.4%). It took approximately 22.5 ± 5.01 minutes (range 15 to 30 minutes) to do the procedure. All distal radius fractures were reduced with intrafocal K-wire and additional one or two extrafocal K-wires were used to stabilize fractures in 23(82.1%) and 5(17.9%) children respectively. Eighteen (64.2%) patients had associated ulna fractures shown on table II. K-wire was placed from proximal end of ulna in 8 cases and from distal end in four cases. Two (7%) out of 12 cases who underwent ulna fixation, had open fracture at ulna; among two open fractures one had associated supracondylar fracture. One with associated supracondylar fracture of humerus was treated with open reduction through the posterior approach and fixed with K wires after distal radius and ulna were fixed. Above elbow slab was applied in 10 cases with radius fracture only and above elbow cast was applied in 18 cases associated with ulna fracture and window were made at the site of pin and wound on first post-operative day for dressing.

		Closed fractures	Open fractures	Total
Radius only fracture		10	0	10
Associated ulna fracture	Undisplaced and not fixed with K-wires	6	0	6
	Displaced and fixed with K-wires	10	2	12
Total		26	2	28

Table II: Distribution of type of fracture and associated ulna fracture.

In all cases, Kapandji technique brought anatomical or near anatomical reduction and no open reduction was performed in any case. Immediate postoperative X-rays did not show residual angulations and/or translation. In 10 cases, those with radius fracture only, slabs were continued for four weeks and those associated with ulna fracture (18 cases) above elbow

cast was continued for three weeks in 16 cases then converted into below elbow cast was continued for two weeks more. Those with associated open fracture it was continued for four weeks and converted to below elbow cast continued for two weeks more. K-wires and slabs were removed in four weeks in ten patients, in 16 cases it was removed in five weeks and in two patients with distal radius and open ulna fracture, K-wires were removed at six weeks. The duration of treatment was uneventful. Twenty patients had full range of motion on two weeks after removal of K-wires. Six patients had it after three weeks of removal who had associated ulna fracture and one had it after four weeks who had associated open fracture at ulna, after removal of K-wires.

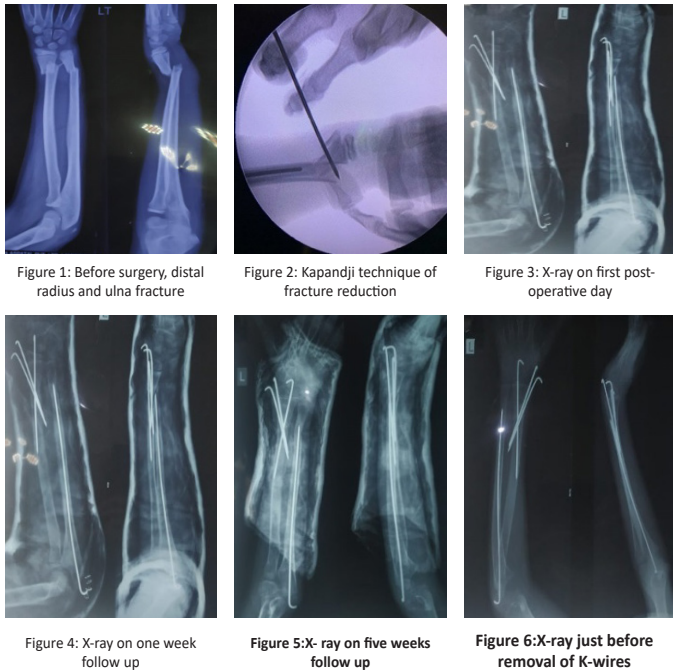


Figure 1: Sequential radiograph of distal radius fracture associated with ulna fracture.

Average follow up was 4.2 months (four to six months). One patient with open fracture had discharge from ulnar side at fracture which was serous type and it subsided after three days of operation. It was managed by alternate day dressing and antibiotics. Two patients, who skipped two weeks follow-up, came on third week, had pin tract infection, which resolved after a week with alternate day dressing and antibiotics. One patient had restricted range of motion for six weeks.

On final follow-up the functional outcome was excellent in 24 (85.7%) cases, good in three (10.7%) cases and optimal in one (3.6%) case as shown in table III and IV. The associated open fracture of ulna had optimal outcome, $p = <0.01$.

Fractures	Functional outcome			Total
	Excellent	Good	Optimal	
Radius fracture only	10	0	0	10
Associated ulna fracture treated conservatively	6	0	0	6
Associated ulna fracture treated with K-wires	8	3	1	12
Total	10	3	1	28

Table III: Functional outcome on the basis of types of fracture and method of treatment.

Ulna fracture		Functional outcome			Total
		Excellent	Good	Optimal	
Closed	not fixed	6	0	0	6
	fixed	8	2	0	10
Open		0	1	1	2
Total		14	3	1	18

Table IV: Functional outcome on the basis of associated open and closed ulna fracture.

DISCUSSION

Closed reduction and casting has been the standard method of treatment in distal radius fracture but due to irreducibility and redisplacement, closed reduction and K-wire fixation has been evolving. Sengab et al⁸ in meta-analysis reported that unstable distal radius fractures and those with the risk factors have higher incidence of redisplacement after reduction. So, primary K-wire fixation is better than conservative treatment. McLauchlan et al¹⁶, in a prospective randomized controlled trial, suggested percutaneous K wire fixation for displaced distal radius fracture is a reliable method to maintain alignment and prevent redisplacement which lessens resurgery compared to closed reduction and casting. Sometimes, reduction of fracture is difficult so, the Kapandji technique is in rise for those fractures rather than the open reduction as this method of treatment has lesser complications compared to it. As Parikh et al¹⁷ in retrospective case control study, described this technique as a added reduction tool where close manipulation fails. This technique helped to reduce the fracture in this study too. Strohm et al¹⁸ in a prospective randomized trial of 100 distal radius fracture treated by K-wire in adults concluded Kapandji method of treatment has a better outcome than those of conventional two extrafocal k wire fixation that was introduced through the radial styloid, Willenegger techniques. Choi et al¹⁹ in conventional K-wire treatment of unstable distal radius fracture in children in 157 cases, eight percent of cases landed into open reduction and 6.4% cases lost the reduction. In current study none of the cases need the open reduction. There was no loss of reduction after stabilization with two to three K wires. Generally, radiographs are taken at seven to 10 days interval for first three weeks to assess early unacceptable redisplacement or fracture reduction.^{14, 16} In our

study 12 patients had three radiographs taken, 14 patients had four radiographs taken and two had five radiographs taken before removal of pin because they were followed for two weeks more and it was done before removal of pin to ensure the adequate union. It is comparable to the study done by Satish et al.¹⁵ McLauchlan et al.¹⁶ and Ozcan et al.²⁰ observed lesser radiograph in patients with K-wire fixation but this study had longer follow ups, up to 12 weeks depending upon age of patient and the outcome of the fracture for the study purpose. Parents were satisfied with appearance of wrist at first visit of K-wires removal. Most of the patient regained full range of motion and follow ups were discontinued. This Kapandji technique is an example of first class lever, surgeon reduced the fracture with adequate effort and it was smooth.¹⁵

Complications associated with Kapandji technique are less compared to conventional K-wire fixation like open reduction of fracture, loss of reduction and pin tract infection. In this study one patient had infection of wound, which subsided after three days of intravenous antibiotics and alternate day dressing. Two patients had pin tract infection as they skipped the follow up on the first two weeks.

The functional outcome was comparable with the study done by Kamiloski et al.²¹ At final follow up in this study, patients did not complain of pain except two cases, 26 patients were satisfied but two patients were moderately satisfied as per modified Mayo wrist score. Among two patients one had associated open fracture at ulna and supracondylar fracture, and another had comminuted fracture of radius. Twenty-seven patients had normal range of motion compared to the normal limb but one had 80% of range of motion who had prolonged immobilization. Grip strength was comparable with normal hand in all cases. On the basis of Mayo Wrist Score 85.7 % (24) had excellent result.

Though it is accepted that the malunited distal radius fracture remodel with better cosmetic and functional outcome in children, parents or guardians are worried about the it, so they prefer to do operative treatment in this study. Union and joint stiffness are not major problems as compared to malunion. To avoid malunion, regaining range of motion as soon as possible and decreasing duration of treatment and follow-up, this Kapandji technique provides the better option regarding that. This decreases the cost and stress in the caregivers.¹⁵ Thus, the Kapandji technique is better method of fixation with unstable distal radius fracture in children.

LIMITATION

Small sample, non-randomized control trails and short duration of follow ups are the limitations.

CONCLUSION

Kapandji technique of K-wire fixation is better, easier and advantageous method of treatment of unstable distal radius fracture in children as it is easier leverage technique which can be done without difficulty and it decreases the risk of redisplacement, and duration of follow up.

REFERENCES

1. Cooper, C., et al., Epidemiology of Childhood Fractures in Britain: A Study Using the General Practice Research Database. *Journal of Bone and Mineral Research*, 2004. 19(12): p. 1976-1981.
2. Spady, D.W., et al., Patterns of injury in children: a population-based approach. *Pediatrics*, 2004. 113(3 Pt 1): p. 522-9.
3. Cheng, J.C. and W.Y. Shen, Limb fracture pattern in different pediatric age groups: a study of 3,350 children. *J Orthop Trauma*, 1993. 7(1): p. 15-22.
4. Worlock, P. and M. Stower, Fracture patterns in Nottingham children. *J Pediatr Orthop*, 1986. 6(6): p. 656-60.
5. Asadollahi, S., K.S. Ooi, and R.C. Hau, Distal radial fractures in children: risk factors for redisplacement following closed reduction. *J Pediatr Orthop*, 2015. 35(3): p. 224-8.
6. Marcheix, P.S., et al., Dorsal distal radius fractures in children: role of plaster in redisplacement of these fractures. *J Pediatr Orthop B*, 2011. 20(6): p. 372-5.
7. McQuinn, A.G. and R.L. Jaarsma, Risk factors for redisplacement of pediatric distal forearm and distal radius fractures. *J Pediatr Orthop*, 2012. 32(7): p. 687-92.
8. Sengab, A., P. Krijnen, and I.B. Schipper, Risk factors for fracture redisplacement after reduction and cast immobilization of displaced distal radius fractures in children: a meta-analysis. *Eur J Trauma Emerg Surg*, 2020. 46(4): p. 789-800.
9. Proctor, M.T., D.J. Moore, and J.M. Paterson, Redisplacement after manipulation of distal radial fractures in children. *J Bone Joint Surg Br*, 1993. 75(3): p. 453-4.
10. Zamzam, M.M. and K.I. Khoshhal, Displaced fracture of the distal radius in children: factors responsible for redisplacement after closed reduction. *J Bone Joint Surg Br*, 2005. 87(6): p. 841-3.
11. Jordan, R.W. and D.J. Westacott, Displaced paediatric distal radius fractures--when should we use percutaneous wires? *Injury*, 2012. 43(6): p. 908-11.
12. Dicke, T.E. and J.A. Nunley, Distal forearm fractures in children. Complications and surgical indications. *The Orthopedic clinics of North America*, 1993. 24(2): p. 333-340.
13. GV, M., H. PW, and C. JC, Translation of the radius as a predictor of outcome in distal radial fractures of children. *The Journal of Bone and Joint Surgery. British volume*, 1993. 75-B(5): p. 808-811.
14. Hove, L.M. and C. Brudvik, Displaced paediatric fractures of the distal radius. *Arch Orthop Trauma Surg*, 2008. 128(1): p. 55-60.
15. Satish, B.R., et al., Closed reduction and K-wiring with the Kapandji technique for completely displaced pediatric distal radial fractures. *Orthopedics*, 2014. 37(9): p. e810-6.

16. McLauchlan, G.J., et al., Management of completely displaced metaphyseal fractures of the distal radius in children. A prospective, randomised controlled trial. *J Bone Joint Surg Br*, 2002. 84(3): p. 413-7.
17. Parikh, S.N., V.V. Jain, and J. Youngquist, Intrafocal pinning for distal radius metaphyseal fractures in children. *Orthopedics*, 2013. 36(6): p. 783-8.
18. Strohm, P.C., et al., Two procedures for Kirschner wire osteosynthesis of distal radial fractures. A randomized trial. *J Bone Joint Surg Am*, 2004. 86(12): p. 2621-8.
19. Choi, K.Y., et al., Percutaneous Kirschner-wire pinning for severely displaced distal radial fractures in children. A report of 157 cases. *J Bone Joint Surg Br*, 1995. 77(5): p. 797-801.
20. Ozcan, M., et al., Percutaneous Kirschner Wire fixation in distal radius metaphyseal fractures in children: does it change the overall outcome? *Hippokratia*, 2010. 14(4): p. 265-70.
21. Kamiloski, M., et al., The Kapandji Technique of Closed Reduction Using Sommer - Pins in the Treatment of Completely Dislocated Fractures of the Distal Radius in Children. *Open Access Maced J Med Sci*, 2018. 6(2): p. 330-335.