

Research Article

Functional outcome of Metacarpal Fracture managed with Miniplate and Screws

Gyanendra Shah^{1*}, Bachchu Ram KC², Pankaj chand³, Deb Narayan Sah⁴

Bir Hospital & Patan Hospital, Kathmandu

¹Lecturer, Dept. of Orthopedics and trauma, National Academy of Medical Sciences, Kathmandu

²Professor, Dept. of Orthopedics and trauma, Nepalese Army Institute of Health Sciences, Kathmandu

³Professor, Dept. of Orthopedics and trauma, Nepalese Army Institute of Health Sciences, Kathmandu

⁴Assist. Professor, Dept. of Orthopedics and trauma, Janaki Medical College, Ramdaiya

ABSTRACT

Background and Objectives: Early techniques of splint immobilization work well for simple metacarpal fractures. However, if significantly shortening, rotational deformity, and angulations occur, surgical treatment is required. The aim of this article was to study the functional outcome of metacarpal fractures treated by open reduction and internal fixation with mini plates and screw in low resource condition of Nepal.

Material and Methods: This retrospective study was done over a period of one year 2012 to 2013 in Bir Hospital, Patan hospital and Shree Birendra hospital. The functional outcome after treatment was assessed by ability to perform acts of daily life and calculating American Society for Surgery of the Hand Total Active Flexion (ASSH-TAF).

Results: Out of 30 patients twenty three were male (76.7%) and seven were female (23.3%). Among them, 7 patients (23.3%) showed union in 6 weeks. 18 Patients (60%) had union in 4 weeks. 3 patients (10%) had at five weeks and 2 patients had union at 6 weeks. We observed ASSH-TAF score at 2 weeks, 1month, 3 months, and 6 months. Results showed 24 patients (80%) had excellent, 4(13.3%) had good and 2(6.7%) had poor result.

Conclusion: The use of miniplate and screws is a reasonable option for treating in displaced metacarpal fracture as it provides a rigid, Secure an anatomical stable reduction, which is sufficient to allow early mobilization of the adjacent joints, hence the mini plate fixation is effective means of immobilization of fracture of metacarpal with less complication and excellent functional outcome.

Key words: Metacarpal fracture, miniplate, screws, TAF score

INTRODUCTION

Hand and upper extremity injuries are one of the most common injuries treated in

emergency department [1]. The principles of fracture management remain the same regardless of the techniques used with the goal to restore full hand function. As a general

rule this can be accomplished through anatomical reduction, obtaining adequate stability to allow early range of motion and minimizing additional soft tissue injury. Early techniques of splint immobilization worked well for simple hand fractures, but fell short in more complex injuries. While there are generally accepted guidelines for management of various hand fractures [2,3,4,5], there is surprisingly little data comparing different treatment options. Most studies are retrospective and there are few prospective clinical trials (and even some of fewer randomized trials) comparing different methods of fixation.

Kirschner wires are the most commonly used fixation after closed or open reduction. However, late initiation of movement resulting in stiff hand, pin tract infection, and pin migration are the disadvantages of this method. The level of fracture care in developed nations cannot be applied to the third world because of economical and health system constraints. Modern techniques of CRPP will not be feasible in the areas where the image intensifier is not available, it also need staff sufficiently familiar with the use which is a rarity in our country.

A plate fixation is used in comminute metacarpal fracture. Stable fixation allows for passive and active movements in intrinsic muscles affected by the trauma. Significantly improving hand function. Preservation of the anatomical reduction prevents the rotational deformity. In patients treated with plate and screws osteosynthesis, an adequate stability was achieved and early motion was started [2,5,6]. All patients went their preinjury occupation without angulations or rotational deformity. The aim of this study was to assess the functional out come with unstable metacarpal fracture managed by open

anatomical reduction and internal fixation with miniplate and screws.

MATERIAL AND METHODS

This study was done in Bir hospital, Shree Birenda hospital and Patan hospital from May 2012 to May 2013. The ethical approval and informed written consent was taken in Nepali language. A total 33 patients who were operated with the diagnosis of displaced, irreducible unstable metacarpal fracture were included in the study. Convenient quota sampling was used for this study. There were 33 of metacarpal fractures patients but 3 patients were lost to follow up after surgery. So, only 30 cases could be followed up for six months. Hence, only those cases were included in final data analysis.

The mini plate and screws were used for all operations. Extra articular fracture, open fracture and undisplaced fracture were excluded from the study. All surgical intervention was performed in supine position with a pneumatic tourniquet in upper arm. A dorsal approach was used to access to the fracture site. The fracture site was reached by displacing extensor tendon to the radial and ulnar side.

The fracture side exposed by periosteal elevator and then internal fixation done with mini plate following the surgical reduction. Fixation was achieved with size and screw and plate according to the standard AO technique with minimum of four cortices in each side of fracture.

The periosteal sleeve was closed over the plate and wound closed in layers and splint was applied. 1st follow up was done in 2 weeks, 2nd follow up in one month, 3rd follow up in 3 months and 4th follow up in 6 months.

Scoring parameters:

Functional outcome after fracture fixation was assessed by and calculating ASSH TAF (American Society for Surgery of Hand and Total Active Flexion) score at each follow up. Analysis was done with mean, standard deviation.

Table1: ASSH TAF Score System

Degree of Flexion	Rating
TAF from MCPJ to DIPJ : digits 2-5 > 220 > 180-220 < 180	Excellent Good Poor
TAF from MCPJ to IPJ : thumb > 120 > 100-120 < 100	Excellent Good Poor
Clinical Assessment Committee. Total Active Flexion (TFA) Scale, American Society for Surgery of the Hand (ASSH) report. New Orleans, 1976.	

RESULTS

In present study 30 patients were included of unstable metacarpal fracture. All the 30 patients underwent open reduction and internal fixation with plate osteosynthesis for unstable metacarpal fracture. Out of 30 patients twenty three patients were males and seven patients were female. Going to the details of mechanism of injury, direct trauma was predominant cause of injury accounting 83.3% followed by RTA and trivial trauma 3, 3%.

The fracture morphology out of thirty patients five had transverse fracture, eight had spiral fracture, thirteen had oblique fracture and three had segmental fracture and one comminuted fracture. The metacarpal involvement was noted four had second metacarpal eight had third metacarpal

fourteen had fourth and four patients had fifth metacarpal. 3 patients developed superficial wound infection .These 3 cases with superficial infection settled with daily dressing and antibiotics. Two patients had reflex sympathetic dystrophy for whom physiotherapy was advised and continued and patients improved range of motion and the results in these patients were fair.

Functional outcome assessed by ASSH-TAF score was excellent in 24 patients (80%), good in 4 patients (13.3%) and two (6.7%) had poor result .The overall results were satisfactory.

TAF at 6 months

TAF grading	Frequency	Percent
Excellent	24	80.0
Good	4	13.3
Poor	2	6.7
Total	30	100.0

None of the patients in our study developed tendon irritation, which is due to the result of extra cautions efforts taken to cover the plate with soft tissue. None of the cases of rotational and angular displacement were seen.

DISCUSSION

Numerous studies, biomechanical and clinical, have been done in an effort to provide optimal treatment of unstable metacarpal fractures. The overall goal is to maintain sufficiently rigid fixation for bony union whereas allowing early motion to prevent stiffness and maximize function, several biomechanical studies have been done to assess the relative strength of various types of fixation methods of metacarpal fractures, including intra modularly k-wires,

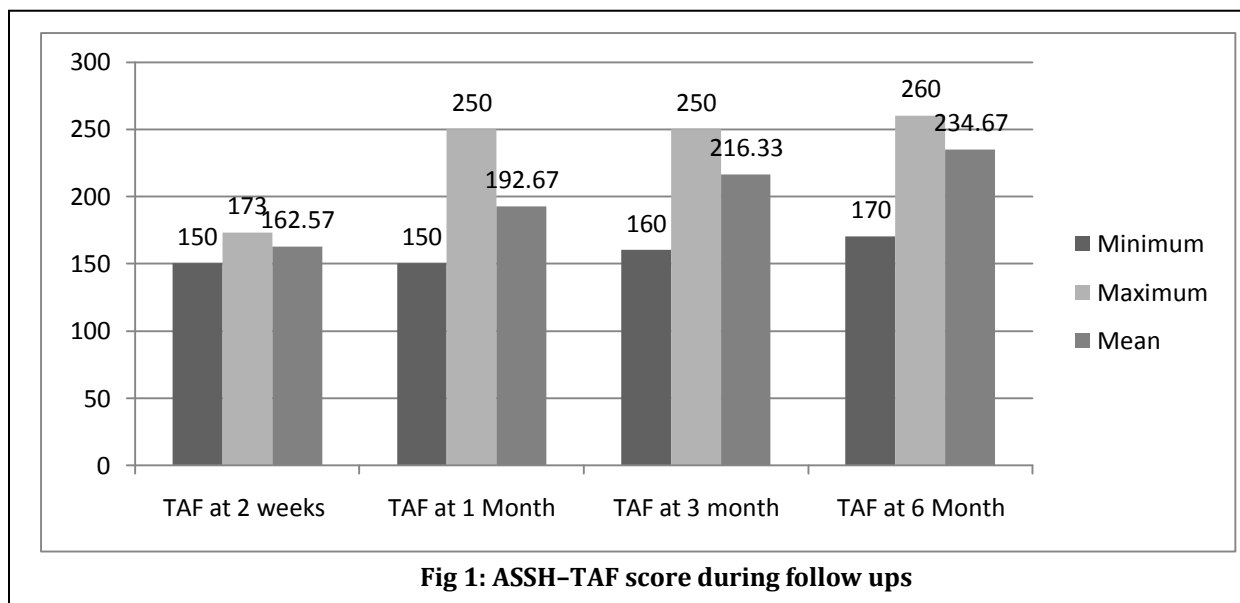


Fig 1: ASSH-TAF score during follow ups

and wiring system, lag screw and mini plating.

Open reduction and internal fixation with k-wire [7] is one of the treatment modalities in these unstable fractures but they provide less rigid fixation and are rotationally unstable, there is increased association of pin tract infection and problems due to protruding ends of k-wire are significant, Interosseous wiring with k-wire although provides rigid equivalent to plating, are useful only in transverse fracture.

Intramedullary fixation with prebent k-wire was used for transverse and short oblique fracture. They provide comparable functional outcome with plate and screw fixation. But there is incidence of loss of reduction, penetration of metacarpophalangeal joint by hardware, thus necessitating a second surgery for hardware removal.

There are many literature studies showing satisfactory result of metacarpal fracture managed by mini plate and screws [8-11]. A study conducted by Joshi A. showed by good functional outcome by total active motion

more than 230 degree in 15 of 17 patients for whom plate fixation was done[8]. Another study Gupta R, et al showed excellent functional outcome with total active movement more than 230 degree in his patients which was managed by mini plate and screws [7]. Page S.M. et al [12] found that range of motion excellent 62%, good 14% and poor 11% these results are comparable to those of Pun W.K. et al [13] and Chen et al [14]. Bosscha K. et al conducted a study in 43 patients with 47 metacarpal fractures with significant displacement and rotation angulations and instability and was managed with internal fixation using AO miniplate with anatomical reduction [15]. At a review after a mean period of 28 months, 31 patients with 35 fractures out of 34 patients had excellent recovery of TAF 92%. Only 3 patients had poor recovery with TAF.

Compared to our study their study had good outcomes may be due to long duration of follow up. They concluded that fixation with AO mini plate and screw have good functional outcome. In our study we found 100% union rate with 80% excellent and 13.3% good result only 2 patients had poor result according to

the ASSH (American Society for Surgery of Hand) Total Active flexion (TAF) score. Stable and rigid fixation provided by mini plates and screws allowed early mobilization of fingers thereby preventing stiffness and achieve over all good functional out come.

CONCLUSION

Mini plate and screws fixation for unstable metacarpal fracture produce rigid stable anatomical fixation and allowed early mobilization and achieved good functional outcome.

LIMITATIONS

The sample size is small and cannot be related to whole country.

ACKNOWLEDGEMENT

We would like to express our deep sense of gratitude to my teachers, senior and friends of the department of orthopedics and trauma of NAMS and National Army institute of medical sciences for the completion of this research work successfully.

AUTHOR'S CONTRIBUTION

GS- Conception of study and data collection. Analysis and interpretation of data, manuscript writing; **BRK-** Analysis and interpretation of data; **PC and DNS-** Data collection ,Analysis and interpretation of data.

SOURCE OF SUPPORT: None

CONFLICT OF INTEREST: None declared.

REFERENCES

1. Emmett JE, Breck LW. A review of analysis of 11,000 fractures seen in a private practice of orthopaedic surgery. *J Bone Joint Surg* 1958; 40: 1169-75.

2. Barton N. Conservative treatment of articular fractures in the hand. *J Hand Surg* 1989; 14: 386-90.
3. Klein DM, Belsole RJ. Percutaneous treatment of carpal, metacarpal, and phalangeal injuries. *Clin Orthop Relat Res* 2000; 375: 116-25.
4. Lee SG, Jupiter JB. Phalangeal and metacarpal fractures of the hand. *Hand Clin* 2000; 16:323-32.
5. Singletary S, Freeland AE, Jarrett CA. 'Metacarpal fractures in athletes: treatment, rehabilitation, and safe early return to play, *J Hand Ther* 2003; 16: 171-9.
6. Strickland JW, Steichen JB, Kleinman WB. Phalangeal fractures: factors influencing digital performance. *Orthop Intev* 1982; 11: 39-50.
7. Gupta R, Sing R, Siwach RC, Sanwan SS, Magu K N, Diwan R. Evaluation of surgical stabilization of metacarpal and phalangeal fracture of hand. *Indian Journal of Orthopedics* 2007;(41):224-229.
8. Joshi A, K.C.BR, Chand P, Thapa BB. Early Experience with Low Profile Plate Osteosynthesis for Metacarpal fracture *J Nepal Health Res Council* 2009; (7):19-24.
9. Soni A., Gulati A., Bassi J. L., Singh, D., &Saini, U. C. Outcome of closed ipsilateral metacarpal fractures treated with mini fragment plates and screws: a prospective study. *Journal of Orthopaedics and Traumatology* 2012; 13(1). 29-33.
10. Dabezies EJ, Schutte JP. Fixation of metacarpal and phalangeal fractures with miniature plate *Hand Surg. (Am)* 1986; 2:283-8.
11. Omokawa S, Fujitani R, Okawa T, Yajima H. Prospective outcomes of comminuted metacarpal fracture using titanium plate *Hand Surg* 2008;33(6):857-63.
12. Page, Steven M., and Peter J. Stern."Complications and range of motion following plate fixation of metacarpal and phalangeal fractures." *The Journal of hand sur* 1998:827-832.
13. Pun WK, Chow SP, So YC et al. Unstable phalangeal fractures:treatment by A.O. screw and plate fixation. *J Hand Surg (Am)* 1991; 16: 113-117.
14. Chen SHT, Wie F, Chen H, Chuang C, Noordhoff S. Miniature plates and screws in acute complex hand injury. *J Trauma* 1994; 37:237-242.

15. Bosscha K, Snellen JP. Internal fixation of metacarpal and phalangeal fracture with AO minifragmentary plate and screw Injury 1993; 24:166-8.

Correspondence to:

Dr. Gyanendra Shah

Lecturer

Department of orthopedics and Trauma

National Academy of Medical sciences

Bir Hospital, Kathmandu

E-mail: drgshah@hotmail.com