

Unilateral Phthiriasis Palpebrarum Infestation: A Rare Presentation

Vinit Kumar Kamble,^{a,c} Sharad Gupta,^{a,c} Reena Yadav,^{a,c} Sanjay Kumar Singh,^{a,c}
Bipin Bista,^{a,c} Nirajan Sah^{b,c}

ABSTRACT:

Introduction: Phthiriasis palpebrarum is an uncommon eyelid infestation mainly caused by *Phthirus pubis* also known as crab lice. **Case report:** A 16 years male presented with redness, itching and watering of the right eye for one week. On slit-lamp biomicroscopic examination lice and nits anchored to the eyelashes along with seborrheic material accumulation was noted. Lice, partial nits along with matted eyelashes were removed and sent to laboratory for microscopic examination. On follow up visit remaining nits were expunged. **Conclusion:** Meticulous slit lamp biomicroscopic examination should be done in all patients presenting with itching of the eyelids in conjunction with clinical findings resembling seborrhea and evidence for Phthiriasis palpebrarum should be looked for.

Keywords: Crab louse, Nits, Phthiriasis palpebrarum, Pruritus, Seborrheic

INTRODUCTION:

Phthiriasis palpebrarum is a rare type of eyelid infestation caused by *Phthiriasis pubis*, commonly known as crab lice.[1] It mainly infests the hair of pubic and inguinal regions, but rarely infests the eye lashes and eyelids.[1] The condition is commonly seen in developing countries and is associated with poor hygiene and overcrowding. [2] These conditions may sometimes be mistaken as blepharitis or blepharo-conjunctivitis due to similarities in the signs and symptoms.[3] Various treatment options with varying efficacy are available. Few literatures reported that mode of transmission of lice are from one hair bearing area to another and found that any hair bearing area may become infested.[4]

Here we report an unusual case of Phthiriasis

Submitted: 20 August, 2020

Accepted: 21 December, 2020

Published: 29 December, 2020

a - Consultant Ophthalmologist,

b - Optometrist,

c - Sagarmatha Choudhary Eye Hospital, Lahan, Siraha, Nepal.

Corresponding Author:

Vinit Kumar Kamble

e-mail: dr.vinitkumarkamble@gmail.com

ORCID: <https://orcid.org/0000-0003-4170-0954>

palpebrarum infestation of the right upper eyelid.

CASE REPORT:

A 16-years-old male presented to our out-patient department with chief complaints of itching and watering of the right eye for one week. On examination the best corrected visual acuity was 6/6 in both eyes. Slit lamp bio-microscopic examination of the right upper eyelid showed numerous, translucent, white nits along with multiple mobile, semi-transparent lice of different sizes adherent at the base of eyelashes (Fig. 1A and B) whereas lower eyelid and eyelashes were unremarkable. The left eye was normal. He did not give history of similar illness to his family members. He was a student from poor socio-economic background. The pubic and inguinal regions were also examined where no signs of lice infestation were noted. Eyelashes, lice and partial removal of nits were done with use of forceps and the specimens were sent for microscopic examination where the lice of *Phthiriasis pubis* and nits were confirmed (Fig. 2). Complete removal of nits was not attempted due to the risk of bleeding.

How to cite this article:

Kamble VK, Gupta S, Yadav R, Singh SK, Bista B, Sah N. Unilateral Phthiriasis Palpebrarum Infestation: A Rare Presentation. *Journal of Lumbini Medical College*. 2020;8(2):281-283. DOI: <https://doi.org/10.22502/jlmc.v8i2.398>. Epub: 2020 December 29.



Licensed under CC BY 4.0 International License which permits use, distribution and reproduction in any medium, provided the original work is properly cited.

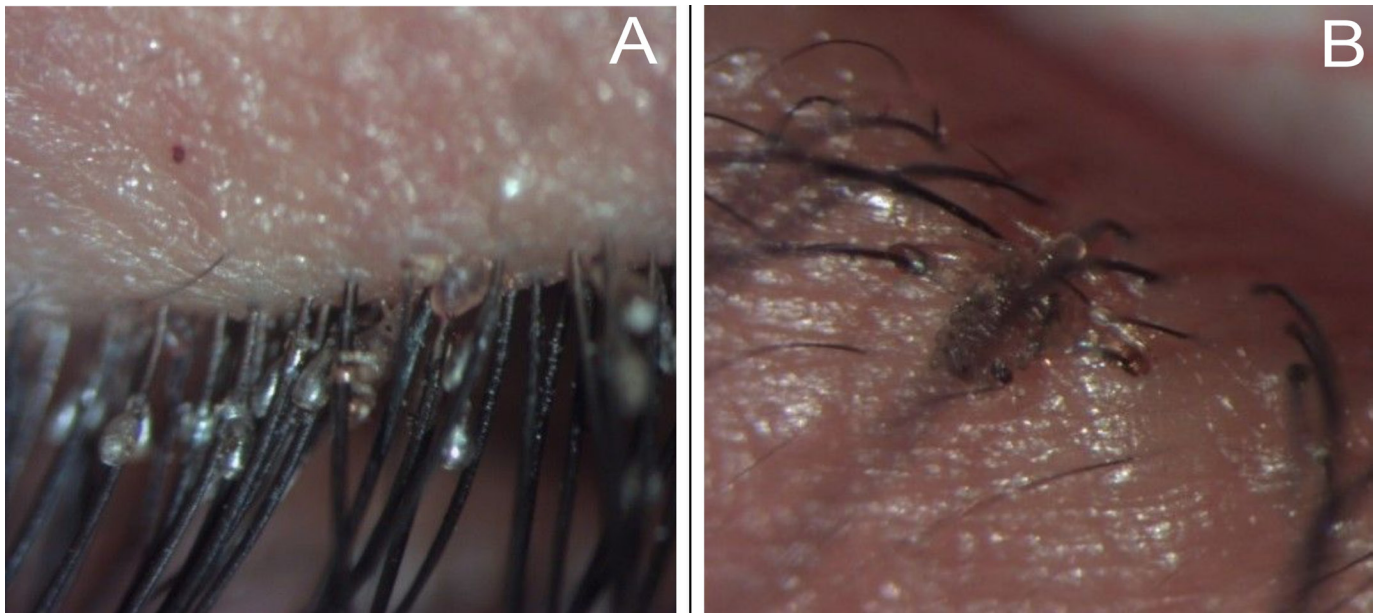


Fig.1. A: Magnified view of multiple nits in right upper eyelid Figure. B: Magnified view of crab louse.




Fig.2. Microscopic appearance of crab louse and nits

The patient was advised to apply pilocarpine 4% gel twice daily over the lid margins and asked to review after seven days. The dermatological consultations for the patient and family members were advised but they refused. On follow up all signs and symptoms had resolved and the remaining nits were removed. The recurrence was not seen in six months follow up period. He was advised to maintain eyelid hygiene (Figure 3).

DISCUSSION:

Phthiriasis palpebrarum is an uncommon cause for pruritus still seen in developing countries with poor personal hygiene. Phthiriasis palpebrarum is characterized by infestation of eyelashes with *Pthirus pubis* also considered as a sexually transmitted disease (STD).[5] The primary habitat of Phthiriasis pubis is pubic hair but in severe infestations, the hair of axilla, chest, eyebrow and eyelashes are also involved.[1,6,7,8] *Phthiriasis*

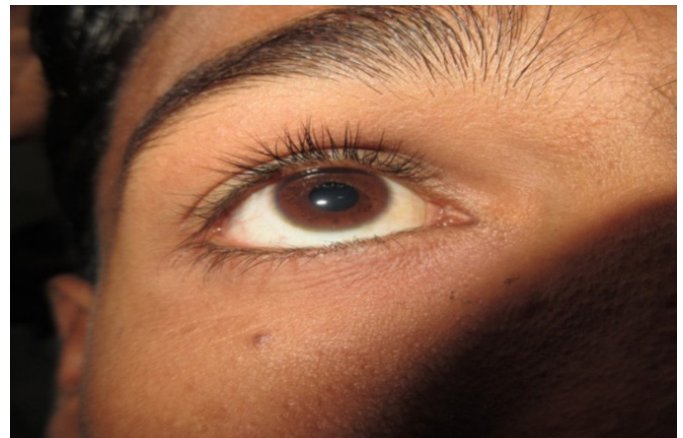

Fig.3. Complete removal of lice and nits.

pubis is a member of hematophagous ectoparasites. [2,9] It belongs to the phylum Arthropoda, the class Insecta and the order Phthiraptera. Beside this, other two species of lice known to infest humans are *Pediculus humanus capitis* (head louse) and *Pediculus humanus corporis* (body louse).[10] *Pthirus pubis* is an entirely different species with a distinctive morphology and habitat. Adult pubic louse is wingless, approximately 1–2 mm in size with a broad, flat and oval translucent body through which freshly ingested blood can be visualised. The body is crab-like which is divided into the head, thorax and abdomen, with three pairs of short, stout legs and powerful claws, which enable them to grasp hair shafts tightly.[11] Clinically patient infested with Phthiriasis palpebrarum present with pruritus, conjunctival hyperemia and preauricular lymphadenopathy due to secondary infection at the site of louse bites.[1] There are multiple treatment options available like trimming of eyelashes or mechanical removal, 4% pilocarpine gel, oral

ivermectin, 20% fluorescein eye drops, argon laser or cryotherapy.[1,3,12] In our report eyelashes, lice and partial removal of nits were done with forceps and advised to apply 4% pilocarpine gel over lid margins. On follow up, all the signs and symptoms had resolved and the remaining nits were removed.

CONCLUSION:

Phthiriasis palpebrarum infestation is an unusual cause of pruritus. It is mandatory to do meticulous slit lamp biomicroscopic examination in all patients presenting with itching of the eyelids along with clinical findings resembling seborrhea accumulation on the eyelashes to avoid misdiagnosis in cases where blepharitis is considered. A clinical follow up of every patient is recommended to rule out residual parasitic infestation and clinical response to therapy.

Conflict of Interest: The authors declare that no competing interests exist.

Financial disclosure: No funds were available.

REFERENCES:

1. Anane S, Malek I, Kamoun R, Chtourou O. Phthiriasis palpebrarum: diagnosis and treatment. *J Fr Ophthalmol*. 2013;36(10):815-9. PMID: 24157356. DOI: <https://doi.org/10.1016/j.jfo.2013.03.018>
2. Ryan MF. Phthiriasis palpebrarum infection: A concern for child abuse. *J Emerg Med*. 2014;46(6):e15962. PMID: 24556565. DOI: <https://doi.org/10.1016/j.jemermed.2013.11.090>
3. Yi JW, Li L, Luo da W. Phthiriasis palpebrarum misdiagnosed as allergic blepharoconjunctivitis in a 6-year-old girl. *Niger J Clin Pract*. 2014;17(4):537-9. PMID: 24909484. DOI: <https://doi.org/10.4103/1119-3077.134063>
4. Lacarrubba F, Micali G: The not-so-naked eye: Phthiriasis palpebrarum. *The American Journal of Medicine*. 2013;126(11):960-1. DOI: <http://dx.doi.org/10.1016/j.amjmed.2013.08.002>
5. Charfi F, Ben Zina Z, Maazoun M, Kharrat W, Sellami D, Makni F, et al. [Phthiriasis pubis palpebrarum in children. Diagnosis and treatment]. *J Fr Ophtalmol*. 2005;28 (7):765-8. PMID: 16208228. DOI: [https://doi.org/10.1016/s0181-5512\(05\)80990-8](https://doi.org/10.1016/s0181-5512(05)80990-8)
6. Dohvoma VA, Ebana Mvogo SR, Atangana PJA, Nyasse P, Epee E, Ebana Mvogo C. Phthirus pubis Infestation of the Eyelids Presenting as Chronic Blepharoconjunctivitis in a 6-Year-Old Girl: A Case Report. *Case Rep Ophthalmol*. 2018;9(1):30-34. PMID: 29643778. DOI: <https://doi.org/10.1159/000485738>
7. Le Guyader F, Charpentier P. [Phthiriasis palpebrarum in a 52-year-old woman]. *J Fr Ophthalmol*. 2018;41(2):196-198. PMID: 29426762. DOI: <https://doi.org/10.1016/j.jfo.2017.08.005>
8. Gupta M, Gupta A. Phthiriasis palpebrarum masquerading as seborrheic blepharitis. *Australas Jtol*. 2016;57(4):e139-e140. PMID: 29896824. DOI: <https://doi.org/10.1111/ajd.12378>
9. Padhi TR, Das S, Sharma S, Rath S, Rath S, Tripathy D, et al. Ocular Parasitoses: A Comprehensive Review. *Surv Ophthalmol*. 2017;62(2):161-89. PMID: 27720858. DOI: <https://doi.org/10.1016/j.survophthal.2016.09.005>
10. Karabela Y, Yardimci G, Yildirim I, Atalay E, Kerabela SN. Treatment of Phthiriasis Palpebrarum and crab louse: Petrolatum jelly and 1% Permethrin shampoo. *Case Reports in Medicine*. 2015;2015:Article ID 287906. DOI: <https://doi.org/10.1155/2015/287906>
11. Sundu C, Dinç E, Kurtuluş UC, Yıldırım Ö. Common blepharitis related to Phthiriasis Palpebrarum: Argon laser phototherapy. *Türkiye Parazitol Derg*. 2015;39(3):252-4. PMID: 26470938. DOI: <https://doi.org/10.5152/tpd.2015.3861>
12. Elston DM. Drugs used in the treatment of pediculosis. *J Drugs Dermatol*. 2005;4(2):207-11. PMID: 15776778