

Adult Onset Best Vitelliform Macular Dystrophy: A Case Report

Sharad Gupta,^{a,c} Hari Sharma,^{a,d} Reena Yadav,^{a,c} Sanjay Kumar Singh,^{a,c} Sushma Chaudhary^{b,c}

ABSTRACT

Introduction: Best disease or vitelliform macular dystrophy is a rare autosomal dominant disorder with bilateral presentation characterized by subretinal accumulation of yellowish material in the macular area. Macular findings range from a small yellow spot, multiple vitelliform or atrophic lesions to a chorio-retinal scar. **Case report:** A 35 years male presented to our outpatient department with chief complaint of blurring of vision of both eyes for the past three months. His visual acuity was 6/12 in both right and left eyes. On slit-lamp bio-examination anterior segments of both eyes were normal. On fundus examination, both eyes revealed a single, circular, yellow-opaque egg yolk-like macular lesion with no other abnormalities. Optical coherence tomography of both eyes revealed deposits of homogenous hyper-reflective material beneath retinal pigment epithelium at fovea. Fundus fluorescence angiography showed blocked fluorescence at the site of vitelliform lesion of both eyes. **Conclusion:** Best vitelliform macular dystrophy is a rare genetic disorder with incomplete penetrance. Optical coherence tomography and fundus fluorescence angiography support the diagnosis.

Keywords: Best disease, Fundus fluorescence angiography, Optical coherence tomography

INTRODUCTION:

Inherited macular dystrophies are arbitrarily classified on the basis of their tissue of origin into those originating from choroid, Bruch's membrane, retinal pigment epithelium (RPE) alone, photoreceptors and RPE, and nerve fibre layers. Best disease, also termed as vitelliform macular dystrophy, is a separate entity among the inherited macular dystrophies. It was first reported by Adam and the first pedigree was described by Dr. Friedrich Best, a German ophthalmologist, in 1905.[1] It is a rare autosomal dominant disorder with incomplete penetrance and variable expression which typically present in childhood involving the long arm of chromosome 11

(11q12- q13).[1,2,3] Usually the fundus lesions are bilateral (yellow or orange egg-yolk appearance) at the macula but can be unilateral. Many individuals with Best disease are asymptomatic initially but the yellow material is gradually resorbed over time, leaving atrophic area of the RPE and often followed by subretinal fibrosis. The diagnostic test for Best disease is Electrooculogram (EOG) with abnormal Arden ratio. Optical Coherence Tomography (OCT), Fundus Fluorescence Angiography (FFA) and full-Field Electro-retinograph (ERG) are the tests done to support the diagnosis. Here we report a case of Best disease with bilateral presentation.

CASE REPORT:

A 35 years old male presented to our retina department with chief complaint of blurring of vision of both eyes for the last three months. There were no other complaints. He did not give history of any trauma, redness, watering or discharge from

Submitted: 19 February, 2020

Accepted: 20 April, 2020

Published: 21 May, 2020

a - Consultant Ophthalmologist

b- Optometrist,

c- Sagarmatha Choudhary Eye Hospital, Siraha, Lahan, Nepal

d- Dristi Eye Hospital, Birgunj, Nepal

Corresponding Author:

Dr. Sharad Gupta

E-mail: sharadgupta00839@gmail.com

ORCID: <https://orcid.org/0000-0001-8654-5172>

How to cite this article:

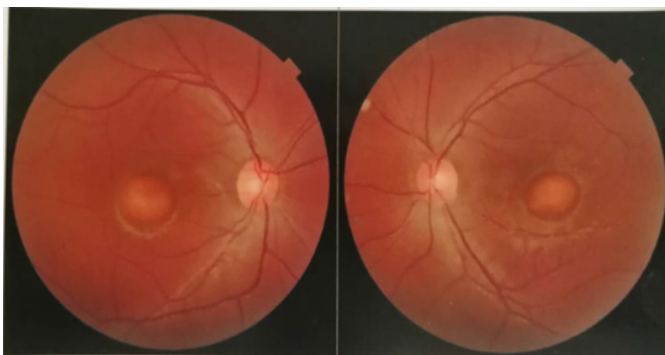
Gupta S, Sharma H, Yadav R, Singh SK, Chaudhary S. Adult Onset Best Vitelliform Macular Dystrophy: A Case Report. *Journal of Lumbini Medical College*. 2020;8(1):3pages. DOI: <https://doi.org/10.22502/jlmc.v8i1.316> Epub: 2020 May 21.



Licensed under CC BY 4.0 International License which permits use, distribution and reproduction in any medium, provided the original work is properly cited.

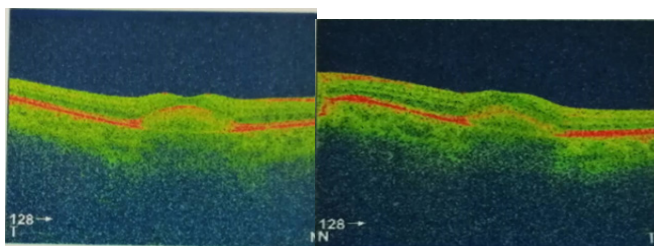
either eye. He had no significant past ocular or systemic histories. There was no similar history in his family members. On examination his presenting visual acuity was 6/12 in each eye.

Visual acuity did not improve even with pinhole or best refractive correction. On slit-lamp examination, anterior segments of both eyes were unremarkable. On posterior segment evaluation, fundus of both eyes revealed a normal well- defined vertically oval optic disc along with single, yellow or orange well-circumscribed dome shaped egg-yolk like sub-retinal lesion approximately disc diameter in size at macula(Figs. 1a and 1b).



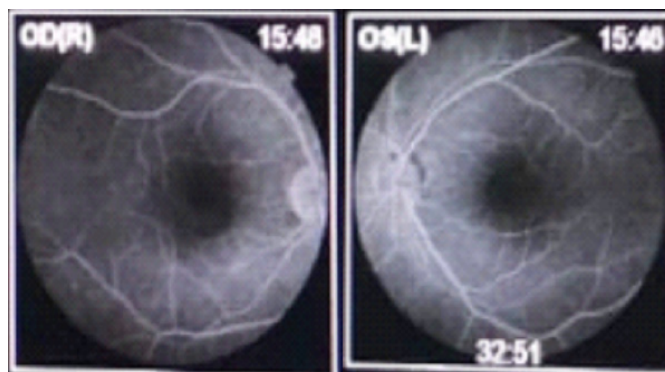
Figs 1a and 1b: Right and left fundus showing yellow or orange well-circumscribed dome shaped egg-yolk like sub-retinal lesion approximately disc diameter in size at macula.

Intraocular pressure of both the eyes were within reference limit. With above history and clinical findings Best's vitelliform macular dystrophy was suspected and the patient was investigated with OCT and FFA. OCT revealed deposit of homogenous hyper-reflective lesion beneath RPE at macula showing RPE disruption and thickening suggestive of pigment accumulation (Figs. 2a and 2b).



Figs. 2a and 2b: OCT of both eyes revealed deposit of homogenous hyper-reflective lesion beneath retinal pigment epithelium at macula showing RPE disruption and thickening suggestive of pigment accumulation.

FFA showed blocked fluorescence at the site of vitelliform lesion of both eyes (Figs. 3a and 3b).



Figs 3a and 3b: Fundus fluorescence angiography showed blocked fluorescence at the site of vitelliform lesion of both eyes.

The EOG and full-field ERG were not done due to unavailability of the test in our hospital. The patient was diagnosed as a case of Best vitelliform macular dystrophy and advised for follow-up yearly.

DISCUSSION

Best vitelliform macular dystrophy is a rare autosomal dominant disorder of unknown prevalence due to the mutation of BEST1 gene with incomplete penetrance and variable expression.[2] It is characterized by accumulation of heterogeneous material between RPE and Bruch's membrane, which is likely derived from the degenerating RPE cells containing lipofuscin.[4] It typically affects young patients in whom a macular lesion gradually evolves through several characteristic stages.

Mohler and Fine classified the evolution of Best disease in different stages:[5]

Stage 0: Normal macula with abnormal EOG.

Stage I: Disturbance of the RPE of the macula.

Stage II: Typical vitelliform or egg yolk lesion.

Stage IIa: Break up of the vitelliform cyst or scrambled egg phase.

Stage III: Pseudo-hypopyon phase where yellow material forms a fluid level in the vitelliform cyst.

Stage IVa: Atrophy of pigment epithelium and possibly retina produces an orange-red lesion in the macula.

Stage IVb: White hypertrophic scar of fibrous tissue in the macula.

Stage IVc: Neovascularization of the fibrous scar.

In Best disease mutation in BEST 1 gene disturbs the ion transport resulting in accumulation of lipofuscin materials and fluid between RPE and photoreceptors.[6] Visual function generally remains good until the disease process progresses to cause disruption of photoreceptors and RPE and structural alterations in the outer retinal layers. Similarly, lesions in Best disease are frequently single and central but there are few reports which describe multiple peripheral lesions outside the macula and posterior pole.[7] Best disease could be diagnosed clinically but EOG is the diagnostic test for it which is abnormal in all stages.

Other tests such as full field ERG, OCT, and FFA are done to support the diagnosis. In our case the electrophysiological test was not done due to unavailability of test in our hospital. There is no definite treatment to slow the progression of this disorder. The role of antioxidant supplementation in Best disease is of only theoretical benefit.[8] The patient of Best disease along with choroidal neovascularization should be treated with either photodynamic therapy or intra- vitreal anti-vascular endothelial growth factors.

CONCLUSION

Best vitelliform macular dystrophy is a rare autosomal dominant disorder. Visual function is good in the early stage but gradually decreases in the late stage. There is no effective treatment available to slow the progression of Best disease. Long term follow up is recommended to see the development of choroidal neo-vascularisation that may have to be treated using intra- vitreal anti-vascular endothelial growth factors or photodynamic therapy.

Conflict of interest: Authors declare that no competing interest exists.

Funding: No funds were available for the study.

REFERENCES:

1. Deutman AF, Hoyng CB. Macular Dystrophies. In: Schachat AP, Hengst TC. (eds.) Medical Retina. 3rd ed. London: Mosby; 2001. p.1225
2. Querques G, Zerbib J, Santacroce R, Margaglione M, Delphin N, Rozet JM, et al. Functional and clinical data of Best vitelliform macular dystrophy patients with mutations in the BEST1 gene. *Mol Vis.* 2009;15:2960-72. PMID: 20057903
3. Stone EM, Nichols BE, Sterb LM, Kimura AE, Sheffield VC. Genetic linkage of vitelliform macular degeneration (Best's disease) to chromosome 11q13. *Nat Genet.* 1992;1(4):246-50. PMID: 1302019. DOI: <https://doi.org/10.1038/ng0792-246>
4. Frangieh GT, Green WR, Fine SL. A histopathologic Study of Best's Macular Dystrophy. *Arch Ophthalmol.* 1982;100(7):1115-21. PMID: 7092655. DOI: <https://doi.org/10.1001/archophth.1982.01030040093017>
5. Mohler CW, Fine SL. Long-term evaluation of patients with Best's vitelliform dystrophy. *Ophthalmology.* 1981;88(7):688-92. PMID: 7267039. DOI: [https://doi.org/10.1016/s0161-6420\(81\)34965-3](https://doi.org/10.1016/s0161-6420(81)34965-3)
6. Hartzell HC, Qu Z, Yu K, Xiao Q, Chien LT. Molecular physiology of bestrophins: multifunctional membrane proteins linked to best disease and other retinopathies. *Physiol Rev.* 2008;88(2):639-72. PMID: 18391176. DOI: <https://doi.org/10.1152/physrev.00022.2007>
7. Weingeist TA, Kobrin J, Watzke RC. Histopathology of Best's macular dystrophy. *Arch Ophthalmol.* 1982;100(7):1108-14. PMID: 7092654. DOI: <https://doi.org/10.1001/archophth.1982.01030040086016>
8. Schmitz-Valckenberg S, Holz FG, Bird AC, Spaide RF. Fundus autofluorescence imaging: review and perspectives. *Retina.* 2008;28(3):385-409. PMID: 18327131. DOI: <https://doi.org/10.1097/IAE.0b013e318164a907>