

Mandibular parameters as a predictor of sex: A digital orthopantomogram study

Ojha B,¹ Bajracharya D,² Koju S,³ Maharjan N,³ Saha A,⁴ Baral R⁵

¹Bidhata Ojha, Lecturer; ²Dipshikha Bajracharya, Associate Professor; ³Sushmit Koju, ³Nisha Maharjan, Postgraduate Resident, Department of Oral Pathology; ⁴Ankit Saha, Lecturer, Department of Oral Medicine and Radiology, Kantipur Dental College and Hospital, Basundhara, Kathmandu, Nepal; ⁵Radha Baral, Lecturer, Department of Oral Pathology, Institute of Medicine, Maharajgunj, Kathmandu, Nepal.

Abstract

Background: The determination of age and sex is required for forensic practice and medicolegal purposes. Because the mandible is typically recovered intact, it plays a crucial role in determining sex. Orthopantomogram X-rays can be used to thoroughly examine the mandible. The availability of a large number of antemortem orthopantomograms could be extremely beneficial in terms of evaluating and developing population-specific sex determination standards.

Objectives: To evaluate the usefulness of the mandibular ramus in sex determination by evaluating linear and angular measurements of the mandibular ramus on digital panoramic radiographs.

Methods: An analytical cross-sectional study was conducted on 216 digital orthopantomogram from March 2021 to June 2021 in Kantipur Dental College. A convenient sampling technique was used to collect the radiographs. Mandibular parameters were traced using Image J Software, and angular and linear parameters were calculated. Radiographs with high image quality and sharpness of patients with full permanent dentition, no radiographic evidence of trauma were included in the study. Descriptive analysis was done using IBM SPSS Statistics for Windows, version 20 (IBM Corp., Armonk, N.Y., USA). The measures were compared using an Independent t-test, and the results were subjected to discriminant function analysis.

Results: The male's vertical parameters were found to be greater than the female's. The coronoid height was shown to be the most dimorphic using discriminant analysis. The overall accuracy of the mandibular parameters was 63.4%.

Conclusion: Mandible can be used as an adjunct in sex determination.

Key words: Dimorphism; Gender; Mandible; Panoramic radiography.

Access this article online

Website: www.jkmc.com.np

DOI: <https://doi.org/10.3126/jkmc.v10i4.43862>

HOW TO CITE

Ojha B, Bajracharya D, Koju S, Maharjan N, Saha A, Baral R. Mandibular parameters as a predictor of sex: A digital orthopantomogram study. *J Kathmandu Med Coll.* 2021;10(4):218-23.

Submitted: Dec 6, 2021

Accepted: Feb 27, 2022

Published: Mar 24, 2022

Address for correspondence

Dr. Bidhata Ojha
Lecturer, Department of Oral Pathology
Kantipur Dental College and Hospital,
Basundhara, Kathmandu, Nepal.
E-mail: bidhataojha@gmail.com

Copyright © 2021 Journal of Kathmandu Medical College (JKMC)

ISSN: 2019-1785 (Print), 2091-1793 (Online)

INTRODUCTION

The mandible is the largest and most powerful bone in the head and neck region, and it is sexually dimorphic. Its morphology shifts with age and tooth loss, manifested by a widening of the mandible's angle. Among the various parameters of the mandible gonial angle has a significant role in sex determination. The gonial angle refers to the angle of the mandible.^{1,2} It can be measured radiographically using orthopantomogram (OPG). Panoramic radiograph has additional advantage over other dentofacial radiographs as it shows the entire maxillary and mandibular structures in a single film.¹ Sex determination of the skeleton is often found to be superior to other methods of sex determination due to its higher accuracy and lower inter and intraobserver variations.^{3,4} The goal of this study was to evaluate linear and angular measurements of the mandibular



This work is licensed under a Creative Commons Attribution-Non Commercial 4.0 International License.

ramus using digital panoramic radiographs in order to determine the usefulness of the mandibular ramus in determining sex.

METHODOLOGY

An analytical cross-sectional study was conducted from March 2021 to June 2021 in Kantipur Dental College and Research Centre, Basundhara, Kathmandu, Nepal. The study was conducted after taking approval from Institutional Review Committee (Ref. 04/021). The study population was OPG of the patients visiting Kantipur Dental College and Research Centre for routine radiographic examination. Radiographs with high image quality and sharpness of patients with full permanent dentition, no radiographic evidence of trauma were included in the study. Any pathological or developmental disturbances visible in the OPG were excluded from the study. Each patient was exposed to panoramic X-ray by Carestream (CS9300, Kodak) at 74Kv, 12 mA for 14.3 seconds. The sample size was calculated using the following formula $Z^2 SD^2/d^2$ taking 10% error; where $Z = 1.96$; $SD = 0.7$;⁵ and $d = 0.1$. The obtained sample size was 216 OPGs.

A convenient sampling technique was used. Two hundred and sixteen OPGs were exported in Image J software version 1.53a. Linear and angular parameters were traced using the same software (Figure 1). Calibration was done for 1:1 magnification. Linear and angular measurements were determined as follows:⁴

- A) Maximum ramus breadth: Horizontal distance between the most anterior to most posterior point of the ramus
- B) Minimum ramus breadth: Smallest horizontal distance between the anterior and posterior point of the ramus.
- C) Condylar ramus height: Height of the ramus from condyle to the most protruding point on the inferior border of the ramus.
- D) Coronoid ramus height: Height of the ramus from the coronoid process to the most protruding point on the inferior border of the ramus.
- E) Projective ramus height: Projective height from condyle to lower margin of the bone.
- F) Gonial angle: Angle formed with a tangent to lower border of the mandible and another line tangent to the distal border of the ascending ramus.
- G) Intergonial width: Horizontal distance between gonion of both sides.

Data were entered in Microsoft Excel sheet, and descriptive analysis was done using IBM Statistical

Package for the Social Sciences (SPSS) Statistics for Windows, version 20 (IBM Corp., Armonk, N.Y., USA). An Independent t-test was used to evaluate the measurements between the groups and the measurements were subjected to discriminant function analysis.

RESULTS

The study included 216 OPG X-rays (126 females and 90 males). Patients' age ranged from 17 to 39 years (22.76 ± 5.00 years). The mean value for males and females showed a slight difference. The condylar height, coronoid height, and projective height of the ramus were greater in males on both the right and left sides. Maximum ramus breadth and gonial angle were greater in females than males on both sides (Table 1).

An Independent sample t-test was used to compare the mean values from the right and left sides and among the sexes. The Independent t-test compared the measurements of the two sides. It showed a significant difference between condylar height and projective ramus height ($p < 0.05$) (Table 2).

The comparison among the sexes showed no statistically significant difference among males and females on both sides (Table 3). The intergonial width of both males and females was also not significantly different ($p = 0.806$).

Discriminant analysis was conducted to evaluate predictors that best discriminate between the sexes based on the mandibular parameters. The F-statistic values indicated that mandibular measurements expressing the greatest dimorphism was coronoid height followed by gonial angle and projective ramus height. The parameter showing the least dimorphism was minimum ramus breadth (Table 4).

The standardised and unstandardised discriminant function coefficients, structure matrix, and group centroids. The Canonical Discriminant Function Coefficients was used to create the discriminant function (equation):

The discriminant function = $2.152 + (0.092 * \text{maximum ramus breadth}) + (-0.069 * \text{minimum ramus breadth}) + (0.166 * \text{condylar height}) + (-0.152 * \text{coronoid height}) + (-0.097 * \text{projective ramus height}) + (0.005 * \text{gonial angle}) + (0.008 * \text{intergonial width})$

The sectioning point obtained was -0.03. If the value is more than the sectioning point, sex is predicted as female and if the value is less, the sex is predicted as male. The

classification results revealed that 126 (91.3%) of females were classified into females. Females were classified with

better accuracy 115 (91.3%) than males 68 (75.6%). By considering all these variables, parameters showed an overall accuracy of 63.4% (Table 5).

Table 1: Descriptive data of the variables

	Male (90)			Female (126)		
	Right Mean ± SD	Left Mean ± SD	Mean ± SD	Right Mean ± SD	Left Mean ± SD	Mean ± SD
Maximum ramus breadth	48.87 ± 8.18	49.07 ± 8.57	48.87 ± 8.19	49.10 ± 7.63	50.06 ± 7.93	49.11 ± 7.63
Minimum ramus breadth	42.68 ± 7.19	42.59 ± 7.48	42.68 ± 7.19	42.67 ± 6.46	43.23 ± 9.47	42.68 ± 6.46
Condylar height	107.69 ± 18.68	112.73 ± 19.28	107.70 ± 18.68	107.09 ± 16.81	112.08 ± 16.57	107.10 ± 16.82
Coronoid height	92.20 ± 13.34	92.90 ± 13.15	92.20 ± 13.35	90.44 ± 12.46	91.16 ± 12.58	90.45 ± 12.47
Projective ramus height	101.01 ± 15.87	104.05 ± 16.06	101.01 ± 15.88	99.66 ± 15.40	102.80 ± 15.60	99.67 ± 15.40
Gonial angle	122.16 ± 7.51	122.08 ± 10.02	122.16 ± 7.52	132.26 ± 98.05	124.92 ± 10.97	132.26 ± 98.05
Intergonial width	-	-	198.96 ± 22.92	-	-	198.21 ± 21.50

Table 2: Independent t-test to compare between right and left side

	Location	Mean ± SD	t	Sig. (2-tailed)
Maximum ramus breadth	Right	49.01 ± 7.85	-0.83	0.41
	Left	49.65 ± 8.20		
Minimum ramus breadth	Right	42.68 ± 6.76	-0.38	0.70
	Left	42.97 ± 8.69		
Condylar height	Right	107.35 ± 17.58	-2.95	<0.05
	Left	112.36 ± 17.71		
Coronoid height	Right	91.18 ± 12.84	-0.57	0.57
	Left	91.89 ± 12.82		
Projective ramus height	Right	100.23 ± 15.58	-2.05	<0.05
	Left	103.33 ± 15.77		
Gonial angle	Right	128.05 ± 75.09	0.84	0.40
	Left	123.74 ± 10.66		

Table 3: Independent t-test to compare gender (right and left side)

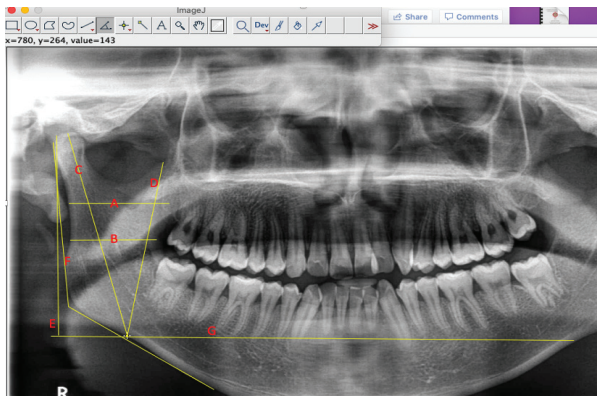
	Gender	Right		Sig	Left		Sig
		Mean ± SD	t		Mean ± SD	t	
Maximum ramus breadth	Female	49.10 ± 7.6	0.213	0.832	50 ±	0.875	0.382
	Male	48.87 ± 8.1			49.07 ±		
Minimum ramus breadth	Female	42.67 ±	-0.004	0.996	43.23 ±	0.532	0.596
	Male	42.68 ±			42.5		
Condylar height	Female	107.09	-0.244	0.808	112.08	-0.258	0.796
	Male	107.69			112.73		
Coronoid height	Female	90.44	-0.989	0.324	91.16	-0.983	0.327
	Male	92.20			92.90		
Projective ramus height	Female	99.66	-0.624	0.535	102.8	-0.570	0.569
	Male	101			104.05		
Gonial angle	Female	132.26	0.975	0.331	124.92	1.946	0.053
	Male	122.16			122.08		

Table 4: Descriptive analysis

	Wilks' Lambda	F	Standardised Canonical Discriminant Function Coefficients	Structure Matrix	Canonical Discriminant Function Coefficients	Centroid (sectioning point)
Maximum ramus breadth	1.000	0.045	0.725	0.082	0.092	F=.150 M=-.210 (-0.03)
Minimum ramus breadth	1.000	0.000	-0.467	-0.002	-0.069	
Condylar height	1.000	0.061	2.923	-0.095	0.166	
Coronoid height	0.995	0.979	-1.955	-0.380	-0.152	
Projective ramus height	0.998	0.390	-1.517	-0.240	-0.097	
Gonial angle	0.996	0.950	0.340	0.374	0.005	
Intergonial width	1.000	0.061	0.168	-0.095	0.008	
(Constant)					2.152	

Table 5: Accuracy

True group	Predicted Group		Total	Accuracy (%)	Overall accuracy
	Female	Male			
Female	115	11	126	91.3	63.4%
Male	22	68	90	75.6	

**Figure 1: Figure showing linear and angular measurements**

DISCUSSION

Sex determination by human skeletal remains is considered an initial step in Disaster Victim Identification (DVI). When an entire skeleton is found, sex determination by forensic examination gives 100% accuracy. In case of mass disasters where only fragmented or skeletonised remains are found establishment of human identification with 100% accuracy may not be possible. Gender determination with a skeleton is often found superior because of a higher accuracy rate.⁴

The present study evaluated the mandibular parameters which included both the linear and angular measurements. The parameters compared on both the sides showed the ramus breadth (maximum and minimum), coronoid height, and gonial angle

to be statistically insignificant. The condylar height and projective height of the ramus had statistically significant values ($p < 0.05$). According to Akcam et al.⁶ OPG provides information on the angular and vertical dimensions of craniofacial features, but it is not as accurate as a lateral cephalogram. The study showed variations mainly in the vertical dimensions. not on the horizontal parameters and angular measurement (gonial angle) as it was statistically insignificant, indicating the reliability of the OPG for measuring those parameters. Study performed by Shahabi et al.⁷ concluded that in Class I patients, the external gonial angle was compared in lateral cephalograms and panoramic radiographs and panoramic radiography was as accurate as a lateral cephalogram in determining the gonial angle.

Both magnification flaws and displacement have been seen to impact the panoramic image. Because of the non-linear fluctuation in magnification at different object depths, horizontal distances are particularly inaccurate, although vertical distances are rather reliable.⁸ However, the measurements still are not the true representation of the real objects. The inherent unavoidable drawbacks in the orthopantomographic techniques such as distortion and magnification factors cannot be eliminated if the image is sharp.⁹ Ramstad et al.⁹ suggest that quantitative measurements on panoramic radiographs should not be encouraged.

The condylar height, coronoid height, and projective height of the ramus were greater in males on both the

right and left sides. A study showed that males have a larger ramus height and bigonial width than females¹⁰ similar to current study. But the measurements were not statistically significant. Maximum ramus breadth and gonial angle were greater in females than males on both sides. However, these parameters were not statistically significant. The gonial angle on the right was 128.05 ± 75.09 and 123.74 ± 10.66 on the left. Evaluation of gonial angle in conventional OPG among the skeletal Class I in the same institution showed gonial angle to be 120.86 ± 7.35 on the right of OPG and 120.73 ± 7.11 on the left side of OPG.¹¹ The results of current study showed greater degrees of the gonial angle among the females on both the sides. A similar result was obtained in the study by Leversha et al.¹⁰ where females have a significantly larger gonial angle than males ($p < 0.0002$).

Gender-related differences vary among regional populations, necessitating the need for population-specific standards to predict sex accurately.⁴ Studies have found that sex differences exist in the ramus height.⁴ Dayal et al.¹² found mandibular ramus height to be the best parameter with an accuracy of 75.8%.

The results showed that the coronoid height has the highest sexual dimorphism. Saini et al.⁴ and Sambhana et al.¹³ reported that the coronoid height expressed the greatest dimorphism. Other studies have reported different mandibular parameters as the most dimorphic; condylar height,¹⁴ minimum ramus breadth,¹⁵ projective height of ramus.¹⁶ Studies among the subjects with

malnutrition observed a lower degree of dimorphism.¹⁷ It has been established that socio-economic factors influence the development and appearance of the bones.⁴ The overall accuracy in predicting gender was found to be 63.4%. The prediction rate for females was greater than for males. One hundred fifteen cases were predicted accurately out of 126 females with an accuracy rate of 91.3% and 68 males among 90 with an accuracy rate of 75.6%. Similar study on conventional OPG showed an overall accuracy of 65.0%.¹⁸ Other studies have variable prediction accuracy; 69%,¹⁹ 75.4%,¹⁴ 80.2%.⁴

It is limitation of this study that male samples were less in comparison to female. The study could have been done in larger population.

CONCLUSION

The present study shows that mandibular vertical height can be used as a reliable tool for sex determination. It can be utilised in forensic casework when bodies beyond visual recognition and skeletonised remains are recovered.

ACKNOWLEDGEMENT

The authors would like to acknowledge Dr. Sunita Khanal, Department of Community Dentistry for her constant help during the study.

Conflict of interest: None

Source(s) of support: None

REFERENCES

- Pillai JP, Shah RJ, Darji B, Banker A, Pillai RJ. Association of the gonial angle with age, gender, and dental status: A radiographic study using lateral cephalogram and orthopantomogram. *J Forensic Radiol Imaging*. 2018;15(August):8-13. [Full Text | DOI]
- Alfawzan AA. Gonial Angle as a determinant of gender, a panoramic study in a sample of Saudi population. *Indian J Public Health Res Dev*. 2020;11(1):1689. [Full Text | DOI]
- Abuhijleh E, Warreth A, Qawadi M, Abdulrida E, Radaideh A, Al Taki A, et al. Mandibular gonial angle measurement as a predictor of gender - A digital panoramic study. *Open Dent J*. 2019;13(1):399-404. [Full Text | DOI]
- Saini V, Srivastava R, Rai RK, Shamal SN, Singh TB, Tripathi SK. Mandibular ramus: An indicator for sex in fragmentary mandible. *J Forensic Sci*. 2011;56(SUPPL.1):S13-6. [PubMed | Full Text | DOI]
- Abu-Taleb NS, El Beshlawy DM. Mandibular ramus and gonial angle measurements as predictors of sex and age in an Egyptian population sample: A digital panoramic study. *J Forensics Res*. 2015;06(05):308. [Full Text | DOI]
- Akcam MO, Altiokt T, Ozdiler E. Panoramic radiographs: a tool for investigating skeletal pattern. *Am J Orthod Dentofacial Orthop*. 2003 Feb;123(2):175-81. [PubMed | Full Text | DOI]
- Shahabi M, Ramazanzadeh BA, Mokhber N. Comparison between the external gonial angle in panoramic radiographs and lateral cephalograms of adult patients with Class I malocclusion. *J Oral Sci*. 2009 Sep;51(3):425-9. [PubMed | Full Text | DOI]
- Srivastava A, Raghav P, Pradhan S. Effectiveness of orthopantomograph in vertical mandibular measurements: A systematic review. *J Oral Maxillofac Radiol*. 2021 May 1;9(2):45-51. [Full Text | DOI]
- Ramstad T, Hensten-Pettersen O, Mohn E, Ibrahim SI. A methodological study of errors in vertical

- measurements of edentulous ridge height on orthopantomographic radiograms. *J Oral Rehabil.* 1978 Oct;5(4):403-12. [[PubMed](#) | [Full Text](#) | [DOI](#)]
10. Leversha J, McKeough G, Myrteza A, Skjellrup-Wakefield H, Welsh J, Sholapurkar A. Age and gender correlation of gonial angle, ramus height and bigonial width in dentate subjects in a dental school in Far North Queensland. *J Clin Exp Dent.* 2016 Feb 1;8(1):e49-54. [[PubMed](#) | [Full Text](#) | [DOI](#)]
 11. Rajak R, Shrestha R, Koju S. Reliability of panoramic radiography in assessing gonial angle compared to lateral cephalogram in patients with class I malocclusion. *Taiwanese Journal of Orthodontics.* 2021 Aug 18;33(2):53-9. [[Full Text](#) | [DOI](#)]
 12. Dayal M, Spocter M, Bidmos M. An assessment of the skull of black South Africans by discriminate function analysis. *Homo: internationale Zeitschrift für die vergleichende Forschung am Menschen.* 2008 Feb 1;59:209-21. [[PubMed](#) | [Full Text](#) | [DOI](#)]
 13. Sambhana S, Sanghvi P, Mohammed RB, Shanta PP, Thetay AAR, Chaudhary VS. Assessment of sexual dimorphism using digital orthopantomographs in South Indians. *J Forensic Dent Sci.* 2016 Dec;8(3):180. [[PubMed](#) | [Full Text](#) | [DOI](#)]
 14. Ranaweera WGPE, Chandrasekara CMCTK, Hraputhanthiri HDS, Silva PD, Herath LHMIM. Sex determination by mandibular ramus – A digital panoramic study. *Sri Lanka J Forensic Med Sci Law.* 2020 May 17;11(1):10-9. [[Full Text](#) | [DOI](#)]
 15. Indira AP, Markande A, David MP. Mandibular ramus: An indicator for sex determination – A digital radiographic study. *J Forensic Dent Sci.* 2012;4(2):58-62. [[PubMed](#) | [Full Text](#) | [DOI](#)]
 16. Samatha K, Byahatti SM, Ammanagi RA, Tantradi P, Sarang CK, Shivpuje P. Sex determination by mandibular ramus: A digital orthopantomographic study. *J Forensic Dent Sci.* 2016;8(2):95-6. [[PubMed](#) | [Full Text](#) | [DOI](#)]
 17. Galdames ICS, Matamala DAZ, Smith RL. Evaluating accuracy and precision in morphologic traits for sexual dimorphism in malnutrition human skull: A comparative study. *Int J Morphol.* 2008;26(4):876-83. [[Full Text](#) | [DOI](#)]
 18. Koju S, Maharjan N, Rajak RRR, Yadav DK, Bajracharya D, Ojha B. Assessment of sexual dimorphism in mandibular ramus: An orthopantomographic study. *Kathmandu Univ Med J.* 2021;75(3):314-9. [[Full Text](#)]
 19. More CB, Vijayvargiya R, Saha N. Morphometric analysis of mandibular ramus for sex determination on digital orthopantomogram. *J Forensic Dent Sci.* 2017 Apr;9(1):1-5. [[PubMed](#) | [Full Text](#) | [DOI](#)]