

# Relative position of mandibular foramen for inferior alveolar nerve block in children: A digital panoramic radiographic study

Upadhyay S,<sup>1</sup> Poudyal S,<sup>2</sup> Mahanta SK,<sup>3</sup> Bali H,<sup>4</sup> Luitel A,<sup>5</sup> Niroula D<sup>6</sup>

<sup>1</sup>Sumita Upadhyay, Associate Professor, Department of Paediatric and Preventive Dentistry, Kathmandu University School of Medical Sciences, Dhulikhel Hospital, Dhulikhel, Kavrepalanchok, Nepal; <sup>2</sup>Sijan Poudyal, Associate Professor, Department of Community Dentistry, People's Dental College and Hospital, Sorhakutte, Kathmandu, Nepal; <sup>3</sup>Swagat Kumar Mahanta, Assistant Professor, Department of Community Dentistry; <sup>4</sup>Harleen Bali, Assistant Professor, <sup>5</sup>Abhinaya Luitel, Lecturer, Department of Oral Medicine and Radiology; Kathmandu University School of Medical Sciences, Dhulikhel Hospital, Dhulikhel, Kavrepalanchok, Nepal; <sup>6</sup>Deepa Niroula, Lecturer, Department of Oral Medicine and Radiology, Institute of Medicine, Maharajgunj, Kathmandu, Nepal.

## Abstract

**Background:** For a successful inferior alveolar nerve block, good knowledge of position of mandibular foramen is imperative.

**Objectives:** To evaluate the position of mandibular foramen in relation to mandibular occlusal plane and anterior border of ramus in a selected population of children in Nepal using digital panoramic radiographs.

**Methods:** An analytical cross-sectional study was done after ethical approval in convenient sample of 180 children of 3-13 years in department of Paediatric and Preventive Dentistry, Dhulikhel Hospital from January 2021 to August 2021. Their digital panoramic radiographs were analysed using software Rainbow TM Image Viewer version 1.0.0.0. Mean with standard deviation were calculated for linear measurements taken from mandibular foramen to mandibular occlusal plane and deepest point on the anterior border of ramus. Paired t-test was used to compare measurements between right and left sides. Student t-test was used to evaluate the difference between boys and girls. Pearson correlation was used to observe the correlation of age with the linear measurements.

**Results:** The mean linear measurements increased along with the increase in age ( $p < 0.05$ ). There was statistically significant difference in linear measurements between the two sides of mandible except in 3-4 years children for mandibular foramen to anterior border of ramus which was not significant ( $p = 0.090$ ). There was no significant difference in linear measurements between boys and girls.

**Conclusion:** For inferior alveolar nerve block, the needle should be placed below the occlusal plane in children up to seven years of age and above for higher ages.

**Key words:** Inferior alveolar nerve block; Mandibular foramen; Occlusal plane; Panoramic radiograph.

## Access this article online

**Website:** [www.jkmc.com.np](http://www.jkmc.com.np)

**DOI:** <https://doi.org/10.3126/jkmc.v10i4.43858>

## HOW TO CITE

Upadhyay S, Poudyal S, Mahanta SK, Bali H, Luitel A, Niroula D. Relative position of mandibular foramen for inferior alveolar nerve block in children: A digital panoramic radiographic study. *J Kathmandu Med Coll.* 2021;10(4):181-7.

**Submitted:** Dec 27, 2021

**Accepted:** Feb 2, 2022

**Published:** Mar 24, 2022

Copyright © 2021 Journal of Kathmandu Medical College (JKMC)

**ISSN:** 2019-1785 (Print), 2091-1793 (Online)



This work is licensed under a Creative Commons Attribution-Non Commercial 4.0 International License.

## INTRODUCTION

Pain control in children during dental procedure is an important facet of behaviour guidance. Inferior alveolar nerve block (IANB) for pain control is the most commonly used anaesthetic technique for mandible. The technique targets deposition of local anaesthetic agent very close to the mandibular foramen (MF).<sup>1</sup> Studies have

## Address for correspondence

Dr. Sumita Upadhyay  
Associate Professor and Head,  
Department of Paediatric and Preventive Dentistry,  
Kathmandu University School of Medical Sciences,  
Dhulikhel Hospital, Dhulikhel, Kavrepalanchok, Nepal.  
E-mail: [drsumipedo@gmail.com](mailto:drsumipedo@gmail.com)

found that the position of mandibular foramen changes according to the growth. Also, the dentofacial structures varies according to race, ethnic group, and between the two sides of the same individual.<sup>2,3</sup>

Successful IANB is difficult to achieve due to the accessory innervation and mostly due to inappropriate position of needle insertion as a result of faulty assessment of landmarks.<sup>4</sup> Thus, it is essential to have a good knowledge about the change in the position of mandibular foramen. Panoramic radiograph is a very useful tool in determining the position of mandibular foramen. Compared to other recent imaging techniques, it is simple to obtain, cost-effective with minimal time consumption.<sup>5</sup>

To the best of authors' knowledge, there is no literature in Nepali children on the location of mandibular foramen. Hence, this research was carried out to evaluate the relative position of mandibular foramen in selected population of children in Nepal using digital panoramic radiographs.

## METHODOLOGY

An analytical cross-sectional study was conducted in the department of Paediatric and Preventive Dentistry, Kathmandu University School of Medical Sciences, Dhulikhel Hospital, Dhulikhel, Kavrepalanchok, Nepal from January 2021 to August 2021. Prior ethical approval for the research was obtained from Institutional review committee, Kathmandu University School of Medical Sciences (Ref. 137/20).

Sample size was calculated using the formula  $z^2\sigma^2/d^2$  keeping 95% confidence interval and  $\sigma = 1.64$ .<sup>6</sup> Keeping 0.25 mm as permissible error,  $n = 165.32 (\approx 166)$ . The present study consisted of 180 convenient sample. Children of ages 3-13 years who visited Paediatric and Preventive Dentistry department of Dhulikhel Hospital during the study period for dental treatment and requiring panoramic radiograph were included in the research. The sample was selected on certain inclusion criteria: healthy children of ages three years to 13 years, good quality panoramic radiographs, and children whose parents gave informed consent. Exclusion criteria were: children with growth related disorder, any congenital or genetic abnormalities, previous orofacial trauma, presence of any gross pathology, and poor-quality panoramic radiographs. Date of birth of the patient and date of radiograph taken was recorded by receptionist of Paediatric and Preventive Dentistry department to

record chronological age along with sex. Children were divided in groups as per Hellman's dental developmental stages (Table 1).<sup>7</sup>

Digital panoramic radiographs were recorded by a radiology technician in a single machine; Rainbow TM CT in 80kVp, 7.0Ma and scan time was 17 seconds. The obtained image was viewed and analysed in Rainbow TM Image Viewer version 1.0.0.0. The required landmarks were traced by a single investigator (SU) for both right and left sides of the mandible. To decrease the visual errors, only five radiographs were analysed in a day. The points and planes that were analysed are depicted in Figure 1.

Linear measurements of MF-OP and MF-ABR in millimeter were recorded for both right and left sides. Investigator was blinded for chronological age and sex of the patient.

The data were entered and analysed using IBM Statistical Package of Social Sciences (SPSS) Statistics for Windows, version 25 (IBM Corp., Armonk, N.Y., USA). Mean and standard deviation was calculated for MF-OP and MF-ABR in all the stages. Paired t-test was used to compare the linear measurements between right and left sides. Student t-test was used to evaluate the gender difference for the linear measurements from stage IIA to IVA between the two sides. Pearson's correlation coefficient test was done to observe the correlation between age and linear measurements. The level of significance was kept at 0.05.

## RESULTS

The sample consisted of 105 (58.3%) males and 75 (41.7%) females. On comparison of mean linear measurements of MF to mandibular occlusal plane, there was statistically significant difference between right and left sides in all the age groups ( $p < 0.05$ ) (Table 2). Similarly, there was statistically significant difference between right and left sides in the mean linear measurements of relative position of MF to anterior border of ramus except for group 1 which was non-significant ( $p = 0.090$ ) (Table 3). No significant gender difference was seen in the mean linear measurements of MF to occlusal plane and anterior border of ramus on both the sides (Table 4, 5).

Pearson correlation demonstrated that age was strongly correlated with the mandibular variables (MF-OP and MF-ABR) and the value increased along with the increase in age ( $p < 0.05$ ) (Table 6).

**Table 1: Hellman's dental developmental stages**

Group	Age (years)	Hellman's stage	Characteristics
1	3-4	II A	Completion of primary occlusion
2	5-7	II C	Eruptive phase of first permanent molar
3	7-9	III A	Eruptive phase of first permanent molars completed
4	9-12	III B	Exchange of lateral teeth
5	11-12	III C	Eruption of permanent second molars
6	12-13	IV A	Eruption of permanent second molars completed

**Table 2: Comparison of mean linear measurement (mm) of relative position of MF to mandibular occlusal plane between right and left sides**

Group	N	RL1	LL1	p-value	
1	16	-2.36 ± 0.27	-2.28 ± 0.36	0.019	
2	32	-0.85 ± 0.55	-0.85 ± 0.62		
3	42	1.80 ± 0.82	2.01 ± 0.91		
4	61	4.17 ± 0.93	4.51 ± 0.87		<0.001
5	32	4.93 ± 0.53	5.22 ± 0.41		
6	29	5.65 ± 0.31	6.10 ± 0.46		

**Table 3: Comparison of mean linear measurement (mm) of relative position of MF to anterior border of ramus on right and left sides**

Group	N	RL2	LL2	p-value
1	16	10.60 ± 0.47	10.64 ± 0.48	0.090
2	32	12.36 ± 0.35	12.56 ± 0.41	0.011
3	42	13.50 ± 0.28	13.74 ± 0.39	<0.001
4	61	15.40 ± 1.05	15.76 ± 1.07	
5	32	16.24 ± 0.69	16.60 ± 0.71	
6	29	17.86 ± 0.62	18.26 ± 0.57	

**Table 4: Gender difference in all the age groups for the mean linear measurement (mm) of relative position of MF to occlusal plane on both sides**

Group		MF-OP (mm)	p-value
1	RL1	Male	-2.34 ± 0.25
		Female	-2.38 ± 0.33
	LL1	Male	-2.29 ± 0.24
		Female	-2.26 ± 0.53
2	RL1	Male	-0.77 ± 0.59
		Female	-0.93 ± 0.52
	LL1	Male	-0.76 ± 0.69
		Female	-0.94 ± 0.54
3	RL1	Male	1.84 ± 0.80
		Female	1.67 ± 0.91
	LL1	Male	2.05 ± 0.89
		Female	1.87 ± 0.99
4	RL1	Male	4.20 ± 0.95
		Female	4.14 ± 0.93
	LL1	Male	4.50 ± 0.95
		Female	4.52 ± 0.79

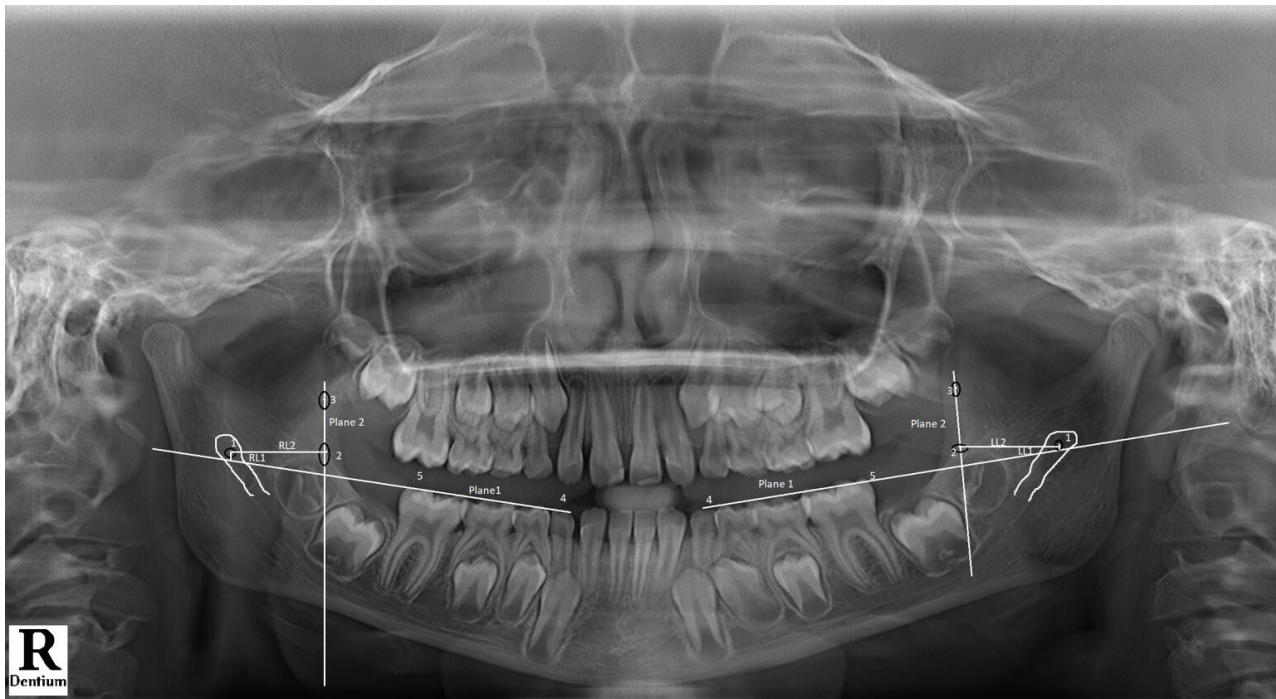
5	RL1	Male	4.94 ± 0.47	0.508	
		Female	4.91 ± 0.62		
	LL1	Male	5.20 ± 0.44		0.959
		Female	5.19 ± 0.39		
6	RL1	Male	5.62 ± 0.27	0.334	
		Female	5.71 ± 0.37		
	LL1	Male	6.10 ± 0.48		0.944
		Female	6.09 ± 0.44		

**Table 5: Gender difference in all the age groups for the mean linear measurement (mm) of relative position of MF to anterior border of ramus on right and left sides**

Group			MF-ABR (mm)	p-value	
1	RL2	Male	10.68 ± 0.43	0.755	
		Female	10.47 ± 0.54		
	LL2	Male	10.69 ± 0.56		0.163
		Female	10.56 ± 0.34		
2	RL2	Male	12.45 ± 0.36	0.474	
		Female	12.26 ± 0.31		
	LL2	Male	12.56 ± 0.43		0.944
		Female	12.57 ± 0.40		
3	RL2	Male	13.53 ± 0.29	0.713	
		Female	13.42 ± 0.26		
	LL2	Male	13.84 ± 0.32		0.166
		Female	13.45 ± 0.44		
4	RL2	Male	15.42 ± 1.01	0.771	
		Female	15.39 ± 1.11		
	LL2	Male	15.73 ± 0.98		0.424
		Female	15.78 ± 1.16		
5	RL2	Male	16.18 ± 0.61	0.906	
		Female	16.32 ± 0.79		
	LL2	Male	16.44 ± 0.61		0.947
		Female	16.77 ± 0.80		
6	RL2	Male	17.87 ± 0.61	0.901	
		Female	17.85 ± 0.67		
	LL2	Male	18.29 ± 0.60		0.841
		Female	18.23 ± 0.55		

**Table 6: Correlation between age and linear measurements (mandibular foramen to occlusal plane and anterior border of ramus) on right and left sides**

		RL1	LL1	RL2	LL2
Age	Pearson correlation	0.988	0.986	0.963	0.980
	p-value	<0.001			
	N	180			



**Figure 1: Panoramic radiograph with points and planes**

- Point 1: Center of the mandibular foramen (MF)
- Point 2: Deepest point on anterior border of ramus (ABR)
- Point 3: Most prominent point on the anterior border of the ramus
- Point 4: Most prominent point on the cusp tip of canine
- Point 5: Most prominent point on the occlusal aspect of posterior fully erupted molar
- Plane 1: Occlusal plane of mandible (OP) connecting point 4 and 5
- Plane 2: Plane connecting point 2 and 3
- RL1: Perpendicular line from point 1 to plane 1 (right side)
- LL1: Perpendicular line from point 1 to plane 1 (left side)
- RL2: Perpendicular line from point 1 to plane 2 (right side)
- LL2: Perpendicular line from point 1 to plane 2 (left side)

## DISCUSSION

Repeated administration of local anaesthesia for failure of IANB in children is difficult due to behaviour issues. Also, there may be risk of overdose of local anaesthesia. To avoid these, it is imperative to locate mandibular foramen for administration of IANB.

In the present study, the relative position of mandibular foramen was evaluated with the aid of two landmarks; occlusal plane of the mandible and deepest point on the anterior border of ramus. Occlusal plane of the mandible gives the estimation of vertical height and deepest point on the anterior border of ramus gives the estimation of the horizontal distance for needle insertion. The findings showed that the position of mandibular foramen changed vertically and horizontally with the age in both genders. Such pattern has been agreed by other authors as well.<sup>8,9</sup>

There was gradual increase in the distance from mandibular foramen to occlusal plane and anterior border of ramus from early primary dentition; stage IIA to late permanent dentition; stage IVA. Similar results were observed in other similar kind of research.<sup>6,10,11</sup> In growing children, mandible undergoes constant phase of remodelling. Different areas exhibit differential growth pattern. Eruption and shedding of teeth affect the bony remodelling at anterior border of ramus and crest of alveolar bone which has indirect effect in the position of mandibular foramen in children.<sup>12</sup>

Based on the findings of the study, MF was located below the occlusal plane in children up to seven years of age and the position changed above the occlusal plane in age above seven years. In contrary to these findings, the research done by Shukla and Tiku showed that the position of MF was slightly above the occlusal

plane in children of 5-7 years of age.<sup>6</sup> Movahhed et al. did a study in 7-10-year-old children and suggested that IANB should be administered below the occlusal plane for 7-9-year-old boys and 7-8-year-old girls and above the occlusal plane for higher age than that for both genders.<sup>13</sup> Pereira et al. with his study suggested that for the children younger than 7-year-old needle should be inserted below the occlusal plane and should be above the occlusal plane for those over 7-year-old.<sup>14</sup> Kanno et al. conducted a study on 7-10-year-old Brazilian children and recommended that inferior alveolar anaesthesia should be administered at least 6 mm above the occlusal plane for both genders. The research considered mandibular lingula as the reference point.<sup>8</sup>

A study done by Afsar et al. is in contrary to the results of the present study. He advocated that there is no difference in linear distance between the mandibular foramen and occlusal plane in terms of age and sex.<sup>3</sup> Feuerstein et al. with his study in 4-23-year-old sample suggested that MF location should be considered similar in all patients regardless of age.<sup>15</sup> Studies have demonstrated that there are differences in the linear measurements of mandible between right and left sides which was explained as due to the difference in the regional growth at different directions of jaws during Hellman's stages of dental development.<sup>10,12</sup> Similar is the finding of the present study. In opposition to these, there are reports demonstrating no significant difference between right and left sides.<sup>6,12,16,17</sup> Studies

have also shown that there is no difference between male and female in the values concerning the location of mandibular foramen.<sup>6,18</sup> Similar results were observed in the present study as well with no gender difference in the measurements of MF-OP and MF-ABR for both right and left sides.

To the best of authors' knowledge, there has not been any reported literature on Nepali children for locating the position of mandibular foramen for inferior alveolar nerve block. This is the first research of its kind and was done only in a selected population of children. There may be various other parameters that may affect the result like ethnic and racial difference in the growth of jaw, accuracy of radiographic machine, identification of radiographic landmarks. The study should be conducted in large population to give a fair verdict.

## CONCLUSION

Based on the present study, for the inferior alveolar nerve block, the needle should be placed below the occlusal plane in children up to seven years of age and above for higher ages. The depth of needle penetration increases gradually from Hellman's dental developmental stage IIA to IVA. The position of mandibular foramen is not bilaterally symmetrical and there is no gender difference.

**Conflict of interest:** None

**Source(s) of support:** None

## REFERENCES

1. Malamed S. Handbook of Local Anaesthesia. 6th ed. Maryland Heights: Mosby; 2012. pp. 157-253. [[Full Text](#)]
2. Olsen NH. Anaesthesia for the child patient. J Am Dent Assoc. 1956;53:548-55. [[PubMed](#) | [Full Text](#) | [DOI](#)]
3. Afsar A, Haas DA, Rossouw PE, Wood RE. Radiographic localisation of mandibular anaesthesia landmarks. Oral Surg Oral Med Oral Pathol Oral Radiol Endod. 1998 Aug;86(2):234-41. [[PubMed](#) | [Full Text](#) | [DOI](#)]
4. Hetson G, Share J, Frommer J, Kronman JH. Statistical evaluation of the position of the mandibular foramen. Oral Surg Oral Med Oral Pathol. 1988;65:32-4. [[PubMed](#) | [Full Text](#) | [DOI](#)]
5. Tsai HH. Panoramic radiographic findings of the mandibular growth from deciduous dentition to early permanent dentition. J Clin Pediatr Dent. 2002 Spring;26(3):279-84. [[PubMed](#) | [Full Text](#) | [DOI](#)]
6. Shukla RH, Tiku A. Correlation of mandibular foramen to occlusal plane as a clinical guide for inferior alveolar nerve block in children: A digital panoramic radiographic study. Contemp Clin Dent. 2018 Jul-Sep;9(3):372-5. [[PubMed](#) | [Full Text](#) | [DOI](#)]
7. Nakata M, Wei SH. Development of dental arch and occlusion. Occlusal guidance in Pediatric Dentistry. 1st ed. St. Louis, Tokyo: Ishiyaka Euro America, Inc.; 1988. p. 10. [[Full Text](#)]
8. Kanno CM, de Oliveira JA, Cannon M, Carvalho AA. The mandibular lingula's position in children as a reference to inferior alveolar nerve block. J Dent Child (Chic). 2005 May-Aug;72(2):56-60. [[PubMed](#) | [Full Text](#)]
9. Krishnamurthy NH, Unnikrishnan S, Ramachandra JA, Arali V. Evaluation of relative position of mandibular foramen in children as a reference for inferior alveolar nerve block using orthopantomograph. J Clin Diagn Res. 2017 Mar;11(3):ZC71-ZC74. [[PubMed](#) | [Full Text](#) | [DOI](#)]

10. Phukan AH, Mathur S, Sachdev V. Relative changes in position of mandibular foramen in 3–13-year-olds in relation to inferior alveolar nerve block. *Int J Ane Rel.* 2018;2(1):1-8. [[Full Text](#)]
11. Chandran S, Peedikayil FC, Chandru TP, Kottayi S, John S. Relative position of mandibular foramen in 4-9-year-old children: A retrospective study. *SRM J Res Dent Sci.* 2021;12:13-6. [[Full Text](#)]
12. Poonacha KS, Shigli AL, Indushekar KR. Relative position of the mandibular foramen in different age groups of children: A radiographic study. *J Indian Soc Pedod Prev Dent.* 2010;28:173-8. [[PubMed](#) | [Full Text](#) | [DOI](#)]
13. Movahhed T, Makarem A, Imanimoghaddam, Anbiaee N, Sarrafshirazi AR, Shakeri MT. Locating the mandibular foramen relative to the occlusal plane using panoramic radiography. *J Appl Sci.* 2011;11:573-8. [[Full Text](#)]
14. Pereira PN, Fernandes A, Gugisch RC, Zaroni FM, Franco A, Rebellato NLS. Radiographic assessment of the mandibular foramen in children: Focus on anaesthetic procedures. *Arch Oral Res.* 2013 Sept/Dec;9(3):279-83. [[Full Text](#) | [DOI](#)]
15. Feuerstein D, Costa-Mendes L, Esclassan R, Marty M, Vaysse F, Noirrit E. The mandibular plane: A stable reference to localise the mandibular foramen, even during growth. *Oral Radiol.* 2020 Jan;36(1):69-79. [[PubMed](#) | [Full Text](#) | [DOI](#)]
16. Hayward J, Richardson ER, Malhotra SK. The mandibular foramen: Its anteroposterior position. *Oral Surg Oral Med Oral Pathol.* 1977 Dec;44(6):837-43. [[PubMed](#) | [Full Text](#) | [DOI](#)]
17. Larheim TA, Svanaes DB, Johannessen S. Reproducibility of radiographs with the orthopantomograph 5: Tooth-length assessment. *Oral Surg Oral Med Oral Pathol.* 1984 Dec;58(6):736-41. [[PubMed](#) | [Full Text](#) | [DOI](#)]
18. Tsai HH. Panoramic radiographic findings of the mandibular foramen from deciduous to early permanent dentition. *J Clin Pediatr Dent.* 2004 Spring;28(3):215-9. [[PubMed](#) | [Full Text](#) | [DOI](#)]