

## Giant adrenal myelolipoma: A case report

Gurung P<sup>1</sup>, Joshi MR<sup>2</sup>, Hirachand S<sup>3</sup>, Lakhey M<sup>4</sup>

<sup>1</sup>Lecturer, <sup>3</sup>Assistant Professor, <sup>4</sup>Professor, Department of Pathology, Kathmandu Medical College Teaching Hospital, Kathmandu, Nepal

<sup>2</sup>Associate Professor, Department of Surgery, Kathmandu Medical College Teaching Hospital, Kathmandu, Nepal

### Abstract

Adrenal myelolipomas are rare benign tumors. Most are detected incidentally on imaging for non adrenal related symptoms. We report a case of a 78 year old female who presented with non-specific complaint of itching all over the body and a palpable abdominal mass. CT scan abdomen revealed a large right-sided retroperitoneal mass with thin capsule measuring 20.8x15.4x12.7cm. Differential diagnoses considered were retroperitoneal liposarcoma, retroperitoneal teratoma and retroperitoneal myelolipoma. The tumor was resected and sent for histopathological examination. Microscopic examination revealed mature adipocytes, islands of hematopoietic tissue and compressed adrenal tissue at the periphery clinching a diagnosis of adrenal myelolipoma.

**Key words:** adrenal gland, myelolipoma

### INTRODUCTION

Myelolipomas are uncommon benign tumors. Their incidence is 0.08%-0.4% based on autopsy studies<sup>1</sup>. The most common site of occurrence is the adrenal gland; extra adrenal sites of myelolipoma are pelvis, retroperitoneum, and thorax. Most myelolipomas are unilateral, asymptomatic and hormonally inactive. Adrenal myelolipoma accounts for 7% to 15% of all adrenal "incidentalomas"<sup>2</sup>. Small tumors are asymptomatic. Large tumors present with pressure symptoms and abdominal pain. Less commonly it may cause spontaneous retroperitoneal hemorrhage<sup>3</sup>. These lesions can be found in normal adrenal glands, in association with endocrine disorders such as Cushing's disease, Addison's disease, congenital adrenal hyperplasia and hyperaldosteronism or with other tumors such as ganglioneuroma and Hodgkin's lymphoma<sup>4,5</sup>. To the best of our knowledge this is the first case report of adrenal myelolipoma from Nepal.

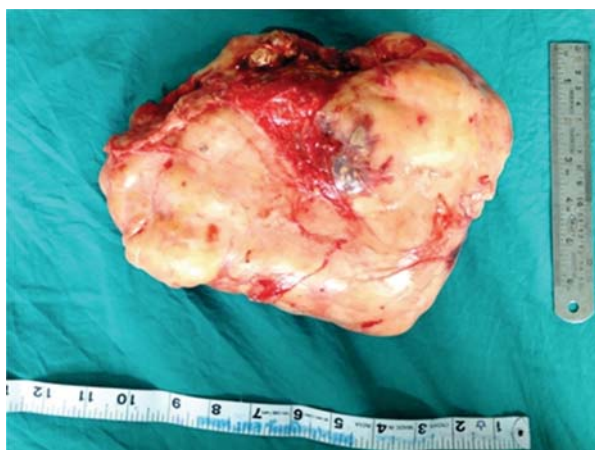### CASE REPORT

A 78 years old female presented with a palpable abdominal mass. CT scan of abdomen showed a huge predominantly fat attenuated, right sided retroperitoneal

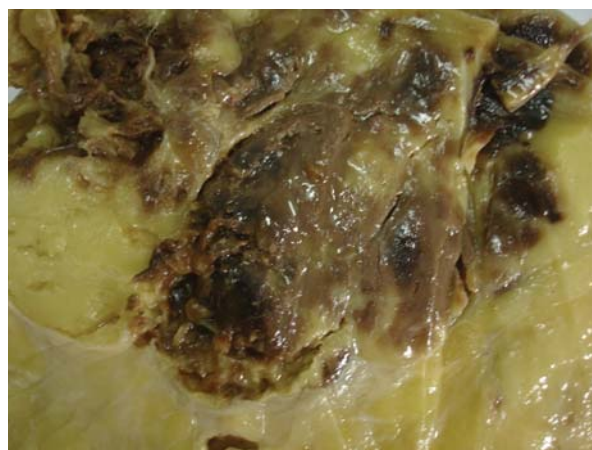mass with thin capsule measuring about 20.8x15.4x12.7 cm. The mass was seen extending from the right sub diaphragmatic region to the right iliac fossa. It had scattered foci of mildly enhancing ill-defined soft tissue components as well as multiple soft tissue density septae. Few linear calcific foci were noted. The right adrenal gland was not separate from the mass and the liver was displaced anteriorly and towards the left side. Suspicion of liposarcoma and teratoma was made based on the CT findings. Operation was performed with midline laparotomy. There was a huge, capsulated, soft, lobulated mass which could be enucleated. Feeding vessels were arising from aorta and inferior vena cava. The mass was resected and sent for histopathological examination. Gross examination revealed an encapsulated fibrofatty tissue mass measuring 23x14x9 cm. Serial sectioning of the mass showed yellowish lobulated, soft to firm areas with foci of haemorrhage (Fig 1 and 2). On microscopic examination, mature adipocytes admixed with islands of hematopoietic tissue were observed. Compressed adrenal tissue was noted at the periphery of the tumour (Fig 3 and 4).

#### Address for correspondence

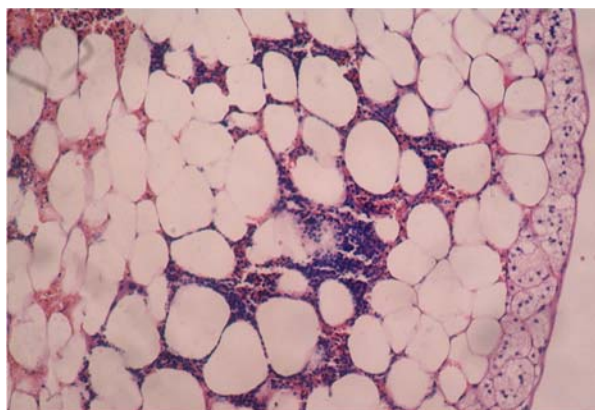
Dr. Pranita Gurung  
Department of Pathology  
Kathmandu Medical College Teaching Hospital  
Sinamangal, Kathmandu, Nepal  
E-mail: pranitagurung2009@gmail.com



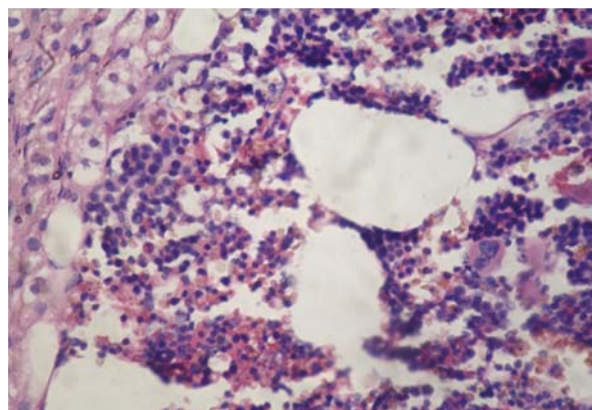
**Figure 1:** Gross appearance of the tumor



**Figure 2:** Cut surface showing haemorrhagic foci within tumor



**Figure 3:** Microscopy showing hematopoietic elements admixed with mature adipocytes and compressed adrenal tissue on the right. ( HE, X20)



**Figure 4:** Higher magnification showing megakaryocytes along with other hematopoietic elements. ( HE, X40)

## DISCUSSION

In 1905, Gierke first described an adrenal myelolipoma and in 1922, the name adrenal myelolipoma was given by Oberling<sup>6</sup>. Since then occasional cases of this rare tumor have been reported from around the world.

Adrenal myelolipomas usually appear as unilateral adrenal masses or as an extra-adrenal retroperitoneal mass. Mean age at diagnosis is approximately 50 years of age and most patients are asymptomatic. These tumors range in size from small microscopic foci to those that fill the abdomen<sup>7</sup>. Grossly, they are typically non-encapsulated, well circumscribed and bright yellow with haemorrhagic foci. Microscopically, they are composed of mature adipose tissue and bone marrow elements. Large tumours may show areas of necrosis, haemorrhage, cyst formation, calcification or ossification<sup>8</sup>. They may be associated with other adrenal conditions like congenital adrenal hyperplasia, cushing's

disease, primary aldosteronism, pheochromocytoma and adenoma<sup>9</sup>.

The pathogenesis of adrenal myelolipoma is uncertain and three theories have been proposed. The first is that myelolipomas are derived from bone marrow emboli that lodge in the adrenal gland. The second theory suggests that myelolipomas are derived from embryonic primitive mesenchymal cells. The third theory suggests that myelolipomas arise from metaplastic transformation of adrenal (or other sites) stromal cells in response to various stimuli such as necrosis, infection and stress<sup>10</sup>. Whether these are true neoplasms or reactive processes is under scrutiny. The study done by Bishop et al. demonstrated non random X chromosome inactivation in the hemopoietic elements and fat in 8 of 11 myelolipomas of female patients supporting a clonal origin of these tumors. Another study done by Chang KC

et al demonstrated a balanced translocation between 3q25 and 21p11 suggesting a possible clonality in myelolipomas<sup>11</sup>.

On ultrasound, myelolipoma is highly suspected if a highly echogenic mass is seen in a hormonally inactive adrenal mass<sup>12</sup>. Myelolipomas on CT scan typically show presence of fat with very low CT attenuation values (-30 to -100 Hounsfield Units) within an adrenal mass<sup>3</sup>. MRI findings of these lesions in T1 weighted images is hypo-intense with scattered hyper-intense foci, while in T2 weighted images; it is hyper-intense with focal

iso-intense areas. After the contrast, the foci will be enhanced.

Treatment: Myelolipomas less than 10cm in diameter should be observed closely. Large asymptomatic tumors greater than 10 cm should be excised due to risk of retroperitoneal haemorrhage<sup>3</sup>.

## CONCLUSION

Adrenal myelolipomas are rare tumors. An awareness of their existence can improve the recognition and diagnosis of these lesions and subsequent management.

## REFERENCES

- Po CL, Yang FS. Bilateral Giant Adrenal Myelolipomas a case report and literature review. *Chin J Radiol.* 2008;33:2124.
- Kloos RT, Gross MD, Francis IR, Korobkin M, Shapiro B. Incidentally discovered adrenal masses. *Endocrine Rev.* 1995;16(4):460-84.
- Akhtar F, Ishtiaq S, Ali Z, Hassan U. Adrenal Myelolipoma. *Ann Pak Inst Med Sci.* 2009;5(4):266-8.
- Merchant SH, Herman CM, Amin MB, Ro JY, Troncoso P. Myelolipoma associated with adrenal ganglioneuroma. *Arch Pathol Lab Med.* 2002;126:736-7.
- Timonera ER, Paiva ME, Lopes JM, Eloy C, Van der KT, Asa SL. Adrenal adenomatoid tumor and myelolipoma. *Arch Pathol Lab Med.* 2008;132(2):265-7.
- Ong K, Tan KB, Putti TC. Myelolipoma within a non-functional adrenal cortical adenoma. *Singapore Med J.* 2007;48(7):e200-e202.
- Delellis RA, Mangray S. The Adrenal glands. *Sternberg's Diagnostic Surgical Pathology*, 5th ed. Philadelphia: Lippincott Williams & Wilkins; 2010. p. 576-81.
- Bennett BD, McKenna TJ, Hough AJ, Dean R, Page DL. Adrenal myelolipoma associated with Cushing's disease. *Am J Clin Pathol.* 1980;73:443-447.
- Oliva A, Duarte B, Hammadeh R, et al. Myelolipoma and Endocrine Dysfunction. *Surgery.* 1988;103:711-5.
- Bishop E, Eble JN, Cheng L, Wang M, Chase DR, Orazi A, et al. Adrenal Myelolipomas show nonrandom X-chromosome inactivation in hematopoietic elements and fat: support for a clonal origin of myelolipomas. *Am J Surg Pathol.* 2006;30(7):838-43.
- Chang KC, Chen PI, Huang ZH, Lin YM, Kuo PL. Adrenal myelolipoma with translocation (3:21) (q25;p11). *Cancer Genet Cytogenet.* 2002;134:77-80.
- Soliman HE, Zein TA, Milad MF, Hussein ES, Al-Tartir TM, Al-Khudairy NN, et al. Myelolipoma of the adrenal gland diagnosis and management. *Saudi Med J.* 2001;22(5):457-9.