

Diagnostic efficacy of ultrasonography in acute appendicitis

Lohani B, Gurung G, Paudel S, Kayastha P

Department of Radiology and Imaging, Institute of Medicine, Tribhuvan University Teaching Hospital, Kathmandu, Nepal.

Correspondence address: Dr. Benu Lohani, Department of Radiology and Imaging, Institute of Medicine, Tribhuvan University Teaching Hospital, Kathmandu, Nepal.

E-mail: benulohani@yahoo.com

Abstract

Introduction: Acute appendicitis is the most common acute condition of the abdomen requiring surgery in both adults 1,2 and children. 3–5 The overall frequency of appendicitis for symptomatic patients younger than 20 years is 41%; the frequency for those older than 20 years is 59%.

Methods: This was a prospective cross sectional study involving 104 patients aged between 8 and 68 years with clinical suspicion of acute appendicitis. Patients with suspected acute appendicitis were evaluated with high frequency linear transducer using graded compression technique. Per operative findings were noted and histopathological examination were carried out in all the cases for confirmation of acute appendicitis. Sensitivity, specificity, negative predictive value, positive predictive value and accuracy of ultrasonography were calculated by using statistical method.

Results: Among 104 patients (61 males and 43 females) with clinical diagnosis of acute appendicitis, ultrasonography was positive for acute appendicitis in 79 patients (75.96%). On histopathological examination, 94 appendices (90.38%) were acutely inflamed. The sensitivity of ultrasonography for the diagnosis of acute appendicitis was 78.72% with specificity of 60%. Positive predictive value, negative predictive value and accuracy of ultrasonography were 94.87%, 23.07% and 76.92% respectively.

Conclusion: Ultrasonography is a useful method of diagnosing clinically suspected acute appendicitis especially in doubtful cases.

Key Words: Acute appendicitis, diagnosis of appendicitis, ultrasonography

Introduction

Acute appendicitis is the most common acute condition of the abdomen requiring surgery in both adults 1,2 and children. 3–5 The overall frequency of appendicitis for symptomatic patients younger than 20 years is 41%; the frequency for those older than 20 years is 59%. 6,7

It has overall mortality rate of <1%, higher in elderly patients (5-15%)⁸⁻¹¹. Late diagnosis can lead to perforation & other complications like abdominal abscess, wound infection, infertility & death. Rupture which is more common in elderly & very young, is associated with 17-40% morbidity.^{12,13} With prompt diagnosis, morbidity

& mortality can be decreased significantly. In men there are limited alternative diagnosis for acute appendicitis and thus low negative appendectomy rate of 10-15%. 6, 7 In women, especially in reproductive age group, many acute gynecological illnesses mimic appendicitis. Due to non specificity of clinical findings & lack of readily available diagnostic techniques they have high negative appendectomy rates up to 34-46%.^{14,15}

Ultrasonography is a widely available, comparatively inexpensive technique which has potential for highly accurate imaging in the diagnosis of acute appendicitis. It is also useful for identifying alternative diagnosis. Graded compression USG with slow & gently maintained pressure

is valuable in successful evaluation even in uncomfortable & reluctant patients. Other advantages of ultrasound include the lack of ionizing radiation or need for patient preparation, and the ability to provide dynamic information through graded compression.¹⁶ This study was carried out to evaluate the efficacy of ultrasonography in the diagnosis of acute appendicitis.

Methods

This was a prospective cross sectional study involving 104 patients with clinical diagnosis of acute appendicitis attending the emergency department of TU Teaching Hospital and Kathmandu Model Hospital between January 2004 and December 2006. The study was approved by the medical ethical committee of the institution and all patients gave informed consent for the study. Clinical diagnosis of acute appendicitis was made based on appropriate clinical history, physical examination and supportive laboratory finding of leukocytosis.

All the patients were subjected for ultrasonography of abdomen. Graded compression technique with 7.5 MHz linear array transducer was utilized for the ultrasonography. Following parameters were assessed in ultrasonography:

- Maximum outer to outer diameter of appendix
- Compressibility
- Appearance of target sign
- Appendicolith
- Periappendiceal collection
- Probe tenderness
- Localized dilatation of bowel loops
- Associated other diagnosis.

Ultrasonographic diagnosis of acute appendicitis was made when appendix measured >6.0 mm in maximum outer to outer diameter [Fig. 1] with non compressibility and probe tenderness were present. All patients were operated and following peroperative findings were noted: Diameter of appendix, position of appendix in relation to caecum, fluid collection, presence of appendicolith, mucocele of appendix, appendicular perforation, peri-appendiceal collection and dilated bowel loops were assessed. Then all the resected specimens were subjected to histopathological examination. Histopathological diagnosis was made based on gross findings and microscopic findings of inflammatory cells in the wall of appendix.

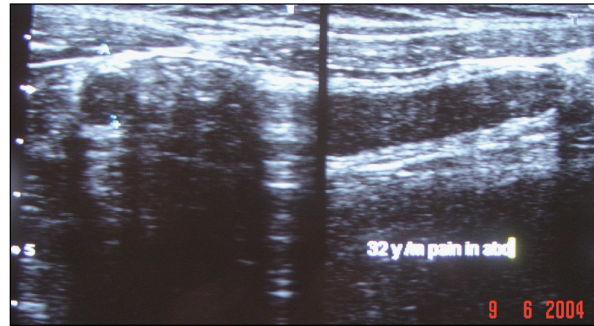


Fig. 1: Transverse and longitudinal ultrasound images showing enlarged appendix (Distance between calipers = diameter of appendix = 9 mm).

Statistical Analysis

SPSS 11.5 package was used for the statistical analysis. Sensitivity, specificity, positive predictive value, negative predictive value and accuracy of ultrasonography were obtained by using histopathological finding as a confirmative test.

Results

Total of 104 patients with clinical diagnosis of acute appendicitis were examined ultrasonographically and all appendices were subjected for the histopathological examination after operation. Among 104 patients, 61 (58.7%) were males and 43 (41.3%) were females. Patient's age ranged from 8 years to 68 years (mean 27.36 year). Ultrasound diagnosis of acute appendicitis was made in 79 patients (75.96%). Mean diameter of enlarged appendix was 9.5 mm (range 6 to 16 mm). Ultrasound findings are given in table 1. Peroperatively 98 (94.2%) cases were diagnosed as appendicitis. Per operative findings are summarized in table 2.

Table 1: Ultrasonographic findings (n=104)

Category	Frequency (%)
Diameter (>6 mm)	79 (76%)
Target sign	49 (47.1%)
Fluid collection	17 (16.7%)
Compression test positive	51 (49%)
Probe tenderness	52 (50%)
Appendicolith	6 (5.8%)
Positive ultrasound diagnosis of acute appendicitis	79 (76%)

Table 2: Peroperative findings (n=104)

Category	Frequency (%)
Inflamed	98 (94.2%)
Fluid collection	54 (52%)
Appendicolith	19 (18.26%)
Perforation	11 (10.57%)
Mucocele	5 (4.8%)
Lump formation	3 (2.88%)
Dilated bowel loops	1 (0.96%)

Histopathologically, 94 appendices were diagnosed as acute appendicitis. Among these, 56 males and 48 females were diagnosed as acute appendicitis. The ultrasound sensitivity of acute appendicitis was 78.72%. Ultrasound specificity was 60%. Positive predictive value, negative predictive value and accuracy of the test were 94.87%, 23.07% and 76.92% respectively.

Discussion

In this study we correlated ultrasonographic findings with histopathology in clinically diagnosed cases of acute appendicitis. We found high sensitivity of USG of 79% for the diagnosis of acute appendicitis. This value is similar to that found by Adrienne VR et al (78%)¹⁷ and Andrea SD et al (83%)¹⁸. Due to four false positive cases we found low specificity of 60% as compared to 83% & 93% in Adrienne VR et al¹⁷ and Andrea SD et al¹⁸ study respectively. Accuracy and positive predictive values were good (~77% & 95% respectively) and similar to other studies.¹⁹ we found higher incidence of acute appendicitis in males as compared to females.

There is increasing trend in using radiological investigations for diagnosis of acute appendicitis. Use of USG had significantly increased from 10% in 1997 to 60% in 2005. However, in the recent years, use of ultrasound is decreasing as the use of CT has markedly increased (0% in 1997 to 35% in 2007). With association of cancer in later life & early radiation exposure well documented, CT is to be avoided if possible²⁰. Moreover, in countries like ours, CT is more expensive and ultrasound would be the good investigation for acute appendicitis.

Conclusion

Acute appendicitis is the most common indication for emergency operation. Accurate & prompt diagnosis is essential for reducing morbidity. Atypical presentation leads to diagnostic dilemma & delayed treatment and in these cases imaging plays a crucial role. Use of USG significantly reduces the negative laparotomy especially

in females. Graded compression USG is a sensitive and accurate method for the diagnosis of acute appendicitis. It is preferred over other imaging technique as it is non invasive & does not use ionizing radiation.

References

1. Storer EH. Appendix. In: Schwartz SI, ed. Principles of surgery. 3rd ed. New York, NY: McGraw-Hill International, 1979; 1257–1267.
2. Federle MP. Focused appendix CT technique: a commentary. *Radiology* 1997;202: 20 –21.
3. Henderson J, Goldacre MJ, Fairweather JM. Conditions accounting for substantial time spent in hospital in children age 1–14 years of age. *Arch Dis Child* 1992;67:83–86.
4. Siegel MJ. Acute appendicitis in childhood: the role of US. *Radiology* 1992;185:341–342.
5. Lund DP, Kolkman J. Appendicitis. In: Walker WA, Durie PR, Hamilton JR, eds. Pediatric gastrointestinal disease. 2nd ed. Vol 1. St Louis, Mo: Mosby–Year Book, 1996; 907–914.
6. Berry J Jr, Malt RA. Appendicitis near its centenary. *Ann Surg* 1984;200:567–575.
7. Lewis FR, Holcroft JW, Boey J, et al. Appendicitis: critical review of 1000 patients. *Arch Surg* 1975;110 :677–684.
8. Anonymous. A sound approach to the diagnosis of acute appendicitis (editorial). *Lancet*. 1987;I:198-200.
9. Fenyo G. Acute abdominal disease in the elderly. *Am J Surgery*, 1982; 143:751-754.
10. Balsano N, Cayten CG. Surgical emergencies of the abdomen. *Emerg Med Clin North Am*. 1990; 8:399-410.
11. Fitz RH. Perforating inflammation of the vermiform appendix with special reference to its early diagnosis and treatment. *Am J Med Sci* 1886; 92:321-346.
12. Seymour I Schwartz, Harold Ellis. Maingot's abdominal operations. Vol. 1. 1255-1281.
13. Lewis FR, Holcroft JW, Boey J, Dunphy JE. Appendicitis: A critical review of diagnosis and treatment in 1000 cases. *Arch Surg* 1975; 110: 677-684.
14. Fitz RH. Perforating inflammation of the vermiform appendix with special reference to its early diagnosis and treatment. *Trans Assoc Am Physicians* 1986;

- 1:107-144.
15. Buchman TG, Zuidema GD. Reasons for delay of the diagnosis of acute appendicitis. *Surg Gynecol Obstet* 1984; 158: 260-266.
 16. Puylaert JB, van der Zant FM, Rijke AM. Sonography and the acute abdomen: practical considerations. *AJR Am J Roentgenol* 1997;168:179 –186.
 17. Adrienne VR, Shandra B, Aeilko HZ, Dirk TU, Jaap S, Marja AB. Acute Appendicitis: Meta-Analysis of Diagnostic Performance of CT and Graded Compression US Related to Prevalence of Disease. *Radiology* 2008; 249 (1): 97-106.
 18. Andrea SD, Rahim M, Christian JK, Monica E, Joseph B, Suzanne S et al. US or CT for Diagnosis of Appendicitis in Children and Adults? A Meta-Analysis. *Radiology* 2006; 241 (1): 83-94.
 19. Health Central; General Encyclopedia – Acute appendicitis.
 20. Wong KK, Cheung TW, Tam PK. Diagnosing acute appendicitis: are we overusing radiologic investigations?. *J Pediatr Surg.* 2008; 43 (12): 2239-41.