

Clinical and Etiological Profile of Patients with Optic Disc Edema in Tertiary Care Centre of Nepal

Ritesh K Shah

BP Koirala Lions Center for Ophthalmic Studies, Institute of Medicine

Corresponding author :

Dr. Ritesh K Shah, MD

BP Koirala Lions Center for Ophthalmic Studies, Institute of Medicine

ABSTRACT

Introduction

sible in most cases using tests like visual acuity, color vision, visual field and suitable radiological imaging. Study in Nepalese population with regard to optic disc edema is scarce. Hence this study aims to act as a guideline for evaluation of such cases and help in further studies in this regard.

Methods

A descriptive, cross-sectional study was conducted in all cases of optic disc edema presenting to neuro-ophthalmology clinic of B.P. Koirala Lions Centre for Ophthalmic Studies from January 2011 to June 2012. A detailed history was obtained and proper ocular and nervous examination was done by ophthalmologist and neuro-physician. Assessment of visual acuity, color vision, contrast sensitivity and visual field along with radiological tests were done in all possible cases.

Results

Out of all the cases evaluated, 38 cases where causes of optic disc edema could be established were included in the study. The commonly affected age group was 31 to 40 years (26.3%) and most of them were males. The commonest cause observed was optic neuritis (36.8%). Others were papilledema, idiopathic intracranial hypertension, toxic optic neuropathy, non-arteritic anterior ischemic optic neuropathy (NA-AION), compressive and traumatic optic neuropathy.

Conclusion

Optic neuritis and papilledema should be considered as common differential diagnosis in patients with optic disc edema. NA-AION is a relatively uncommon disease among Nepalese population.

Keywords : NA-AION, optic disc edema, optic neuritis, papilledema

INTRODUCTION

Optic disc edema which refers to edematous swelling of the optic disc results from a variety of causes. Demyelinating optic neuritis (ON), non-arteritic anterior ischemic optic neuropathy (NA-AION), compressive optic neuropathy, retinal-vein occlusion, and diabetic papillopathy are common causes of unilateral disc edema. Similarly bilateral optic disc swelling is often associated with papilledema,

infiltrative optic neuropathy, toxic optic neuropathy, and malignant hypertension.¹

Common causes of optic disc edema like optic neuritis and anterior ischemic optic neuropathy can cause significant visual morbidity. On the other hand, intracranial tumors and infections can be life threatening. Hence, early identification of the cause of disc edema with timely management can be both sight and life saving.

Clinically disc edema of intracranial origin can be distinguished from other forms of acquired disc swelling with a concept that visual acuity, visual field, and pupillary reactions are typically normal in papilledema, whereas they are almost always defective in papillitis or ischemic optic neuropathy.²

Several studies done for clinical and etiological evaluation of cases of disc edema have investigated different aspects of vision like visual acuity, color vision, visual field and contrast sensitivity as supportive measures to establish the cause of disc edema. In view of above fact, this study is undertaken using similar diagnostic tools along with radiological imaging in order to prepare a clinical and etiological profile of optic disc edema cases.

Study in Nepalese population with regard to optic disc edema is very scarce. Hence this study can act as a guideline for evaluation of such cases as well as a foundation for further studies in this regard.

METHODS

A cross sectional study was carried out between January 1st, 2011 to June 30th, 2012. All the cases of disc edema presenting to neuro-ophthalmology clinic of B.P. Koirala Lions Centre for Ophthalmic Studies, Institute of Medicine were included. Patients who had already received any medical or surgical treatment and those secondary to systemic condition affecting retina or the optic nerve (like diabetes, or hypertension and inflammatory ocular pathology like posterior uveitis) were excluded.

After taking verbal informed consent from the patients or their guardians (in cases of minors), a detail history was obtained regarding profile of the patients, presenting symptoms, past illness, associated risk factors, any form of treatment received and personal habits like smoking cigarettes and drinking alcohol.

Visual Acuity was assessed by internally

Table 1. Etiologic distribution of optic disc edema

Causes	Number of patients	
	Number	Percentage
Optic neuritis (ON)	14	37
Papilledema	9	24
Idiopathic intracranial hypertension (IIH)	6	16
Toxic optic neuropathy (TON)	4	10
NAAION	2	5
Compressive optic neuropathy (CON)	2	5
Traumatic optic neuropathy (Tr.ON)	1	3
Total	38	100

Table 2: Age distribution

Age in years	Number of cases	
	Number	Percentage
0-10	2	5
11-20	7	18
21-30	4	11
31-40	10	26
41-50	8	21
51-60	6	16
61-70	1	3
Total	38	100%

illuminated Snellen vision box with multiple optotype and E chart (for illiterates) at a distance of 6 meters. Anterior segment examination was performed with the help of slit lamp biomicroscopy. A careful evaluation of pupillary reaction, its size and swinging flash light test was performed in a dark room with a bright source of light. Anterior segment examination was performed and dilated fundus examination done with 90D and 20D indirect ophthalmoscopy. Complete neurological examination was done by consultant neurologists in neuro-ophthalmology clinic.

- a) Colour vision was tested with Ishihara chart.
- b) Visual field test was done using Goldmann Perimeter.
- c) Radiological imaging (CT scan or MRI or MRV) was done.

Table 3: Laterality

	Disc edema cases
Unilateral	15 (40%)
Bilateral	23 (60%)

All the above mentioned data were recorded in a proforma especially made for this purpose and data analyzed using SPSS version 19.

RESULTS

A total of 38 patients (61 eyes) where radiological imaging could be done to establish the etiology of disc edema were included in the study.

The commonest cause of disc edema in our study was optic neuritis 14 (36.8%) as depicted in table 1. Out of which one was due to Devics' disease. Multiple sclerosis could not be confirmed in any case of optic neuritis. Papilledema was seen in 9 (23.7%) cases of disc edema. Idiopathic intracranial hypertension was confirmed in 6 cases (15.8%) after demonstrating raised CSF opening pressure during lumbar puncture and a normal brain scan. Other causes included NA-AION, toxic optic neuropathy, compressive optic neuropathy and traumatic optic neuropathy. Out of 4 cases (10.5%) of toxic optic neuropathy, three were due to consumption of methanol and the fourth case was Ethambutol induced which was seen in

Table 4: Visual acuity

Age in years	Number of eyes	
	Number	Percentage
6\6-6\18	34	55
6\24-6\60	5	8
5\60-3\60	6	10
2\60-PL	12	20
NPL	4	7
Total	61	100

a female under anti-tubercular therapy for 45 days for TB meningitis. Compressive optic neuropathy was seen in two patients (5.3%); one was secondary to advanced thyroid eye disease and the other due to optic nerve glioma.

Age of the patients in our study ranged from 8 to 65 years. (Table2). Mean age of all the cases of disc edema was 35.5 years. The

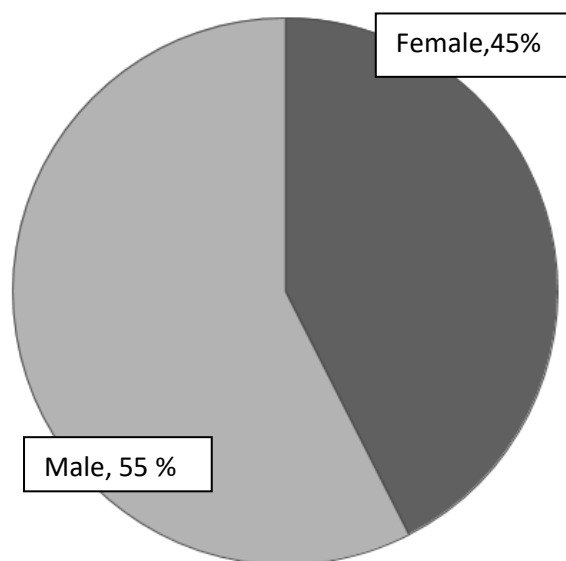


Figure 1. Sex distribution of optic disc edema cases

Table 5: color vision

Color vision	Number of eyes	
	Number	Percentage
Normal	32	52
Total color vision defect	5	8
Red green defect	1	2
Deutan defect	1	2
Tritan defect	1	2
Not done	21	34
Total	61	100

mean age for patients with optic neuritis was 38.6 years.

Figure 1 shows M:F ratio of 1.24:1. Seventeen (44.7%) patients with disc edema were female. Female was the predominant sex in optic neuritis (65.8%), and idiopathic intracranial hypertension (83.3%).

Most of the cases of disc edema were bilateral (60.5%). (table3) Ten cases (71.4%) of optic neuritis were unilateral. One case of papilledema was unilateral who had pre-existing optic atrophy of left eye and papilledema of the other eye secondary to lesion in left parafalcine region.

Best corrected visual acuity on presentation was normal in 55.7 % of patients. (Table 4). Ten eyes (71.4%) with optic neuritis had vision equal or less than 3/60. All cases of idiopathic intracranial hypertension (IIH) had visual

Table 6: Visual field

Visual field	Number of cases	
	Number	Percentage
Normal	10	16
Enlarged blind spot	18	30
Enlarged blind spot with reduced central sensitivity	5	8
Central and/or paracentral scotoma	2	3
Superior quadrantopia	2	3
Altitudinal defect	2	3
Centrocecal scotoma	1	2
Not done	21	35
Total	61	100

acuity better than 6/18. All cases of toxic optic neuropathy had visual acuity of counting finger close to face or worse. Three eyes of two patients with NAAION had vision of 6/60 or worse.

Color vision could not be assessed in 21 eyes (34.4%) because of very poor vision at the time of presentation. Eight eyes (13%) had impaired color vision. (Table 5)

Visual field could be assessed in 65.6% of eyes with disc edema and of them enlarged blind spot was the commonest type of visual field defect (29.5%). (Table 6)

Radiological imaging:

In cases of optic neuritis, radiological imaging (MRI brain and orbit) were normal in 9 cases (64.3%) suggesting papillitis as the diagnosis, 3 (21.4%) of them had thickened optic nerve sheath and 2 cases (14.3%) showed areas of demyelination which was not specific for multiple sclerosis. A myriad of radiological findings were seen in cases of papilledema. Pineal region tumor likely meningioma, mass in left parafalcine location, third ventricle colloidal cyst, granulomatous lesion in parietal region likely tuberculoma, transverse and sigmoid sinus sinus thrombosis, multiple cystic lesion in brain suggestive of neurocysticercosis were seen in MRI of brain in cases with papilledema. Pyogenic meningitis was confirmed in three cases through CSF analysis.

MRI in all cases of IIH showed normal study of brain and CSF opening pressure were raised above 18 cm of water.

CT of traumatic optic neuropathy showed fracture of floor and lateral wall of left orbit and anterior wall of maxillary sinus.

MRI orbit and brain in younger patient with compressive optic neuropathy showed spindle shaped mass in optic nerve suggestive of optic nerve glioma and CT orbit in other case showed thickened extraocular muscle more towards the orbital apex.

DISCUSSION

A wide variety of etiologies of optic disc edema was seen in this study. The commonest cause of disc edema was optic neuritis (36.8%) followed by papilledema (23.7%). In contrast Jong Jin Jung³ reported NAAION (34.7%) as the commonest cause of optic disc edema in a study done among 49 patients with optic disc edema in Seoul, Korea. Optic neuritis (30.6%) was second commonest cause of disc edema in his study. A very similar pattern was also observed in studies done in France by Marques⁴ (52% NAAION) and by Ozdamar⁵ (49.3% NAAION) from Turkey. AION has also been reported as the commonest cause of optic disc edema among Caucasians⁶. This suggests NA AION may be a rare disease among Nepalese population unlike in other parts of the world.

Mean age of 35.5 years seen in our study was low when compared to another study done by Tournaire-Marques⁴. This could be explained by the difference in the etiological pattern in both the studies. NA AION, which is commonly seen in elderly age group, was the commonest cause of optic disc edema in Marques's study whereas in this study it was observed only in 2.5% of total cases of disc edema.

A male preponderance, representing 55.7% of total study group was seen in the current study. In contrast to this finding, female outnumbered males in studies done by Jasmine Ozdamar (51.9%) and Marques (62.5%).

Color vision and visual field testing could not be done in significant number of cases (21%) due to poor vision at presentation. However, it was seen that color vision remained unaffected in many eyes of papilledema (82.4%) and IIH (100%) whereas in 61.1% of total optic neuritis eyes where color vision could be done, 54.5% of eyes had abnormal color vision.

Visual field could be done in 61.1% of eyes with optic neuritis and the commonest field defect observed was reduced central sensitivity with enlarged blind spot (45.5%). In contrast, Jain IS⁷ observed concentric contraction (25%) to be the commonest defect in eyes with optic neuritis. Shatriah⁸ reported paracentral scotoma in 29.3% of eyes with optic neuritis, which was the most common visual field defect.

A significant number of patients with IIH had no field defect (50%) in this study which was consistent with Vishwanathan Ananth's study⁹ done in 25 patients with IIH in Saudi Arabia.

He reported no visual field defect in 76% of the cases. Another series¹⁰ reported 62.5% of eyes of IIH had isolated enlarged blind spot as the common field defect. Isolated enlarged blind spot was the second commonest (33.3%) field defect in this study.

Small sample size was one of several limitations of this study. Many cases of optic disc edema who could not get radiological tests done were excluded from the study. Cases of optic disc edema seen in department other than neuro-ophthalmology department were excluded. Hence, cases like diabetic papilloapthy or uveitis were overlooked.

CONLUCSION

Optic neuritis and papilledema are important and common differentiating conditions in cases with optic disc edema. Na-AION is a relatively uncommon disease in Nepalese population. Diagnosis of optic disc edema can be established in most cases with a proper clinical history, ocular and neurological

examination which when further supported by color vision, contrast sensitivity, visual field tests and radiological imaging.

CONFLICTS OF INTEREST

None declared.

REFERENCES

1. Van Stavern GP. Optic disc edema. *Semin Neurol* 2007; 27:233-43.
2. Glaser JS. *Duane's ophthalmology*. Philadelphia: Lippincott Williams & Wilkins; 2006
3. Jung JJ. Analysis of the Causes of Optic-Disc Swelling. *Korean J Ophthalmol* 2011; 25(1):33-36.
4. Marques T. Unilateral optic disc edema: Retrospective study of fifty-two patients. *J Fr Ophtalmol* 2012 Sep; 26 (4): 396-403.
5. Ozdamar J. Clinical and etiological evaluation of unilateral disc edema. *Journal of Neurological Sciences (Turkish)* 2009; 26 (4): 396-403.
6. Miller NR, Newman NJ, Biousse V, Kerrison JB, editors. *Walsh & Hoyt's clinical neuro-ophthalmology: the essentials*. 2nd ed. Philadelphia: Lippincott Williams & Wilkins; 2008.
7. Jain IS, Munjal VP, Dhir SP, Gangwar DN. Profile of optic neuritis in Chandigarh and surrounding areas. *Indian Journal of Ophthalmology* 1980; 28 (4):195 – 200.
8. Shatriah. Clinical Profile and etiology of Optic Neuritis in Hospital Universiti Sains Malaysia 5 Years Review. *Med J Malaysia* 2012 April; 67(2): 159-164.
9. Ananth V, Sirwal IA Banoo T. Idiopathic intracranial hypertension (prospective study of 25 patients). *Jk sciences* 2001; 3 (1): 21-24.
10. Ambika S. Clinical profile, evaluation, management and visual outcome of idiopathic intracranial hypertension in a neuro-ophthalmology clinic of a tertiary referral ophthalmic center in India. *Ann Indian Acad Neurol* 2010 Jan-Mar; 13(1): 37-41.