

Early Laparotomy: A Necessity for Postoperative Intraperitoneal Hemorrhage

Suniti Rawal, Pooja Paudyal

Department of Obstetrics and Gynecology, Maharajgunj Medical Campus, Tribhuvan University Teaching Hospital, Institute of Medicine, Kathmandu, Nepal

Corresponding author :

Dr. Suniti Rawal, MD

Associate Professor, Department of Obstetrics and Gynecology, Maharajgunj Medical Campus, Tribhuvan University Teaching Hospital, Institute of Medicine, Kathmandu, Nepal

Email: sunudinurawal@yahoo.com

ABSTRACT

Introduction

Haemorrhage is considered the dreaded complications following any surgery. "Relaparotomy" is a better described terminology for a repeat case postoperative haemorrhage in gynecological surgeries. With increased awareness and early detection and subsequent rise in gynaecological operations have led additional incidence of relaparotomies and further in morbidity and mortality.

Methods

The study was conducted from April 2006 - March 2017 including cases of re/laparotomy for intraperitoneal bleeding at TUTH, Nepal.

Results

There were 27 cases of intraperitoneal hemorrhage majorly from 20 abdominal surgeries comprising 12(44.4%) abdominal hysterectomies, 6 (22.2%) laparotomy, 1(3.7%) each of diagnostic laparoscopy and abdomino perineal approach and 7(26%) vaginal hysterectomies. Features of hypovolaemic shock in 14(51.8%), marked abdominal distention in 9(33.3%) and blood loss of 400 to 3000 ml was observed.

Five (18.5%) cases of active bleeding from pedicles were secured. Oozing from various sites (10, 37%) cured with haemostatic sutures. Generalised oozing post diagnostic laparoscopy, subtotal hysterectomy was done (1, 3.7%). In 2 (7.4%) cases bleeding from fallopian tube and mesosapinx were sutured. Six (22.2%) hematomas were evacuated and bleeders secured. Dissection of left uterosacral ligament and tearing of infundibulopelvic ligaments (1, 3.7%) were reinforced and sutured. Sputter in the vault (1, 3.7%) were ligated and isolated rise in PT (1, 3.7%) with FFP transfusion.

Two succumbed to death, one following diagnostic laparoscopy from adult respiratory distress syndrome and next from VH with PFR anesthetic complications.

Conclusion

Proper closure of surgical incision with the right technique, appropriate ligature, careful tying of the blood vessel, monitoring pulse rate and blood pressure in postoperative cases can minimize the morbidity and mortality.

Keywords: Hemoperitoneum, intraperitoneal bleeding, relaparotomy

INTRODUCTION

Hemorrhage is one of the dreaded complications following any surgery. Hemoperitoneum requiring early second intervention have been reported following procedures as simple as culdoscentesis to one even following vaginal hysterectomies.^{1,2} Having the abdomen opened once already "relaparotomy" is a better described terminology incorporated in postoperative

haemorrhage following hysterectomies, myoma enucleation, even laparotomies for ectopic pregnancies.^{3,4} A reoperation rate between 0.6- 4.7% has been reported in various studies.^{5,6} Recently, laparoscopic approach has been found as an attractive alternative to the exploratory laparotomy. In 0.85% postoperative bleeding following laparoscopic or vaginal hysterectomy, intraabdominal hemorrhage was stopped by immediate laparoscopy.

Table 1. Routes and indications of surgery

S.N.	Route of Surgery	Indications	Number (N=27)
1	Abdominal Hysterectomy	Myoma	6
		Ovarian tumor	3
		DUB	1
		H mole	1
		Endometriosis	1
2	Laparotomy	Dermoid cyst	3
		Ectopic	2
		Endometriosis	1
3	Vaginal Hysterectomy	UV Prolapse	7 (26%)
4	Abdomino perineal approach	UV Prolapse with ovarian tumor	1 (3.7%)
5	Diagnostic Laparoscopy	Infertility	1 (3.7%)

Some literatures have quoted relaparotomy to be "laparotomy performed within 60 days following initial surgery".⁷ Urgent abdominal re-explorations following complicated abdominal surgeries are generally known as "final choice operations" with high mortality and morbidity rates.⁸ Early relaparotomy refers to laparotomy performed within 21 days of original surgery.⁹

Due to more awareness and early detection more and more number of gynaecological cases are getting operated, leading to increase in the incidence of relaparotomies and further in morbidity and mortality.

Here the concentration was on laparotomy as second intervention for hemorrhagic complication arising from gynecological surgeries; aiming to find out the constraints to convene a remedy.

METHODS

It was a retrospective analysis of laparotomies performed for intraperitoneal hemorrhage

Table 2. Clinical presentations

S.N.	Clinical Presentation	Number (N=27)
1	Features of hypovolaemic Shock	14
2	Marked abdominal distention	9
3	Oliguria with or without haematuria	6
4	Suprabupic mass (hematoma 12X12 cm)	1

after vaginal or abdominal procedure in the Department of Obstetrics and Gynaecology, Tribhuvan University Teaching Hospital, for the past 11 years (April 2006-March 2017). A total of 27 cases who underwent relaparotomy for haemoperitoneum following primary surgery (abdominal or vaginal route) were studied. The medical records of these patients were reviewed. Relaparotomy for sepsis, bleeding in the anterior abdominal wall, rectus sheath haematoma, paralytic ileus and burst abdomen due to infections were excluded. Approval was obtained from The Institutional Review Board. The following parameters were studied: route and indication of surgery,

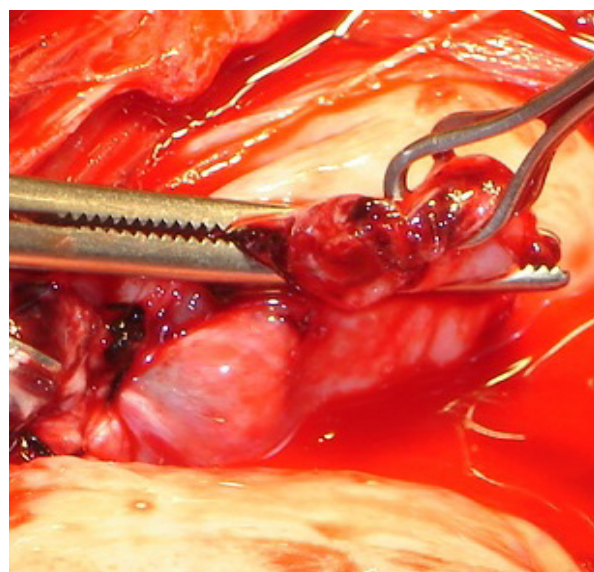


Figure 1. Slipped infundibulopelvic ligament

Table 3. Causes and Remedies for bleeding

S. N.	Causes of bleeding	Remedies	N=27
1	Active Bleeding from vascular pedicles	Bleeder secured	5
2	Oozing from various sites-bladder base(4), broad ligament(2), omentum(1) vaginal cuff(1), Lt cardinal ligament(1), bed of endometriosis(1)	Hemostatic sutures	10
3	Generalized oozing	Subtotal hysterectomy	1
4	Bleeding from fallopian tube, mesosalpinx	Resutured	2
5	Hematomas: Cornual stump(1), Vault(2), Broad ligament(1), Bladder base(1), Retroperitoneal(1)	Hematoma evacuated, bleeders secured	6
6	Dissection of left uterosacral ligament and tearing of infundibulopelvic ligaments	Reinforced and resutured	1
7	Sputter in the vault	Ligated	1
8	Isolated rise in PT	FFP transfusion	1

detection of haemoperitoneum (symptoms/sign), time interval between hysterectomy/laparotomy and haemoperitoneum, findings on relaparotomies (causes, site and amount of bleeding), management and the risk factor for bleeding, hospital stay and the outcome of the patients

All data was entered into a master chart and descriptive analyses were conducted using the SPSS 19 software. Qualitative variables were expressed as percentages and quantitative variables as means.

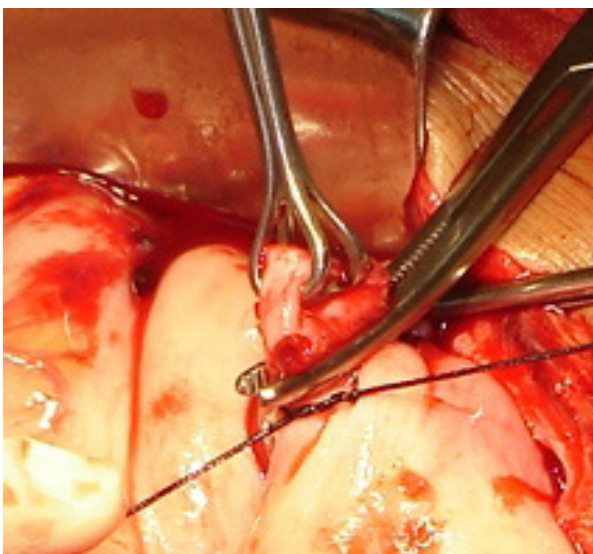


Figure 2. Tying off the pedicle

RESULTS

Over the past 11 years, 27 cases needed relaparotomy/laparotomy for the hemorrhagic complications following Gynaecological surgeries.

Of the total 27 cases the primary surgeries performed were abdominal hysterectomy in 12 (44.4%), Vaginal hysterectomy in 7(26%), laparotomies in 6(22.2%) and diagnostic laparotomy and Abdomino perineal approach in 1(3.7%). (Table 1).

Diagnosis of the intraperitoneal bleeding was made primarily due to features shock in 14 patients. In vaginal hysterectomy hematuria and oliguria after a normal urinary output for 8 hours (1) and suprapubic mass of 12x12 cms (1) were primary suspects of intraperitoneal bleeding. Another one complained of difficulty in passing urine on the 4th post operative day that lead to detection of haemoperitonium. (Table 2)

Detection of intraperitoneal bleeding was made immediately in the OT table and as late as 4 days [< 6 hours (5), 6-12 hours (6), 13-24 hour (6) and > 24 hours in the rest (10) of the cases]. A case was reopened on the 10th postoperative day because of a retroperitoneal haematoma complicating hysterectomy for molar pregnancy.

Abdominal ultrasonography was helpful in almost all the cases as it not only detected

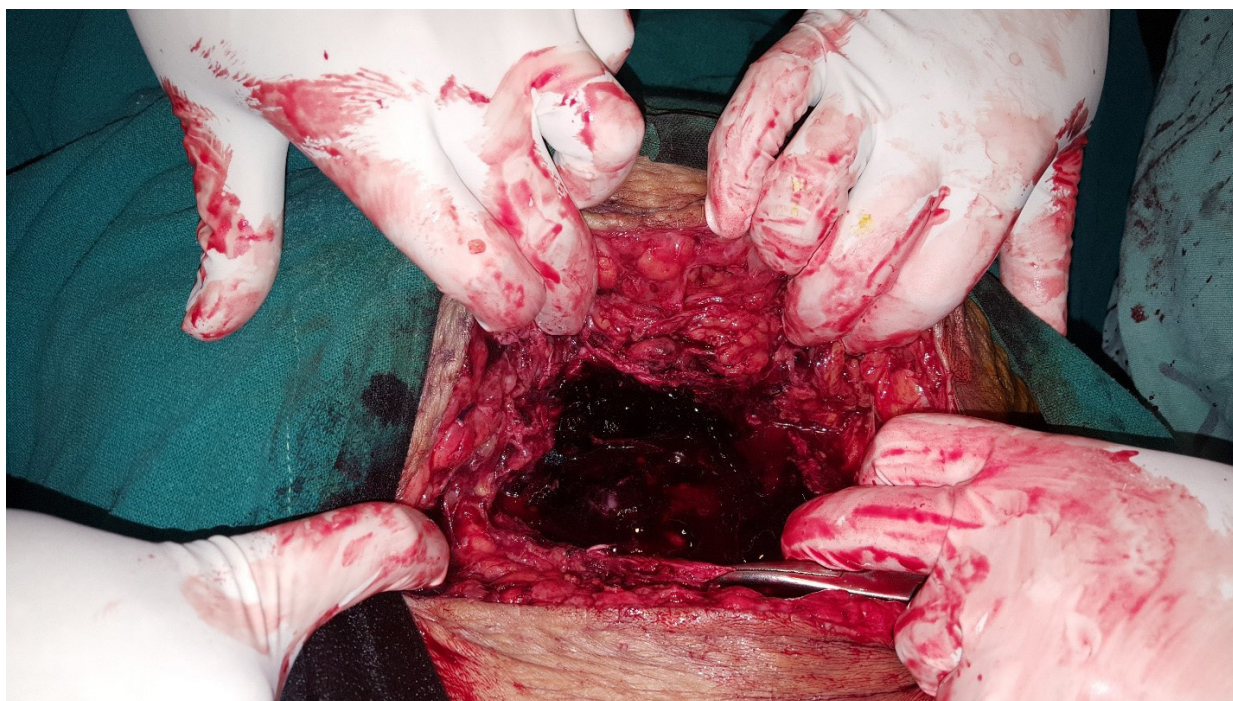

Figure 3. Haematoma in relaparotomy

collection in the pelvis but also fluid extending to the Morrison's pouch was observed. Intraperitoneal blood collection ranged from 400 to 3000 ml

On relaparotomy bleeding from various sites were noted as shown in Table 3. Special consideration is to be given to the 3 cases that were on warfarin for Rheumatic heart disease (RHD) post valvular replacement All the 3 cases underwent TAH with BSO, 2 for fibroid and 1 for dermoid. Following surgery once these patients were put on heparin and then bridged on to warfarin, complications like haemoperitonium and haematoma developed. (Fig1,2, 3).

The risk factors were malignancy (1) and dense pelvic adhesion due to endometriosis (2), and severe hypertension in a case of molar pregnancy in 55 years (1). The last case was diagnosed to have retroperitoneal hematoma, but on the 10th postoperative day following TAH BSO. She was opened with benefit of doubt, which helped her release a huge amount of slightly blood mixed ascetic contents with retroperitoneal hematoma left undisturbed. Rheumatic heart diseases with valvular replacement requiring warfarin/heparin were again alarming risk factors that contributed in relaparotomy (3). Isolated rise in PT was also a risk factor in a case of DUB

that lead to relaparotomy where oozing from multiple sites was observed despite of all the other coagulation factors being normal.

Hospital stay varied from 10-30 days, partly because of soakage from wound infections, and resuture of the abdominal wound. One of the patients on warfarin stayed about a month due to recurrent wound soakage, but later was discharged in good health.

Outcome: Of 27 patients, only 2 succumbed to death. One was following the diagnostic laparoscopy for infertility; required reopening for intraperitoneal hemorrhage twice .She received more than 25 units of blood transfusion and other blood products but subsequently died from adult respiratory distress syndrome.

Second was 35 yrs with III degree prolapse following VH with PFR. Though she had haemoperitonium of 800 ml due to oozing from the bladder base for which cauterization and haemostatic sutures were applied but she died due o anesthetic complications.

DISCUSSION

Complications are not totally avoidable during surgery. Postoperative intraperitoneal hemorrhage after hysterectomy/ laparotomy is a rare but life-threatening complication.

One of the nightmares is to reopen the patient again, which may further lead to increased morbidity and mortality.

Though literature on relaparotomies following gynaecological surgeries is meagre, complications were tactfully combated by relaparotomies as mentioned in two papers written a decade apart.^{8,9} Holub and Jabor reported 2 cases (0.17%) of secondary hemorrhage in their series of 1167 patients with laparoscopic hysterectomy and vaginal hysterectomy.¹⁰ Wilke et al reported an incidence of secondary hemorrhage of 0.23% after vaginal hysterectomy and laparoscopic hysterectomy.¹¹ In an earlier study by Bhattacharya et al, the incidence of secondary hemorrhage was 0.45% after vaginal hysterectomies.¹² Amongst 16,719 cases of laparotomy, a series of 121 relaparotomies had depicted haemorrhage (19%) as one of most important cause for reopening, other than ileus (25%), peritonitis (32%), wound rupture and burst abdomen (22%), and other causes (2%).⁶

Many factors need to be considered that may alter the outcome of the reoperation, like the type of primary surgery and the indication, concurrent medical and surgical diseases, time interval between the primary surgery and the resurgery last but not the least, high index of suspicion.¹³

This paper deals with intraperitoneal hemorrhage where 27 relaparotomy were applied as the second intervention. Seven patients (26%) who underwent vaginal hysterectomy needed resurgery for collection of blood intraperitoneally compared to study by Sak ME et al whose study reviewed the incidence to be 21.2% following total abdominal hysterectomy 3.5% following subtotal hysterectomy and only 2.6% following vaginal hysterectomy.⁹ A total of 20 (74%) relaparotomy were performed following abdominal surgeries; 1(3.7%) after diagnostic laparoscopy, 6(22.2%) after laparotomy and 13(48%) following abdominal hysterectomies including 1 performed both via abdomino-perineal route.

Features of hypovolaemic shock was the primary factor that led to early diagnosis of

the intraperitoneal bleeding in about 50% (14). There was 1 case of endometriosis, 1 of malignancy and 3 of RHD on warfarin post valvular replacement, which were high risk for bleeding. The risk factors could be the contributing factor for reopen as endometriosis causes dense adhesion that could lead to bleeding from the endometritic deposits and bleeding beds. Malignancy is too vascular and even after securing haemostasis the chances of oozing and bleeding from the cancer bed and necrotic tissue remains. Similar association of malignancy and severe degree of endometriosis is cited by Dasgupta Shyamal et al.¹³

Both heparin and warfarin are anticoagulant, that inhibits the clotting of blood and were responsible for causing haemorrhage in 3 patients who were on anticoagulants. Despite of normal coagulation factors, isolated rise in PT was another risk factor in a case of DUB that led to relaparotomy where oozing from multiple sites was observed.

Detection of haemoperitoneum was as quick as on the operation table to as later as 10 days. For the few reported cases in the literature, the time interval varied from 3 to 18 days.^{10,11,14} The contributing factors for early detection were tickling of blood from the vaginal vault during toileting following surgery in the OT table, monitoring the patient in the recovery room when sudden instability in the vitals were observed. Collection of frank blood in cases where drain had been kept was also an alarming sign that led to quick reopen. A good example is where the disligated ovarian pedicle was opened within 3h of surgery with ultrasound detection of free fluid in Morrison's pouch after a postoperative collapse. Demonstration of shifting dullness with increase abdominal girth due to distension was another way of looking into intraperitoneal hemorrhage which was elicited within 12 hours of surgery. But a case of ruptured ectopic tackled by salpingectomy with contralateral tubal ligation when reopened had 1.5 L of hemoperitoneum who had been deceptively well preserved for 20 hours probably due to the infusion of crystalloids and colloids. Therefore early recognition signs of

intraperitoneal hemorrhage are an important aspect since they may not persist for long moving on to fatal ends with temporary illusive sense of recovery. Further the delay the more the blood loss. Up to 3000ml blood loss was recorded and as many as 25 units of blood were transfused.

In case of hysterectomy/laparotomy failure to ligate securely a significant bleeding vessel, bleeding from vaginal cuff and slippage of ligature or avulsion of tissue before or after clamping can be the cause of haemorrhage. It is essential to achieve proper hemostasis to ensure a safe and successful surgery.¹

At relaparotomy/laparotomy various remedies were undertaken. All the cases were opened by senior consultants. Tiny bleeders were either retied with thin silk or cauterized, vault and vaginal haematoms were evacuated, cuff was re-sutured and infundibulopelvic ligament and ovarian vessel was transfixed with thin silk ties. Precautions were taken not to over ride the knots. Blood and FFP were transfused as required. Abdominal washing was done thoroughly and abgel and drains were kept as required.

Following hysterectomy, Dasgupta S et al have also recommended the proper closure of the lateral angles of vaginal vault and also to secure all the pedicles carefully before closure of parietal peritoneum.¹³

Failing all measures recombinant factor VIIa (2.4 mg intravenous injection) was found to be effective prior to relaparotomy.¹⁶ Collagen-fibrin agent (Tacho Comb) has also been found to be a boon for securing perfect hemostasis during laparoscopic approach, judged presently as an attractive alternative to the laparotomy as a second intervention for postoperative bleeding following laparoscopic or vaginal hysterectomy employed in 0.85% (10 /1167).¹⁰

OUTCOME

Unfortunately there was mortality in 2 (4.7%) of the 27 cases. Both the patient succumbed to death related to anesthetic complications and adult respiratory distress syndrome following relaparotomies. Mortality rate has been shared by many studies which

were 3.5% in study by Sak ME et al, and 12.76% in Dasgupta Shyamal et al.^{9, 13}

The mortalities could be related to the primary presentation of the patient rather than to the relaparotomy, a reintervention that brought to evidence the technical errors which can be modified.

RECOMMENDATIONS

Vessel should be ligated with thin 00 vicryl (polyglycolic) so that disligation of vessel is prevented. The vascular pedicles are better tied with thin silk suture to avoid slippage of ligature. Whenever the pedicles are swollen or are very broad like in the case of mucinous cyst adenoma, it is always wise to transfix the pedicles rather than simply tying them. It is superior not to overlay one tie over the other, because if the lower one is looser the end result is not hopeful. It is better to take separate suture than to pile one over the other. Ensure regaining of normal blood pressure (especially with regional anesthetic agents) before closure, this may obviate hematoma from small bleeders. Whenever the doubt exists, it is always better to wash the peritoneal cavity by normal saline which opens up the bleeding capillaries by washing away the clots, which can then be coagulated again. Keeping an abdominal drain for any doubtful venous oozers left behind (not for the arterial bleeders) was much helpful even to detect an arterial bleeding from infundibulopelvic ligament following surgery in case of a dermoid cyst.

CONCLUSION

It is better to acknowledge and anticipate the probabilities of post operative intraperitoneal hemorrhage rather than treat them but at the same time tachycardia and hypotension which are the earliest signs in these cases must be closely monitored and investigated so as to avoid morbidity and mortality. Being more cautious and vigilant at surgery, observing and adhering to general surgical principles obviate the need to reopen.

CONFLICTS OF INTEREST

None declared.

REFERENCES

1. Duff P Sparks J, Hawley C. Extensive. An unusual complication of culdocentesis: intraperitoneal haemorrhage from uterine laceration. *J Reprod Med* 1983; 28(3): 221-2
2. Banas T, Boryczko M, Durzynska-Urbaniec J. Intraperitoneal hemorrhage due to the rupture of right ovarian artery in the second day of puerperium. *Ginekol Pol* 2004; 75(9): 729-32
3. Ghourab S. Abdomino-pelvic packing to control severe haemorrhage following caesarean hysterectomy. *J Obstet Gynaecol* 1999; 19(2): 155-8
4. Mayer HG, Lirmberger M. Early abdominal second interventions following gynecologic surgery. *Zentralbl Gynakol* 1975; 97(11): 692-5
5. Kirk RM. Reoperative surgery for early complications following abdominal and abdominothoracic operations. *J R Soc Med* 1988; 81:7-9.
6. Gunther K, Taubert E, Mehwald J. Disordered postoperative course. A retrospective analysis. *Zentralbl Chir* 1988; 113:384-90.
7. Srivastava P, Qureshi S, Singh U. Relaparotomy: review of indications and outcome in tertiary care hospital. *Int J Reprod Contracept Obstet Gynecol*. 2016 Feb; 5(2):520-524
8. Unalp HR, Kamer E, Kar H, Bal A, Peserkoy M, Onal MA. Urgent abdominal re-exploration. *World J Emerg Surg*. 2006; 1:10.
9. Sak ME, Turgut A, Evsen MS, Soydinc HE, Ozler A, Sak S, Gul T. Relaparotomy after initial surgery in obstetrics and gynecology operations: analysis of 113 cases. *Ginekol Pol*. 2012; 83(6):429-32.
10. Holub Z, Jabor A. Laparoscopic management of bleeding after laparoscopic or vaginal hysterectomy. *JSLs*. 2004; 8:235-238
11. Wilke I, Merker A, Schneider A. Laparoscopic treatment of hemorrhage after vaginal hysterectomy or laparoscopically assisted vaginal hysterectomy (LAVH). *Surg Endosc*. 2001; 15:1144-114
12. Bhattacharya MS, Shinde SD, Narwekar MR. Complications of vaginal hysterectomy, analysis of 1105 cases. *J Postgrad Med*. 1978; 24:221-225
13. Dasgupta Shyamal, Sharma Partha, Pratim Kalra, Aradhan Mukhopadhyay, Partha Mahajan, Kirti, Dasgupta Subhankar: *J Obstet Gynecol India* Vol. 60, No. 6 : November / December 2010 pg 507 – 510
14. Miranda CS, Carvajal AR. Complications of operative gynecological laparoscopy. *JSLs*. 2003; 7:53-58
15. Falcone T, Stovall G. In: Berek JS, Berek DL. *Berek and Novak's Gynecology*. 15th ed. New Delhi: Wolter Kluwer. 2013:831
16. Al-Nuaim LA, Mustafa MS, Abdel Gader AG. Disseminated intravascular coagulation and massive obstetric hemorrhage, management dilemma. *Saudi Med J* 2002 Jun; 23(6):658-62) Ciaglia P, Fersching R, Syniec C. Elective percutaneous dilatational tracheostomy: a new simple bed-side procedure—preliminary report. *Chest* 1985; 87:715-7.