

Efficacy of dexamethasone as an adjuvant to bupivacaine in supraclavicular brachial plexus block

Sagun Ram Vaidya*¹, Sandeep Neupane², Kundu Shrestha³, Tumaya Ghale²

¹Department of Anesthesiology and Critical Care Medicine, Nepal Medical College, Kathmandu, ²Department of Anesthesiology, Gandaki Medical College, Pokhara, ³Department of Anesthesiology, Nepal Armed Police Force hospital, Kathmandu

ABSTRACT

Introduction: Supraclavicular brachial plexus block provides the optimal operating conditions for upper arm surgery. The study was conducted to assess the efficacy of dexamethasone as an adjuvant to bupivacaine in supraclavicular brachial plexus block. **Methods:** An experimental study was performed in Gandaki Medical College and Teaching hospital, Pokhara. Forty patients undergoing surgery of the elbow, forearm, and hand under supraclavicular brachial plexus block, with 0.25% bupivacaine with normal saline (n = 20) in the Group I versus 0.25% bupivacaine with dexamethasone (n = 20) in Group II with an equal volume of 30 ml in each group. Randomization was done and the onset of sensory and motor blockade and duration of analgesia was compared in both groups. Statistical package for the social sciences version 24.0 software was used. Continuous variables like the onset of sensory and motor block and time to first rescue analgesia were assessed with the student's t-test and the chi-square test was applied to assess categorical variables like visual analogue score score. **Results:** The time to onset of sensory block in the bupivacaine only group was 504.10±70.24 seconds compared to bupivacaine with dexamethasone group (255.65±75.28) seconds. The time to onset of motor block in the bupivacaine-only group was 813.00±74.57 seconds compared to bupivacaine with dexamethasone group (524.25±80.38) seconds. Time to first rescue analgesia in bupivacaine only group was 542.5±126.33 minutes compared to bupivacaine with dexamethasone group (1245±325.66) minutes. The difference was statistically significant in all the findings (p<0.0001). **Conclusions:** The study concluded that the addition of dexamethasone to bupivacaine prolongs the duration of analgesia and provides faster onset of sensory and motor blocks.

Keywords: Analgesia, brachial plexus block, bupivacaine, dexamethasone.

*Correspondence:

Dr. Sagun Ram Vaidya
Lecturer, Department of Anesthesiology and
Critical care medicine
Nepal Medical College, Jorpati, Kathmandu
Email: sagunrv@hotmail.com

Submitted: March 24, 2022

Accepted: June 30, 2022

To cite: Vaidya SR, Neupane S, Shrestha K, Ghale T. Efficacy of dexamethasone as an adjuvant to bupivacaine in supraclavicular brachial plexus block. JGMC Nepal. 2022;15(1):63-8.
DOI: 10.3126/jgmcn.v15i1.43999

INTRODUCTION

Regional anesthesia enables site specific, long lasting, and effective anesthesia and analgesia which is suitable for many surgical patients and can improve analgesia.¹ William Stewart Halsted first reported the use of cocaine to block upper extremity nerve in 1884 and performed the first brachial plexus block in 1885.² Brachial plexus block is considered as method of obtaining ideal operating conditions for upper limb surgeries providing extended postoperative analgesia with minimal side effects. It also decreases risk of aspiration due to intact pharyngeal and laryngeal reflexes and maintain haemodynamic stability.³

Brachial plexus block can be done through various approaches along their course such as supraclavicular, interscalenous, infraclavicular and axillary route. However, for anesthesia and perioperative pain management below shoulder joint surgeries, supraclavicular approach provides most consistent and easiest method compared to other approaches.⁴ However, pneumothorax,^{4,5} hemothorax,⁴ horner's syndrome,⁴ phrenic nerve block⁴ are the potential complication of Supraclavicular block. Ultrasonography guided supraclavicular brachial plexus block also allows better visualization of underlying

structures, movement of the needles and thereby making procedure safe and effective.⁶

Local anesthetics when used alone for supraclavicular brachial plexus block provide good operative conditions but inevitably, the effects dissipate after several hours unmasking the moderate to-severe pain of the surgical insult.⁷ So, in order to prolong the effect of local anesthetics various adjunct like morphine, tramadol, fentanyl, clonidine, dexmedetomidine midazolam were also added.⁸ Recently steroids particularly dexamethasone has been studied as an adjuvant to local anesthetics in brachial plexus block.⁹ Dexamethasone is a very potent and long acting ($t_{1/2} >36h$) glucocorticoid having potent anti-inflammatory and analgesic effects. It has nerve block prolonging effects and also produce analgesia by blocking transmission of nociceptive non-myelinated c-fibers. They might bring about this effect by altering the function of potassium channels in the excitable cell.¹⁰ Dexamethasone also causes degree of vasoconstriction to the tissue and local anesthetic will have a slower uptake and absorption, thus prolonging its duration of action.¹¹ The study was conducted with objective to compare the onset of sensory block and motor block along with duration of analgesia between two groups when dexamethasone is added as an adjuvant to bupivacaine in supraclavicular brachial plexus block.

METHODS

This is a quantitative, experimental study performed in Gandaki Medical College from June 2019 to June 2020. Adult patients of either sex aged 18 to 60 years, American Society of Anesthesiologists (ASA) physical status I or II, patient posted for elective orthopedics surgery of elbow, forearm and hand under supraclavicular brachial plexus block were included. Patients with history of hypersensitivity to drugs in study, peptic ulcer diseases, diabetes mellitus, renal failure, hepatic failure, neuromuscular or psychiatric disease, patient receiving psychotropic drug, chronic analgesic therapy Coagulation disorders, pregnancy and lactation, skin lesion at the site of injection, duration of surgery more than three hours, failure to get sensory motor block or need of other modality of anesthesia were excluded from the study.

Pre-anesthetic evaluation was done day before surgery. Written informed consent was obtained from each patient after explaining about the study & anesthetic procedure. VAS scoring system for the assessment of pain consisting of 10 cm line with 0= no pain and 10= worst possible pain was explained to the patient. The patients were randomly

allocated into two groups of 20 each in which group using lottery system. Group I received 0.25 % bupivacaine with 2 ml normal saline and group II received 0.25 % bupivacaine with 2ml dexamethasone (8 mg) with equal volume of 30 ml in each group. Study drug was prepared by anesthesiologist not involved in the study and anesthesiologist performing block was blinded about the study drug. Heart rate (HR), systolic and diastolic blood pressures, respiratory rate and oxygen saturation (SpO_2) was recorded just before the block and at five minutes intervals thereafter. An intravenous drip was started before undertaking the procedure with 18 G cannula which continued throughout the duration of surgery for maintenance fluid.

Patient was kept in supine position with head turned to the opposite side of the block and ipsilateral forearm adducted. Injection site was prepared by aseptic technique with povidine iodine solution. Block was performed with the help of 22 G 2" insulated blunt beveled nerve stimulating needle with peripheral nerve stimulator (Stimuplex ®; B Braun) and portable ultrasonography machine (Alpinion E-CUBE 7). Portable ultrasound machine with linear superficial probe (4.2 cm) with frequency of 5 to 10 MHz was used. The USG probe was covered with sterile plastic sheath and sterile ultrasound gel was used for better visualization of image and minimization of interference. After identifying brachial plexus a skin wheal was created with lidocaine 1% 2 ml and stimulating needle was advanced by in-plane approach with respect to the probe. In real time vision and with the help of peripheral nerve stimulator, motor response to the electrical stimulus was observed in corresponding area of the hand. The nerve stimulator was set at frequency of 1 Hz with current strength of 2 mA. After obtaining motor response the strength of the current was gradually decreased and if the motor response persisted even at 0.3 to 0.5 mA, local anesthetic was injected under ultrasound vision. Total volume of 30 ml of 0.25% plain bupivacaine with normal saline or dexamethasone was injected increasingly with aspiration after each 5 ml of injection. The inter-costobrachial nerve (T2) was also blocked with 5 ml of 2% lignocaine with 1:200000 adrenalin to avoid tourniquet pain.

Sensory block was tested by using pin prick and assessed by three-point scale:

- 0= normal sensation,
- 1= loss of sensation to pin prick (analgesia),
- 2= loss of sensation to touch (anesthesia).

The palmar surfaces of the index and little finger was used to test the median and ulnar nerve in the hand, respectively.

To test the radial nerve the dorsal surface of the thumb was used.

Motor Score (Modified Bromage Scale)¹²

0= able to raise the extended arm to 90° for full two seconds

1= Able to flex the elbow and move the fingers but unable to raise the extended arm

2= Unable to flex the elbow but able to move fingers

3= Unable to move the arm, elbow, or fingers

Both sensory and motor block was assessed every five minutes till acceptable sensory and motor blockade of whole arm was achieved or 30 minutes whichever is shorter.

Score 1 for sensory and score 2 for motor block was considered to be adequate for the procession of surgery. The brachial plexus block was supplemented by intravenous sedation (midazolam 0.015 mg/kg intravenously) and repeated in 30 to 60 minutes as needed. In the event of failure to achieve acceptable sensory and/or acceptable motor blockade, the patient was administrated general anesthesia and was excluded from the study. Pain was assessed every 15 minutes during the first hour, every 30 minutes in the next hour and then hourly. After the operation, patient was asked to fill up the visual analogue scale (VAS). Duration of analgesia was considered from the time of onset till the requirement of first rescue analgesia. Rescue analgesic injection sodium diclofenac 75 mg intra muscularly was given when VAS score is ≥ 5 .

Pain was assessed by using VAS score (0= no pain, 5= moderate pain, 10= worst pain possible) every 15 minutes after the surgery in first hour, every 30 minutes during the second hour and hourly thereafter. The time of onset of acceptable sensory block is defined as the interval between the completion of injection and loss of pain in pinprick sensation (Grade 1) on palmar surfaces of the index and little finger dorsal surface of the thumb and at around the injury site of forearm. The onset time of acceptable motor block defined as the time between the completion of the local anesthetic injection and unable to flex the elbow but able to move the fingers (Grade 2).

Heart rate, systolic blood pressure, diastolic blood pressure, SpO₂ was recorded every 5 minutes till the end of the surgery. Sample size was estimated based on a pilot study of 60 patients with 1.96 (95% confidence interval) and 1.64 (power 95%). Total sample calculated was 40. Statistical analysis was performed with statistical package for social science (SPSS) version 24.0. The observations

recorded in both groups were tabulated and statistical analysis of demographic data and comparison of groups was carried out using Student's t-test (paired for intragroup and unpaired for intergroup comparison) and chi-square test. The p-value of <0.05 was taken to be statistically significant.

RESULTS

The mean onset of sensory block was faster in dexamethasone with bupivacaine group (group I) than in bupivacaine with normal saline group (group II). The mean time in group I was 255.65 seconds and in group II was 504.1070.243 seconds which was statistically significant ($p<0.0001$). (Figure 1)

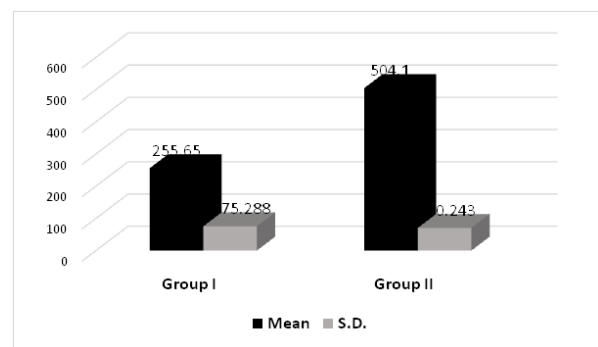


Figure 1: Onset of sensory block

The mean onset of motor block was faster in dexamethasone with bupivacaine group (group I) than in bupivacaine with normal saline group (group II). The mean time in group I was 524.2580.382 seconds and in group II was 81374.576 seconds which was statistically significant ($p<0.0001$). (Figure 2)

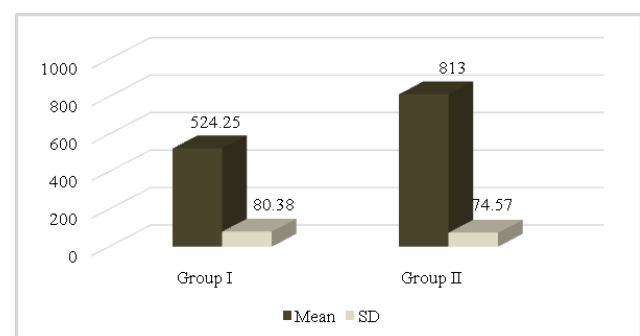


Figure 2: Onset of motor block (sec)

The mean time to first rescue analgesia among the two groups were highly variable. The mean time to first rescue analgesia in bupivacaine with dexamethasone group (Group I) was 1245 ± 325.66531 minutes and in bupivacaine with normal saline group (Group II) was 541.5000 ± 126.33602 minutes which was significant statistically ($p<0.001$). (Figure 3)

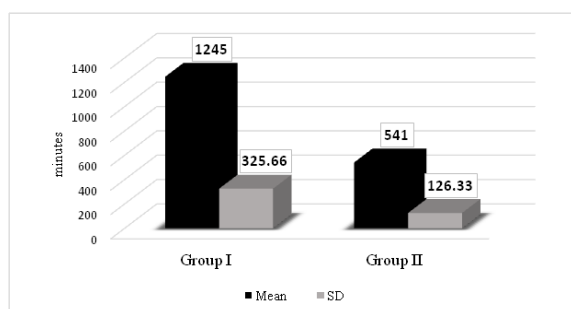


Figure 3: Time for first rescue analgesia

No statistically and clinically significant changes were observed in hemodynamic and respiratory parameters in either group and demographic variables such as age, weight, gender, ASA.

DISCUSSION

Regional anesthesia because of its simplicity of technique, avoidance of airway manipulation and instrumentation, preservation of consciousness and rapid recovery with adequate post-operative analgesia confers advantage over other choices of anesthesia. The brachial plexus consists of injecting local anesthetic agents in fascial plane surrounding the nerve plexus, thereby blocking autonomic, sensory and motor fibers supplying upper extremity.

In our study the patients characteristics (age, weight, sex, ASA) were similar in two groups and not significant. On comparison of heart rate, systolic and diastolic blood pressure in both groups at different intervals, no significant difference was observed. None of the patient had bradycardia, tachycardia, hypertension or hypotension following administration of dexamethasone along with local anesthetic agents. Our finding was similar to that of Baloda et al.,³ Choi et al.,⁷ and Shrestha et al.⁹ who also found no significant difference in hemodynamic parameters on addition of dexamethasone.

Our study is comparable with study conducted by Shrestha et al.⁹ in which they had used a mixture of lidocaine 2% with 1:200,000 adrenaline and bupivacaine 0.5%, dexamethasone was added to the local anaesthetic solution in the steroid group. They demonstrated that there was significant faster onset of action and prolonged duration of analgesia in dexamethasone group than in local anesthetic group. However, compared to our study delayed onset of action in this study could be due to use of mixture of lignocaine and bupivacaine which might have altered individual concentration, pKa and the pH of the solutions and also use of paresthesia technique compared to use of real time ultrasonography with peripheral nerve stimulator in our study. Regarding duration of analgesia, it was found prolonged in dexamethasone group which was

statistically significant, similar to this in our study duration of analgesia was significant in dexamethasone but was higher in our study. This may be due to use of real time ultrasonography with peripheral nerve stimulator in our study.

Our study was also comparable with Baloda et al.,³ they concluded that onset of sensory and motor block were faster in levobupivacaine with dexamethasone group and duration of analgesia was also significantly higher in dexamethasone group compared to levobupivacaine with normal saline group. The results were similar to our study. However, the prolonged onset of mean sensory block and mean onset of motor in this study than in our study may be due to use of paraesthesia technique in this study vs use of real time ultrasonography combined with peripheral nerve stimulator in our study.

Our study was also similar to the study conducted by Biradar et al.,¹³ who demonstrated effect of dexamethasone added to lidocaine in supraclavicular brachial plexus block using peripheral nerve stimulator. The onset of sensory and motor blockade was significantly more rapid in dexamethasone group than in control group. However, compared to our study the duration of onset of sensory block and motor is higher in this study. This could be because in their study position of needle was considered to be acceptable when distal motor response was observed with output current of less than/equal to 0.6 mA whereas in our study position of needle was considered to be acceptable when distal motor response was observed with output current of less than/equal to 0.5mA under ultrasound vision. So, deposition of local anaesthetic was closer in vicinity of brachial plexus, as well as under ultrasound guidance could be the explanation for quicker onset of sensory and motor block.

Another study done by Pathak et al.,¹⁴ patients were divided into two groups in which one group received 1.5% lidocaine + Bupivacaine 0.5% + dexamethasone 8 mg, while another group received 1.5 % lidocaine + 0.5 % bupivacaine + normal saline. They concluded that dexamethasone did not produce significant difference in onset time of sensory and motor block. However, duration of analgesia was significantly prolonged in dexamethasone group compared to normal saline group, which was comparable with our study.

The study conducted by Gandhi et al.¹⁵ divided the patients into two groups where one group received 2% lignocaine with adrenaline with 0.5% bupivacaine and another group received added dexamethasone 4 mg. They concluded that there was significantly faster onset of sensory and motor

block when dexamethasone was added. Also duration of analgesia was prolonged in dexamethasone group. The results in this study very much correlated with the results in our study.

In a similar study conducted by Alarasan et al.,¹⁶ who demonstrated effect of dexamethasone along with bupivacaine in low volume supraclavicular brachial plexus block. They concluded that there was significant rapid onset of both sensory and motor block in dexamethasone group compared to bupivacaine group alone. The duration of sensory block was also prolonged in dexamethasone group. The result in this study was comparable with the result in our study. However, the author in this study used low volume 20 ml of bupivacaine and dexamethasone in contrast we used total volume of 30 ml of bupivacaine and dexamethasone.

For successful regional anesthetic block to ensure the key requirement is optimal distribution of local anesthetics around nerve structures. This goal is effectively achieved under sonographic visualization. Ultrasonographic visualization results in decreased performance time, lessen patient discomfort and also decreases onset time of local anesthetics.¹⁷

In our study with the aid of ultrasonography in peripheral nerve stimulator assisted supraclavicular brachial plexus block in upper limb surgeries, the onset of sensory and motor block and duration of analgesia block significantly faster. The reason behind faster onset may be due to real-time visualization of target nerves and deposition of local anesthetics in close proximity to the nerves. As the anatomy of human body is variable and these variables are unrecognizable during the performance of either paresthesia or peripheral nerve stimulator technique,¹⁸ with the use of only peripheral nerve stimulator, target nerve can be far away from needle and deposition of local anesthetics in such conditions can lead to delayed contact of local anesthetics with nerves and hence delayed onset of action.

In a prospective study, Williams et al.¹⁷ assessed the quality, safety, and execution time of supraclavicular blocks of the brachial plexus using ultrasonic guidance and neurostimulation compared with a supraclavicular technique that used anatomical landmarks and neurostimulation. They concluded that that ultrasound-guided neurostimulator-confirmed supraclavicular block is more rapidly performed and provides a more complete block than supraclavicular block using anatomic landmarks and neurostimulator confirmation.

This study still bears some limitations. The limited number of cases were enrolled in the study. Only perineural use of dexamethasone was compared with control group and effect of dexamethasone via other routes were not observed and only immediate post-operative complications following supraclavicular brachial plexus block were observed.

CONCLUSIONS

From our study, we can conclude that the addition of dexamethasone 8 mg to 0.25% bupivacaine in supraclavicular brachial plexus block fastens the onset of action of sensory and motor block and prolongs the duration of analgesia significantly when compared to use of bupivacaine alone.

CONFLICT OF INTEREST: None declared

SOURCE OF FUNDING: None

REFERENCES

1. Tziavrangos E, Schug SA. Regional anaesthesia and perioperative outcome. *Curr Opin Anaesthesiol.* 2006;19(5):521-5. DOI: 10.1097/01.aco.0000245278.22658.1e PMID: 16960485.
2. Regmi NK, Subba S, Sharma UC. A Comparative Clinical Evaluation of Efficacy of Tramadol as an Adjuvant To Bupivacaine En Brachial Plexus Block For Upper Limb Surgery. *Journal of Nepalgunj Medical College.* 2015;13(2):13-6. DOI: 10.3126/jngmc.v13i2.16535
3. Baloda R, Bhupal JP, Kumar P, Gandhi GS. Supraclavicular Brachial Plexus Block With or Without Dexamethasone as an Adjuvant to 0.5% Levobupivacaine: A Comparative Study. *J Clin Diagn Res.* 2016;10(6):Uc09-12. DOI: 10.7860/JCDR/2016/18325.8048 PMID: 27504384.
4. Kothari D. Supraclavicular brachial plexus block: A new approach. *Indian journal of anaesthesia.* 2003;47(4):287-8.
5. Moore D. Supraclavicular approach for block of the brachial plexus. *Regional block A handbook for use in the clinical practice of medicine and surgery, 4th ed* Springfield, Charles C Thomas Publisher. 1981:221-42.
6. Verma V, Rana S, Chaudhary SK, Singh J, Verma RK, Sood S. A dose-finding randomised controlled trial of magnesium sulphate as an adjuvant in ultrasound-guided supraclavicular brachial plexus block. *Indian J Anaesth.* 2017;61(3):250. DOI: 10.4103/ija.IJA_466_16 PMID: 28405040.
7. Choi S, Rodseth R, McCartney CJ. Effects of dexamethasone as a local anaesthetic adjuvant

- for brachial plexus block: a systematic review and meta-analysis of randomized trials. *Br J Anaesth.* 2014;112(3):427-39. DOI: 10.1093/bja/aet417 PMID: 24413428.
8. Edinoff AN, Houk GM, Patil S, Siddaiah HB, Kaye AJ, Iyengar PS, et al. Adjuvant drugs for peripheral nerve blocks: The role of alpha-2 agonists, dexamethasone, midazolam, and non-steroidal anti-inflammatory drugs. 2021;11(3). DOI: 10.5812/aapm.117197
 9. Shrestha BR, Maharjan SK, Tabedar S. Supraclavicular brachial plexus block with and without dexamethasone - a comparative study. *Kathmandu Univ Med J.* 2003;1(3):158-60.
 10. Oliveira JM. Does The Addition Of Dexamethasone To Local Anesthetic Used For Peripheral Nerve Block Prolong Analgesia In The Surgical Patient? 2015. Available from: https://dune.une.edu/na_capstones/3 [Accessed on 30th May 2022]
 11. Suzuki S, Gerner P, Lirk P. Local anesthetics. *Pharmacology and Physiology for Anesthesia: Elsevier;* 2019. p. 390-411. DOI: 10.1016/B978-0-323-48110-6.00020-X
 12. Breen TW, Shapiro T, Glass B, Foster-Payne D, Oriol NE. Epidural anesthesia for labor in an ambulatory patient. *Anesthesia and analgesia.* 1993;77(5):919-24.
 13. Biradar PA, Kaimar P, Gopalakrishna K. Effect of dexamethasone added to lidocaine in supraclavicular brachial plexus block: A prospective, randomised, double-blind study. *Indian J Anaesth.* 2013;57(2):180. DOI: 10.4103/0019-5049.111850 PMID: 23825819.
 14. Pathak R, Satkar AP, Khade RN. Supraclavicular brachial plexus block with and without dexamethasone—a comparative study. *International Journal of Scientific and Research Publications.* 2012;2(12):1-7.
 15. Gandhi M AK, Panwar N, Gupta N. . Effect of addition of dexamethasone to local anesthetic agent in supraclavicular brachial plexus block. *A comparative study. International J of Medical Research* 2018;3(2):70-4.
 16. Alarasan AK, Agrawal J, Choudhary B, Melhotra A, Uike S, Mukherji A. Effect of dexamethasone in low volume supraclavicular brachial plexus block: A double-blinded randomized clinical study. *J Anaesthesiol Clin Pharmacol.* 2016;32(2):234-9. DOI: 10.4103/0970-9185.182108 PMID: 27275056.
 17. Williams SR, Chouinard P, Arcand G, Harris P, Ruel M, Boudreault D, et al. Ultrasound guidance speeds execution and improves the quality of supraclavicular block. *Anesthesia & Analgesia.* 2003;97(5):1518-23. DOI: 10.1213/01.ANE.0000086730.09173.CA PMID: 14570678.
 18. Brown AR. Ultrasound versus peripheral nerve stimulator for peripheral nerve blockade: Pros and cons. *Revista Mexicana de Anestesiología.* 2008;31(S1):79-84.