

Seizure and unilateral facial nerve paralysis in a newborn with Dandy-Walker malformation – A case report

S Bhakta,¹ S Pal,² A Chatterjee,³ A Pan⁴

¹Junior Resident, MD Pediatrics,²Assistant Professor, Department of Pediatric Medicine, Medical College and Hospital, Kolkatta, ³Associate Professor, Department of Pediatric Medicine, Calcutta National Medical College, Kolkatta, ⁴Lecturer, Department of Pediatric Medicine, College of Medical Sciences, Bharatpur.

Abstract

The Dandy-Walker syndrome (DWS) is a rare posterior fossa malformation. It can have a varied presentation depending on the age. A newborn presenting with neonatal seizure along with unilateral facial nerve palsy is rather a rare presentation of DWS and very few such cases were reported in the past. We are reporting a case of a newborn male baby presenting with neonatal seizure within 48 hrs of birth along with right sided LMN type facial nerve palsy which on due course of investigation revealed as a case of Dandy-Walker malformation.

Case report

A 36 hours old male newborn of 2.6 kg weight delivered at term by elective cesarean section presented to our NICU with repeated convulsion and depressed cry, reflex and activity. The baby was the 1st child of a non consanguineous marriage. The baby cried immediately after birth. No history of prolonged labour, birth trauma, premature rupture of membrane, maternal fever, maternal diabetes mellitus, nonsignificant maternal drug history and antenatal period was uneventful.

The baby appeared appropriate for gestational age without any external deformity. Capillary refill time, tone, colour, fontanelle were within normal limit. Heart rate was 156/min, respiratory rate was 68/min, head circumference was 33cm.

We excluded hypoglycaemia, hypocalcemia and hypomagnesemia. Convulsions were controlled by

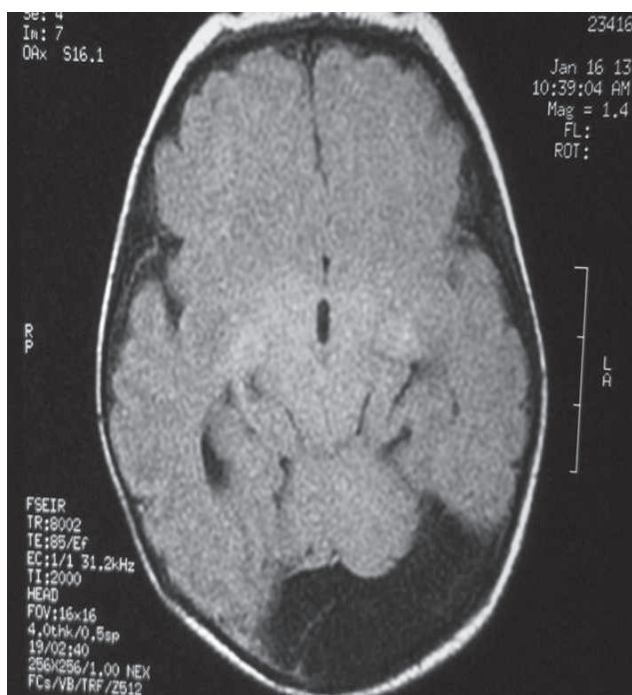Correspondence: Dr. Subhajit Bhakta
E-mail: drsubhajitbhakta@gmail.com

loading and 1st half loading of I.V phenobarbitone and no convulsion occurred thereafter. Baby was put on IV 10% dextrose, I.V Cefotaxim and Amikacin, Vit K and moist oxygen. Complete hemogram showed Hb-18.6 gm/dl, TLC-12600/cmm (N-40, L-55, E-5), platelet count-2.1 lakh/cmm. Sepsis screen was negative. Blood culture showed no growth and CSF examination revealed 2 cells (all mononuclear cells), CSF sugar 66 mg/dl and protein 82 mg/dl. The baby remained depressed for first 72 hrs.

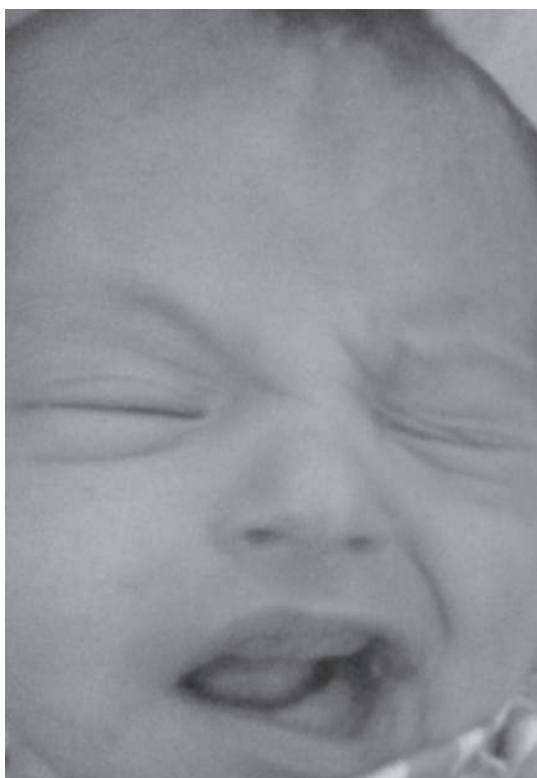On the 4th day of life we noted right side lower motor neurone type (LMN) facial nerve paralysis. Ocular movement and movement of all 4 limbs appeared to be normal. USG brain on 5th day revealed agenesis of posterior part of corpus callosum without any evidence of intracerebral or intraventricular hemorrhage. MRI brain showed - partial agenesis of corpus callosum with prominent medial borders of lateral ventricles with high

rising 3rd ventricle,agenesis of cerebellar vermis with 4th ventricle directly opening into fairly large cistern magna,pituitary fossa and brain stem remaining normal.The MRI finding was suggestive of Dandy-Walker malformation. We did an Echocardiography to exclude associated cardiac abnormality which was essentially normal apart from a small patent foramen ovale(PFO).

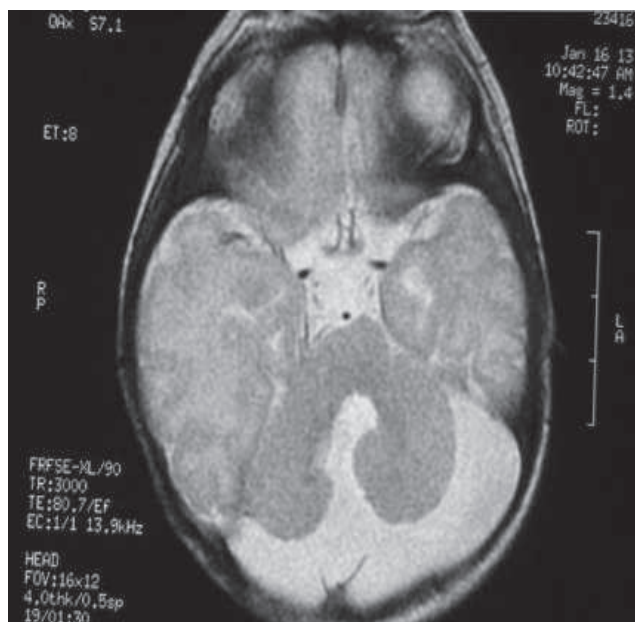
We reviewed antenatal serial USG abdomen reports of the mother which didn't cite any fetal abnormality. Neurosurgery consultation was taken and they advised for routine follow up and provision of early shunt surgery.We discharged the patient with oral phenobarbitone with prognosis explained to the parents.



MRI brain showing large cystic dilatation of 4th ventricle and large cisterna magna.



4th day old baby with right sided LMN type facial nerve palsy having dandy walker malformation.



MRI brain showing large cystic dilatation of 4th ventricle and large cisterna magna.

suspected by using computed tomography (CT scan) and ultra-sound. MRI evaluation can be used antenatally to confirm the diagnosis and gain more detailed information.¹¹

Treatment for Dandy-Walker malformation is directed to reduce the raised intracranial tension by cystoperitoneal or ventriculoperitoneal shunt or both. In smaller children with moderate hydrocephalus, cyst drainage tends to be successful.

The patients with DWS may never have normal intellectual development even when management of hydrocephalus is done early. Prognosis otherwise depends on the severity of the syndrome and associated malformations. The presence of multiple congenital defects may shorten lifespan.

Therefore, idea of this case presentation is to convey that DWS can have an early presentation since birth. Neonatal seizure with unilateral facial nerve paralysis in a newborn is rather a rare presentation of DWS. Corpus callosum agenesis as an USG brain finding may be isolated but ideally be followed by a MRI brain to exclude other brain defects like DWS. If it is diagnosed early then early shunt surgery has a better prognosis.

References

1. Hart MN, Malamud N, Ellis WG. The Dandy-Walker syndrome: a clinicopathological study based on 28 cases. *Neurology* 1972;**22**:771-80.
2. Hirsch JF, Pierre-Kahn A, Renier D, et al. The Dandy-Walker malformation. *J Neurosurg* 1984;**61**:515–22.
3. Klein O, Pierre-Kahn A, Boddaert N, et al. Dandy-Walker malformation: prenatal diagnosis and prognosis. *Childs Nerv Syst.* 2003;**19**(7-8):484-9. Epub 2003 Jul 16.
4. Imataka G, Yamanouchi H, Arisaka O. Dandy-Walker syndrome and chromosomal abnormalities. *Congenital Anomaly (Kyoto)*, 2007;**47**(4):113-8.
5. Lavanya T, Cohen M, Gandhi SV, et al. A case of a Dandy-Walker variant: the importance of a multidisciplinary team approach using complementary techniques to obtain accurate diagnostic information. *British Journal Radiology* 2008; **81**(970):e242-5.
6. Hynd, G., Morgan, A. And Vaughn, M. Magnetic Resonance in the diagnosis of C.N.S Disorders. CIC Edizioni, pp 27-8
7. Kaplan LC (Dec 1985). "Congenital Dandy Walker malformation associated with first trimester warfarin: A case report and literature review". *Teratology* **32** (3): 333–7.
8. Taylor FR, Larkins MV. Headache and Chiari I malformation: clinical diagnosis, and controversies in management. *Curr Pain Headache Rep* 2002;**6**:331-7.
9. Sasaki-Adams D, Elbabaa SK, Jewells V, et al. The Dandy-Walker variant: a case series of 24 pediatric patients and evaluation of associated anomalies, incidence of hydrocephalus, and developmental outcomes. *J Neurosurg Pediatr.* 2008;**2**(3):194-9. doi: 10.3171/PED/2008/2/9/194.
10. Zimmerman RA, Bilaniuk LT; Magnetic resonance evaluation of fetal ventriculomegaly-associated congenital malformations and lesions. *Semin Fetal Neonatal Med.* 2005;**10**(5):429-43.