

Umbilical Myiasis in a Newborn: a case report

PK Dey,¹ T Bhattacharya,² SN Pal,² S Das,² S pal,³

¹MD Resident, ²Junior Resident, ³Assistant professor, Department of Paediatrics, Calcutta Medical College, Kolkata

Abstract

Myiasis is an infection of live mammalian tissue by the larval forms of dipteran flies, usually infects domestic and wild animal but human may be affected sometimes. Although adult cases have been reported, neonatal myiasis is a rare condition. Umbilical myiasis is very rare in newborns with few reported cases in the literature. In this article we are reporting an eight day old female neonate from urban slum area in West Bengal (India) presented with umbilical myiasis and omphalitis. She was infected with *Chrysomya* spp. larvae, was clinically well.

Key words: *Myiasis, Neonate, Umbilical, Chrysomya*

Introduction

Myiasis is defined as the invasion of live mammalian tissue by the larvae of dipteran flies which feed on the host's dead or living tissue, body fluids or ingested food,¹ commonly seen in the tropics and subtropics.² It usually infects domestic and wild animal but human may be affected sometimes reared in poor hygienic conditions.³ However, neonatal myiasis is a very rare clinical state that is almost always found in tropical areas.⁴ Neonatal myiasis is briefly mentioned in only two of the three major American pediatric textbooks,⁵ and with few reported cases in the literature.

Herein, we report a 8-day-old female infant from an urban slum area in West Bengal (India) who was referred to us with umbilical myiasis which is a very rare occurrence. The natural mummification of fetal tissue during the umbilical separation process is not well described as a risk factor in literature for myiasis

and, similarly the best means to protect this process are still unclear.⁶ The aim of this work was to describe a case of umbilical myiasis produced in a neonate living in an urban area.

Case report

An eight day old female neonate from an urban slum area in West Bengal (India), born out of nonconsanguineous marriage belonging to a poor socioeconomic status presented with history of something coming out from the umbilical region and umbilical bleeding after feeling the umbilical cord. This baby was delivered vaginally at Kolkata Medical college. Her gestational, intrapartum and postpartum periods were unremarkable, both mother and child were discharged from hospital on next day.

On clinical examination this neonate weighed 2.3 Kg, her cry, reflex and activities were satisfactory, respirations were 30 breaths/min and the pulse rate

Correspondence: Dr. Pranab Kumar Dey
E mail : drpranabdey@gmail.com

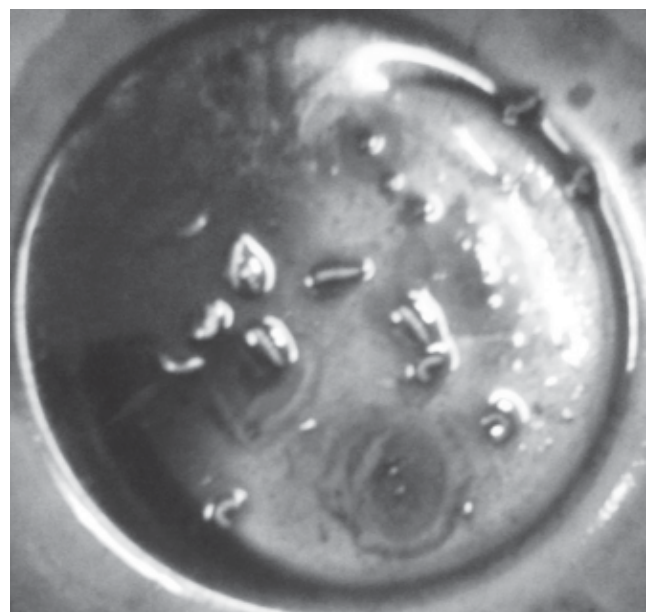
was 134 per minute. The baby was noted to have a soft fontanelle, no hepatosplenomegaly and normal cardiorespiratory system findings. There was mild omphalitis and cellulitis. The cord was absent at umbilicus and on close observation movements of some live 10 to 12-mm-long cylindrical white maggots were noted at the base of the umbilicus (**Fig 1**). In the next 3 hours, 15 maggots bored out of umbilicus following instillation of ether (repellent) and more than 35 maggots were removed within 24 hours of hospital admission. On the second day of admission ultrasound examination were done and showed no maggot or umbilical abscess. Following removal, the maggots were preserved in 80% of alcohol and sent to department of Parasitology, School of Tropical Medicine, Kolkata for microscopic examination and species identification. The maggot was found to be of *Chrysomya megacephala*.

Intravenous administration of cefotaxime (100 mg/kg of body weight a day) and amikacin (15 mg/kg a day) was begun. A complete blood count showed a hematocrit level of 48 ml/dl and the red blood cell morphology was normal. The leukocyte count was 9800/mm³ with a differential cell count of 2% band forms, 42% segmented forms, 5% eosinophils, 50% lymphocytes and 1% monocytes. Blood culture and urine analysis was normal. There was no evidence of sepsis. As soon as all larvae were out of the epidermis, the omphalitis rapidly resolved with no sequelae. On the 5th day antibiotic medications were stopped and the infant was discharged from the hospital under satisfactory physical and clinical condition.

Fig 1: Few maggots emerging from the umbilicus of a newborn.

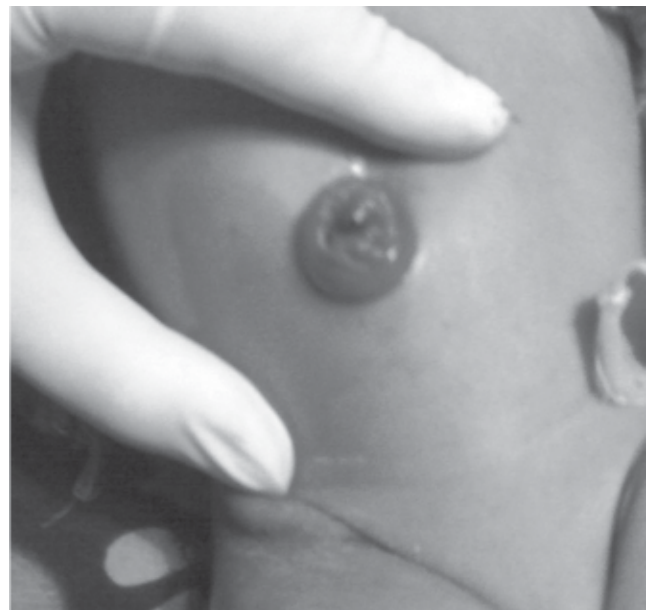

Fig 2: The macroscopic view of the larvae that crawled out of the umbilicus.



Discussion

Umbilical myiasis, a type of cutaneous tissue myiasis, is usually produced by larvae of flies (Diptera) of

various kinds which invade the live mammalian tissue, feed on the host's dead or living tissue, body fluids or ingested food.¹ In umbilical myiasis the fly lays eggs on dry skin and the larvae subsequently invade the wound. Larvae grow rapidly and reach maturity in 4-8 days.⁷ Typical larvae are cylindrical, whitish, segmented, legless, and headless, ranging in length from 1 to 30 mm.⁸ The larvae are removed from the affected site of the host by irrigation, manipulation or surgery.⁹ The larvae should be killed and preserved properly for species identification. Identification of the maggot can be crucial in determining pathogenesis and as well as controlling of the disease. Third stage larva is ideal for species identification.⁹ In our case, the larvae were investigated in the Department of Parasitology, School of Tropical Medicine, Kolkata and were diagnosed as *Chrysomya megacephala*, a member of *Chrysomya* genus in the Calliphoridae family of blowflies. The macroscopic view of the larvae that crawled out of our patient's umbilicus in a bowl (**Fig 2**).

Chrysomya megacephala, more commonly known as the Oriental Latrine Fly, is known to breed in human feces, meat and fish. In the Indian population (especially rural or urban slum area) defecating in open air is a common practice. The fly is attracted by feces and lays eggs on them. After landing on feces it lands commonly on human foods and on very rare occasion on open human wounds or on umbilicus of a newborn.¹⁰ There was a butcher's shop near their house. There were no other myiasis cases reported from that region at that time. Therefore, myiasis may have originated from the butcher's shop and a fly dropped the eggs on her umbilicus. In India sun-drying fish is a preservation method for sending the fish form where

they are caught to the location of markets and consumers. However, blowfly larvae tend to infect these sun-dried fish when the weather is warm and humid. An experiment was done to observe which flies show up around these sun-dried fish the most, and 95% were *C. megacephala*.¹¹

Either of these two may be the mode of infection in our case.

Removal of maggots, use of local antiseptics, and systemic antibiotics for combating secondary infections have been recommended as treatment options in neonatal myiasis.⁵ Our patient was given proper antibiotics and larvae were removed by using ether in the hospital. Her findings resolved with therapy and no adverse effects were seen. So once the diagnosis has been made, the treatment is usually straightforward and uncomplicated.

Conclusion

We report this case to emphasize the importance of patient education in matters of personal hygiene especially in neonates and to maintain clean surroundings around our living areas.

References

1. Yüca K, Caksen H, Sakin YF, et al. Aural myiasis in children and literature review. *Tohoku J Exp Med.* 2005;**206**: 125-30.
2. Noutsis C, Millikan LE. Myiasis. *Dermatol Clin.* 1994;**12**: 729-36.
3. Ghosh T, Nayek K, Ghosh N et al. Umbilical myiasis in newborn. *Indian Pediatr.* 2011;**48**:32-3.

4. Clark JM, Weeks WR, Tatton J. Drosophila myiasis mimicking sepsis in a newborn. *Western J Med* 1982;**136**:443-4.
5. Bapat SS. Neonatal myiasis. *Pediatrics*. 2000;**106**:E6.
6. Zupan J, Garner P, Omari AAA. Topical umbilical cord care at birth The Cochrane Database of Systematic Reviews 2004, Issue 3. Art. No. CD001057.pub2. DOI: 10.1002/14651858.CD001057.pub2.
7. Piangjai S, Siriwattananarungsee S, Sukontason KL, Sukontason K. Morphology and developmental rate of blowflies *Chrysomya megacephala* and *Chrysomya rufifacies* in Thailand: application in forensic entomology. *Parasitol Res*. 2008;**102**:1207-16.
8. Miller A. Myiasis. In: *Diseases of Children in the Subtropics and Tropics*. 4th ed. London, England: ELBS with Edward Arnold London; 1991;957-59
9. Cook GC, Zumla A. Medical Acarology and Entomology. Manson's Tropical Disease, 21st edition, Saunders (ELST);2003;1727-32.
10. Hammack L. Oviposition by screw-worm flies (Diptera: Calliphoridae) on contact with host fluids. *J Econ Entomol*.1991;**84**:185-90. Wall R, Howard JJ, Bindu J (April 2001).
11. Wall. R, Howard JJ, Bindu J. The Seasonal Abundance of Blowflies Infesting Drying Fish in South-West India". *Journal of Applied Ecology* **38** (2): 339-48. DOI:10.1046/j.1365-2664.2001.00588.x. JSTOR 2655802.