

Endoscopic Push-Through Technique Myringoplasty in Tympanic Membrane Perforations; An Institutional Experience in Kathmandu, Nepal

Kundan Kumar Shrestha ¹, Anup Dhungana ¹, Anupama Shah Rijal ¹, Rupesh Raj Joshi ¹

¹Department of Otorhinolaryngology, Nepal Medical College and Teaching Hospital, Attarkhel, Jorpati, Kathmandu, Nepal.

ABSTRACT

Background

Push-through technique cartilage perichondrium composite graft myringoplasty involves placing the graft beneath the freshened perforation by endoscopic approach without elevating tympanomeatal flap. The aim of this study is to assess the graft uptake and hearing after push-through myringoplasty at our institution.

Methods

This prospective study was conducted in Otorhinolaryngology Department of Nepal Medical College Teaching Hospital from November 2022 to October 2023 after obtaining ethical clearance from Research and Ethical Sub Committee (RESC). All patients aged 20 years and above with inactive type of chronic otitis media mucosal disease with conductive hearing loss underwent myringoplasty by push-through technique using cartilage perichondrium composite graft. Pure tone audiograms of the patients were done before and after surgery. Graft uptake and hearing results were evaluated at 12 weeks using SPSS. Paired t test was used to assess hearing improvement.

Results

The success rate among the participants who underwent endoscopic push through myringoplasty regarding graft uptake was 84.8% (78 of 92). The mean preoperative bone conduction threshold was 13.6±4.1 dB as compared to 13.1±4.0 dB postoperatively. Similarly, the mean preoperative air conduction threshold was 45.2±7.3 dB, with the postoperative value being 30.9±7.6 dB. The mean preoperative air-bone gap was 30.6±7.5 dB, while the air-bone gap postoperatively was 17.8±6.7 dB. Paired t-test comparing the means of the preoperative to postoperative air-bone gap showed a significant difference post-surgery with a p value of less than 0.001.

Conclusions

Push through technique myringoplasty can be used to repair perforations with good results in terms of graft uptake and improved hearing.

Keywords: push-through technique; endoscopic; myringoplasty.

INTRODUCTION

Since 1950, microscopic myringoplasty, with 80-90% success rates, has been the gold standard treatment for tympanic membrane (TM) perforations.^{1,2} Postauricular approach is preferred for anterior/large perforations but may cause scarring, ear malposition, and temporary sensory loss.^{3,4} Endoscopy, introduced in 1978 by Eichner⁵ and used for middle ear surgery since 1990, provides better vision and avoids scarring but has drawback like loss of depth perception.^{6,7} Grafts

for myringoplasty can include temporalis fascia, tragal perichondrium, adipose tissue, synthetic materials, and tragal cartilage.⁸ Most conventional myringoplasty techniques involve raising the tympano-meatal flap, which may cause bleeding.⁹ As endoscopic push through technique avoids this, bleeding is less. Hence, its use has escalated since the 1990s.¹⁰⁻¹² There are limited studies in our region regarding the outcomes of this new technique. This study assesses graft uptake and hearing results after endoscopic push-through

Correspondence: Dr. Kundan Kumar Shrestha, Department of Otorhinolaryngology, Nepal Medical College and Teaching Hospital, Attarkhel, Jorpati, Kathmandu, Nepal. Email: kundanshrestha9@hotmail.com, Phone: +977-9860124543.

Article received: 2023-11-21. **Article accepted:** 2024-08-20.

myringoplasty in chronic otitis media mucosal inactive disease.

METHODS

This prospective study was conducted in Nepal Medical College Teaching Hospital, Otorhinolaryngology Department from November 2022 to October 2023. The IRC ethical clearance number (29-079/080) was obtained from the Research and Ethical Sub Committee (RESC) of Nepal Medical College Teaching Hospital. All patients aged 20 years and above diagnosed as chronic otitis media mucosal inactive disease with subtotal perforation with conductive hearing loss were included in the study. Sample size was calculated as follows:

Sample size:

z = reliability coefficient

= 1.96 at 95% confidence interval

p = the graft uptake rate after endoscopic push through myringoplasty = 93.75%¹³

q = (100- p) = 6.25%

d = absolute error = 6%

$$n = \frac{Z^2 P(1-P)}{d^2}$$

$$= \frac{(1.96)^2 (0.9375) (0.0625)}{(0.06)^2}$$

$$= 62.5 \text{ (approximately 63)}$$

Patients with diseases of the external ear, squamous type chronic otitis media, those with mixed and sensorineural hearing loss and those with congenital anomalies were excluded. A thorough history and detailed clinical examination including tuning fork tests, otoscopic examination under microscope (EUM) were done. Hearing status was evaluated by Pure Tone Audiometry. Pre-operatively and post-operatively pure tone audiograms of the patients were done to record the air conduction threshold (ACT), bone conduction threshold (BCT) and the air bone gap (ABG) at speech frequencies (500 Hz, 1 KHz, 2 KHz, and 4 KHz).

Written informed consent was obtained from all patients who agreed to undergo surgery. All surgeries were performed under local anaesthesia. Oral cefixime 200 milligrams 12 hourly was started on the day of surgery and was continued for a total of 7 days.

Patients were sedated by intramuscular injections of 50 milligrams of pethidine and 25 milligrams of phenergan, given about 30 to 45 minutes pre-operatively. Endoscopy of the operating ear was done to inspect the middle ear. Then infiltration of local anaesthesia consisting of 5-10 ml of 2% xylocaine combined with 1: 200,000 of adrenaline was given for four quadrants canal wall block just lateral to cartilaginous-bony junction and around the tragus. Freshening of the margins of TM was done using 0degree 4 mm Karl Storz endoscope by permeal approach. Cartilage graft was harvested from the tragus by making a small incision on the medial aspect of the tragus which was sutured later with 3-0 prolene. Perichondrium was removed from one side. The malleus handle was skeletonized. Haemostasis in the middle ear was achieved by using wet cotton balls soaked with adrenaline. Dry gelfoam pieces was placed in the middle ear. The cartilage graft was then pushed through the perforation in an underlay fashion which was strengthened further with a perichondrium cover. Finally, the external auditory canal was packed with gelfoam pieces soaked in ciprofloxacin ear drops to the level of the isthmus. A small dressing was applied to cover the auricle. Ear canal was packed using ribbon gauze impregnated antibiotic ointment (polymyxin B sulphate, neomycin and bacitracin zinc) and mastoid bandage was applied. Patients were discharged same day after the surgery with oral cefixime 200 milligrams 12 hourly for a total of 7 days. Follow up was done after 1 week and external auditory pack was removed. After removing the pack, patients were prescribed ciprofloxacin ear drops three times a day for 2 weeks. Next follow up was done at 12 weeks. Graft uptake and hearing results were evaluated at that time. Statistical analysis was done using SPSS version 16. Descriptive statistics was calculated such as frequency, mean and standard deviation. Paired t test was applied to look at the hearing improvement.

RESULTS

A total of 92 participants were included for the study. Graft uptake failed in 14 patients. Only the successful 78 cases were then taken for further statistical

analysis. The age of the participants ranged from 20 years to 58 years old, with the mean being 28.4 ± 8.4 years. There were 44 females (56.4%) and 34 males (43.6%). There was a female preponderance among the participants with the male to female ratio being 1:1.3. The success rate among the participants who underwent push through myringoplasty regarding graft uptake was 84.8% (Figure 1).

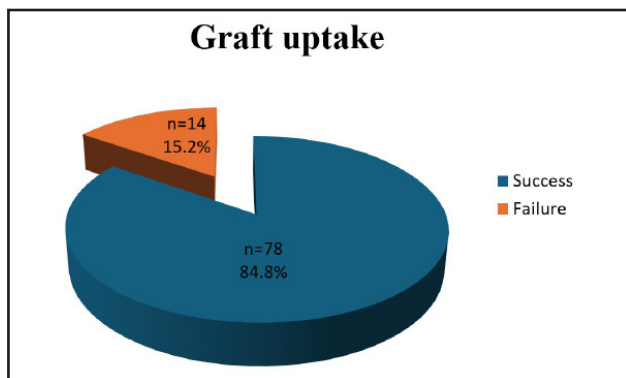


Figure 1. Graft uptake status.

The mean preoperative bone conduction threshold was 13.6 ± 4.1 dB as compared to 13.1 ± 4.0 dB postoperatively. Similarly, the mean preoperative air conduction threshold was 45.2 ± 7.3 dB, with the postoperative value being 30.9 ± 7.6 dB. The mean preoperative air-bone gap was 30.6 ± 7.5 dB, while the air-bone gap postoperatively was 17.8 ± 6.7 dB. Paired t-test comparing the means of the preoperative to postoperative air-bone gap showed a significant difference post-surgery with a p value of less than 0.001 (Table 1).

Hearing status	Pre-operative mean	Post-operative mean	p-value
ACT (dB)	45.2 ± 7.3	30.9 ± 7.6	<0.001
BCT (dB)	13.6 ± 4.1	13.1 ± 4.0	0.35
ABG (dB)	30.6 ± 7.5	17.8 ± 6.7	<0.001

Out of 78 successful cases, 25 (32.1%) had improved hearing by 1-10 dB, 49 (62.8%) had improvement by 10-20 dB and 4 (5.1%) had improvement in hearing by 21-30 dB (Figure 2).

DISCUSSION

Tympanic membrane perforations can be repaired by variety of techniques. Traditionally, a graft is placed by using a microscopic underlay technique underneath

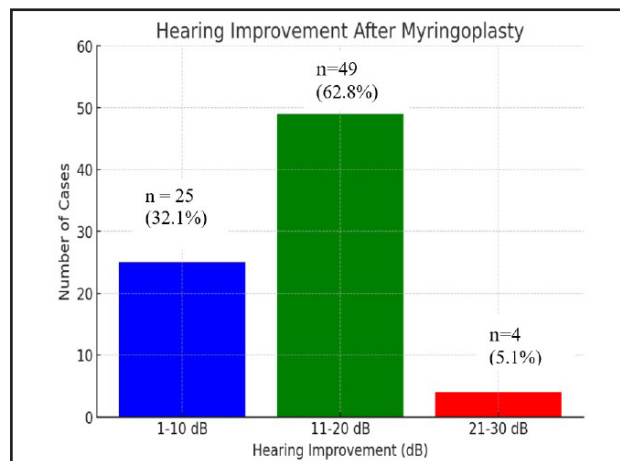


Figure 2. Improvement in hearing in dB among 78 successful myringoplasties.

a tympanomeatal flap which involves making skin incisions via an endaural or a post aurial approach. In the transcanal endoscopic push through technique of cartilage myringoplasty, the graft is placed directly through the freshened perforation. It neither needs skin incisions as in conventional methods nor does it require a preparation of a tympanomeatal flap. Thus it provides various advantages like no need for external skin incision except the incision performed for harvesting the cartilage graft, no need for elevation of tympanomeatal flap, short operative time, no need for a postoperative mastoid dressing, fast postoperative wound healing, patient comfort and good cosmetic results.¹³ Apart from these, as an endoscope can easily be transported, it can be conveniently used in temporary ear surgery locations that take place in far less prepared places where microscopes are not available and can't be transported. The cost efficiency of the endoscope can also prove to be a good substitute in the healthcare facilities which cannot afford a microscope. However, the endoscopic technique also has some disadvantages. Because it is a single handed technique, it requires a learning curve for the surgeon to become familiar with the instruments and the endoscope. Additionally, if external canal skin is injured, the patient will face significant bleeding. This will cause contamination of the lens and obscure the vision subsequently requiring frequent suctioning and hence increasing the duration of the procedure. One major drawback of endoscopic

myringoplasty is the difficulty to operate directly through the eyepiece of the endoscope leading to eye strain, neck and backache. Therefore, the endoscope is invariably used with the camera and monitor. This increases the weight of the endoscope, leading to arm fatigue as well.^{14, 15} Some authors have also raised the concern that heat from the endoscopic light source could damage the inner ear. However, no patients in our study complained about prolonged vertigo, dizziness, or nystagmus in the postoperative period. And we found only slight statistically insignificant postoperative bone conduction threshold reduction post-surgery; therefore, we consider the heat from the endoscopic light source didn't damage the inner ear in our study. In our study, we chose tragal cartilage-perichondrium as a grafting material. Cartilage is durable, strong against absorption, resists negative pressure (such as that produced by sniffing) and hence prevents resorption and retraction.² Tragal cartilage-perichondrium is particularly preferred because it is easy to harvest, prevents postoperative scarring and hence makes it a very good choice for all kind of tympanic membrane perforations including the revision cases. Cartilage as a graft material has been used in managing retraction pockets. It offers more mechanical stability and is better in cases of chronic tubal dysfunction, adhesive processes or total/ sub-total defects of the tympanic membrane. As cartilage is well tolerated by the middle ear, it survives for a long time. Cartilage is also supplied by diffusion and seems to offer high resistance to lack of vascularization and infections. Our study had a female preponderance which was also seen in other similar studies.^{14, 16, 17} This could be because of the growing awareness of females towards overall health and health related issues in recent times in our communities. Our study comprised mostly younger patients which is similar to other studies. The age range of the patients was also similar to ours with more patients in the younger age groups.^{13, 17} This could highlight the fact that younger age groups are more concerned about their problems and also more enthusiastic regarding the surgical treatment. The graft success rate in myringoplasty is varied and is

reported as 71%– 96% in the literature.¹³⁻²¹ In our study, the graft success rate obtained by endoscopic push-through technique cartilage myringoplasty was 84.8%, and it is comparable with the literature.¹³⁻²¹ Endoscopic push-through technique cartilage myringoplasty has anatomical and functional results comparable with the literature, and it is an effective, minimally invasive, and feasible method.¹⁶ Another measure of the success of the surgery was improved hearing. Out of 78 successful cases, 49 (62.8%) had improvement by 11-20 db. Other studies in the literature also have shown improvement in hearing after surgery.^{2, 10, 13, 14, 16, 17, 19, 21} In our study, graft uptake failed in 14 patients (15.2%). This could be because of infections, such as otitis media, recurrent upper respiratory tract infections like the common cold, postoperative non-compliance with care instructions, and patient-related factors including smoking, diabetes, or conditions that impair healing. The push through myringoplasty first described by El-Guindy was applied to the closure of the small TM perforations; subsequently, successful surgical and functional outcomes were reported in the treatment of medium and large-sized TM perforations using the push-through technique.^{10, 22-24} Our study also supports that. The comparable results for subtotal perforation in our study proves that the technique might be effective for all types of perforations. The best technique for myringoplasty is still under debate because of rapidly growing novel technology leading to paradigm shifts in minimally invasive surgery. The conventional microscope has been considered the ideal surgical tool to facilitate ear surgery. However, with the recent advances in technology, even in our part of the world, the endoscope can be considered a novel alternative surgical tool for ear surgery.

CONCLUSIONS

Endoscopic push through technique myringoplasty can be used to correct tympanic membrane perforations with good results in terms of graft uptake and improved hearing.

Conflict of interest: None

Funding: None

REFERENCES

1. Sarkar S. A review on the history of tympanoplasty. *Indian J Otolaryngol Head Neck Surg.* 2013;65(Suppl 3):455–60. [[Google Scholar](#)][[DOI](#)]
2. Dornhoffer JL. Hearing results with cartilage tympanoplasty. *Laryngoscope.* 1997;107(8):1094–9. [[Google Scholar](#)][[Link](#)]
3. Choi N, Noh Y, Park W, Lee JJ, Yook S, Choi JE, et al. Comparison of endoscopic tympanoplasty to microscopic tympanoplasty. *Clin Exp Otorhinolaryngol.* 2017;10: 44–9. [[Google Scholar](#)][[DOI](#)]
4. Kang HS, Ahn SK, Jeon SY, Hur DG, Kim JP, Park JJ, et al. Sensation recovery of auricle following chronic ear surgery by retroauricular incision. *Eur Arch Otorhinolaryngol.* 2012; 269 (1): 101–6. [[Google Scholar](#)][[DOI](#)]
5. Eichner H. A “mother-and baby scope-optic” for middle ear endoscopy. *Laryngol Rhinol Otol.* 1978; 57: 872-6. [[Google Scholar](#)]
6. Thomassin JM, Duchon-Doris JM, Emram B, Rud C, Conciatori J, Vilcoq P. Endoscopic ear surgery: initial evaluation. *Ann Otolaryngol Chir Cervicofac.* 1990; 107(8):564-70. [[Google Scholar](#)][[PubMed](#)]
7. Tarabichi M. Endoscopic middle ear surgery. *Ann Otol Rhinol Laryngol.* 1999;108 (1): 39–46. [[Google Scholar](#)] [[Link](#)]
8. Boedts D. Tympanic grafting materials. *Acta oto-rhino-laryngologica Belg.* 1995;49 (2):193-9. [[Google Scholar](#)]
9. Sergi B, Galli J, De Corso E, Parrilla C, Paludetti G. Overlay versus underlaymyringoplasty: report of outcomes considering closure of perforation and hearing function. *Acta Otorhinolaryngol Ital.* 2011; 31(6): 366–71. [[Google Scholar](#)]
10. El-Guindy A. Endoscopic transcanal myringoplasty. *J Laryngol Otol.* 1992;106(6):493-5. [[Google Scholar](#)][[DOI](#)]
11. Yadav SP, Aggarwal N, Julaha M, Goel A. Endoscope-assisted myringoplasty. *Singapore Med J.* 2009;50(5): 510-2. [[Google Scholar](#)]
12. Mohindra S, Panda NK. Ear surgery without microscope: is it possible. *Indian J Otolaryngol Head Neck Surg.* 2010; 62(2):138-41. [[Google Scholar](#)][[DOI](#)]
13. Ballal VC, Shivappa L, Tmmappaiah SB, Basavannaiah S, Rangaswamy CTV. Minimally invasive cartilage myringoplasty: our technique and experience. *Int J Otorhinolaryngol Head Neck Surg.* 2019;5: 866-70. [[Google Scholar](#)][[DOI](#)]
14. Gharib FM, Naseer UA, Elessi AMJ. Endoscopic permeal “push-through” myringoplasty: hearing gain and graft uptake. *Egypt J Otolaryngol.* 2022; 38: 121. [[Google Scholar](#)][[DOI](#)]
15. El-Hennawi DEM, Ahmed MR, Abou-Halawa AS, Al-Hamtary MA. Endoscopic push-through technique compared to microscopic underlay myringoplasty in anterior tympanic membrane perforations. *J Laryngol Otol.* 2018;132 (6):509-13. [[Google Scholar](#)][[DOI](#)]
16. Celik H, Samim E, Oztuna D. Endoscopic "Push-Trough" Technique Cartilage Myringoplasty in Anterior Tympanic Membrane Perforations. *Clin Exp Otorhinolaryngol.* 2015;8(3):224-9. [[Google Scholar](#)][[DOI](#)]
17. Erden B, Gülşen S. Evaluation of Surgical and Audiological Outcomes of Push-Through Myringoplasty and Underlay Cartilage Tympanoplasty in Repairing Anterior Tympanic Membrane Perforations. *J Craniofac Surg.* 2020;31(6):1709-12. [[Google Scholar](#)][[DOI](#)]
18. Mahawerawat K., Kasemsiri P. Comparison of the clinical outcome of endoscopic push-through myringoplasty and microscopic overlay myringoplasty: matching co-variated designs. *BMC Surg.* 2022; 22: 44. [[Google Scholar](#)] [[Link](#)]
19. Gu F. Endoscopic transtympanic cartilage push-through myringoplasty without tympanomeatal flap elevation for tympanic membrane perforation. *Acta Otolaryngol.* 2021;141(9):831-4. [[Google Scholar](#)][[DOI](#)]

20. Couloigner V, Baculard F, El Bakkouri W, Viala P, Francois M, Narcy P, et al. Inlay butterfly cartilage tympanoplasty in children. *OtolNeurotol*. 2005;26(2):247-51. [[Google Scholar](#)][[DOI](#)]
21. Ayache S. Cartilaginous myringoplasty: the endoscopic transcanal procedure. *Eur Arch Otorhinolaryngol*. 2013;270(3):853-60. [[Google Scholar](#)][[DOI](#)]
22. Eren SB, Tugrul S, Ozucer B, Veyseller B, Aksoy F, Ozturan O. Endoscopic transcanal inlay myringoplasty: alternative approach for anterior perforations. *Otolaryngol Head Neck Surg*. 2015;153:891-3. [[Google Scholar](#)][[DOI](#)]
23. Kaya I, Benzer M, Uslu M, Bilgen C, Kirazli T. Butterfly cartilage tympanoplasty longterm results: excellent treatment method in small and medium sized perforations. *Clin Exp Otorhinolaryngol*. 2018;11(1):23-9. [[Google Scholar](#)][[DOI](#)]
24. Alain H, Esmat NH, Ohad H, Yona V, Nageris BI. Butterfly myringoplasty for total, subtotal, and annular perforations. *Laryngoscope*. 2016;126(11):2565-8. [[Google Scholar](#)][[DOI](#)]

Citation: Shrestha KK, Dhungana A, Rijal AS, Joshi RR. Endoscopic Push-Through Technique Myringoplasty in Tympanic Membrane Perforations; An Institutional Experience in Kathmandu, Nepal. *JCMS Nepal*. 2024; 20(3): 268-73.