

# Functional And Radiological Outcome of Schatzker Type V and VI Tibial Plateau Fracture Treated with Closed Reduction and Ilizarov Fixation with or without Minimally Invasive Screw Supplementation

Suresh Pandey,<sup>1</sup> Suraj Bidary<sup>1</sup>

<sup>1</sup>Department of Orthopedics, College of Medical Sciences, Bharatpur, Nepal.

## ABSTRACT

### Introduction

Controversy exists as to the best treatment approach for high-velocity tibial plateau fractures. This study was done to assess the functional and radiological outcome of Schatzker type V and VI tibial plateau fractures treated with closed reduction and Ilizarov ring fixation with or without cancellous screw supplementation.

### Methods

An analytical cross sectional study was conducted among 25 cases of both closed and open Schatzker type V and VI tibial plateau fractures treated with closed reduction and Ilizarov ring fixation with or without minimally invasive cannulated cancellous screw supplementation. The outcome variables analyzed were union time, knee range of motion, American Knee Society Score (AKSS), Rasmussen's Radiological Score (RRS), and complications. Data analysis was done using SPSS-20. P-value <0.05 was considered as statistically significant.

### Results

There were 15 type V fractures, 10 type VI fractures, 21 closed fractures, and 4 open fractures. All the fractures united with a mean union time of 15.88 weeks (range 12-24). The mean American Knee Society score was 77.8 (range 68-95), Rasmussen's radiological Score (RRS) 15.12 (range 10-18), and mean range of motion was 112.40° (range 90-135). Superficial pin site infection was present in 7 (28%) of the cases. There was no case of nonunion, deep infection, repeat surgery other than implant removal, or nerve palsy.

### Conclusions

Closed reduction and Ilizarov ring fixation with or without minimally invasive screw supplementation give rise to good to excellent functional and radiological outcomes in most of the cases in the treatment of Schatzker type V and VI tibial plateau fractures with minimal bone or soft tissue related complications.

**Keywords:** tibial plateau fracture; schatzkar type; ilizarov fixation.

**Correspondence:** Dr. Suresh Pandey, Department of Orthopaedics College of Medical Sciences, Bharatpur, Chitwan, Nepal.  
Email: drsuresh.orthonepal@gmail.com. Phone: +977-9845047228.

## INTRODUCTION

High energy tibial plateau fracture in young adults is on the rise due to an increased number of high-velocity injuries.<sup>1</sup> It results in bicondylar fracture with or without diaphyseal extension (Schatzker type V and VI respectively). Treatment of such complex fractures aims to achieve anatomical reduction, stable fixation, restoration of joint motion, preservation of secondary osteoarthritis, and addressing meniscal and ligament injury.<sup>2</sup>

There are an array of options to manage such fractures in the practice starting from plaster treatment to operative fixation with plate and Ilizarov.<sup>3,4</sup> There is a varying degree of associated soft tissue injury in such fractures giving rise to increased incidence of soft tissue and fracture-related complications in plaster method of treatment. Open reduction and internal fixation (ORIF) with dual plating or one side plate and one side screws can be a good option when soft tissue condition permits. But, there is a high rate of wound dehiscence and infection in dual plating.<sup>5-7</sup> Closed reduction and stabilization with Ilizarov fixation has the advantage of preservation of soft tissue and vascularity, avoidance of soft tissue-related complications, yet providing satisfactory results in most cases.<sup>8</sup>

There is still debate about the best method of treatment for such complex fractures. So, this study was carried out to assess the functional and radiological outcome of complex tibial plateau fracture (both closed and open Schatzker type V and VI) with closed reduction and Ilizarov ring fixation with or without minimally invasive screw supplementation as a primary objective. The secondary objectives were to assess the rate of complications and comparison of outcome with closed and open fractures and type V and type VI fractures. Our hypothesis was this method of treatment for complex tibial plateau

fracture gives satisfactory outcomes in most cases.

## METHODS

An analytical cross sectional study was conducted among 25 patients of Schatzker type V and VI tibial plateau fracture treated with closed reduction and Ilizarov fixation with or without minimally invasive screw supplementation. All the operations were performed by a single surgeon in the tertiary care teaching hospital from Sept. 15 2019 to Sept 15, 2021. Ethical clearance was taken from the institutional review committee of College of Medical Sciences and Teaching Hospital.

Inclusion criteria were all the closed or open tibial plateau (Schatzker type V and VI) fractures operated with closed reduction and Ilizarov fixation technique from the age group 16 to 60 years. Exclusion criteria were patients with age <16 years or >60 years, associated ipsilateral lower limb other bone fracture, pathological fracture, and patients operated elsewhere. Consent was taken from the patient for the use of data in research with the condition of anonymity.

Basic demographic and clinical data of each patient were collected from the inpatient chart and follow-up data, union status, complications, and functional and radiological outcomes were taken from the OPD record and examination of the patient in the OPD.

### Operative Details:

All the operations were performed under either spinal or general anesthesia in a supine position on the operating table without the use of a tourniquet. Preoperative prophylactic antibiotics were given 30 minutes before incision. Prepping and draping were done following standard protocol. Closed reduction was done under C-arm control with traction coupled with counter traction. The centrally

depressed fracture was elevated with the insertion of a percutaneous impactor to restore the articular congruity. The reduction was held with 1 or 2 percutaneous 6.5 mm cannulated cancellous screw (CCS) distal to the joint level in patients where fractures were markedly depressed or comminuted. Then, premeasured and prepared 3-ring Ilizarov ring assembly was inserted and Ilizarov wires 1.8 mm olived in the proximal fragment were inserted parallel to the joint 15 mm distal to the joint level to avoid intracapsular position. Two Ilizarov wires were transfixed distal to the fracture and two in distal metaphysis of the tibia. Wire tensioning was done, clamp tightened and 4 threaded rods were used to join the adjacent rings to each other. In a few cases, the Schanz pin was added in proximal and/or distal fragments to add stability; a decision solely based on the operating surgeon intraoperatively. The proximal-most ring was 5/8 if the patient was obese with bulky thigh and leg. None of the cases was managed with a knee-spanning ring fixator. Reduction and fixation were checked in the C-arm. Corticocancellous block of bone graft was impacted in cases with marked central depression.

In open fracture of the tibial plateau, meticulous wound debridement was done and definitive Ilizarov fixation was done. If the patient had exposed bone or tendon, a medial gastrocnemius muscle pedicle flap was done to reconstruct the soft-tissue defect either in the same seating if time permitted or within 1 week of Ilizarov fixation. Cases with acute compartment syndrome (ACS) with tibial plateau were managed with decompression with double incision fasciotomy and unilateral temporary external fixator during index surgery. It was converted to definitive Ilizarov fixation and closure of the wound with or without split skin graft within 5-7 days.

Pin site cleaning with betadine and spirit was done twice a day and taught to the patient as

well during the postoperative phase. Quadriceps strengthening exercise and Range of motion (ROM) were started the next day onward. Toe touch crutch walking was started the next day till 6 weeks. Then, partial weight-bearing from 6-12 weeks and then full weight-bearing crutch walking were advised. Follow-up in OPD was advised 2 weekly till 3 months then 6 weekly.

The implant was removed once there was evidence of union clinicoradiologically. The radiological union was decided by the presence of bridging callus/bone in three cortex out of 4. Clinically, painless full weight-bearing and absence of deformation at the fracture site after dynamization were indicators of united fracture. Dynamization of the two adjacent rings proximal and distal to the fracture was done 2 weeks before implant removal when radiological evidence of union was present. The slab was applied for 2 weeks after the removal of the Ilizarov fixator. Final functional scoring was done using the American Knee Society score (AKSS) and Rasmussen's Radiological Score (RRS) at final follow-up or at least 6 months after the fixation of the fracture. AKSS consists of physician-evaluated scores based on pain (maximum 50 points), knee stability (maximum 25 points), and ROM (maximum 25 points), all adding up to 100 points with appropriate deductions for flexion contracture, extensor lag, and malalignment. Based on this score, the result is rated as excellent (85), good (75-84), fair (60-74), and poor (<60).<sup>9</sup>

Rasmussen's radiological scoring (RRS) system consists of an assessment of articular depression, intercondylar widening, and meta-diaphyseal angulation, each having a maximum score of 6 and a minimum of 0, making it a total of 18. Excellent is 18, good is 12-17, fair is 6-11, and poor is <6 score.<sup>1</sup> The details of Rasmussen's radiological scoring system has been given below.

Parameters	Points
<b>A. Articular depression</b>	
Not present	6
<5 mm	4
6-10 mm	2
>10 mm	0
<b>B. Condylar widening</b>	
Not present	6
<5 mm	4
6-10 mm	2
>10 mm	0
<b>C. Angulation (varus/valgus)</b>	
Not present	6
<10°	4
10°-20°	2
>20°	0

**Data analysis and statistics:** Collected data was check for completeness and then data analysis was done by IBM SPSS software version 20.0. Data was analyzed using descriptive and inferential statistical tools. In the descriptive statistics categorical variables were expressed interm of frequency and percentage while continuous variables were expressed interm of mean and standard deviation. In the inferential statistics AKSS score and RSS were compared with fracture type (SchatzkerV and VI and closed and open fracture) using an independent t-test or Man Whitney test (for nonparametric data). P-value <0.05 was considered as statistically significant.

## RESULTS

There were a total of 25 cases of type V and type VI tibial plateau fracture with a mean age of 34.48 years (range 18-55, standard deviation 9.87) treated with closed reduction and Ilizarov fixation. The study population had male

dominance (84%, n=21) over female (16%, n=4). Right side involvement was in 15 cases (60%) and left in 10 (40%). Further demographic data, injury characteristics, and treatment details have been summarized in table 1.

**Table 1.** Showing demographics, injury characteristics, and treatment summary.

Variables	Number (%)
<b>Mode of injury</b>	
RTA	23 (92)
Fall injury	2 (8)
<b>Schatzker fracture Types</b>	
Type V	15 (60)
Type VI	10 (40)
<b>Closed fracture</b>	
Open Fracture	21 (84)
Open Fracture	4 (16)
ACS	2 (8)
Preop CT scan done	15(60)
Initial External fixator	5 (20)
5/8 ring	6 (24)
Full ring	19 (76)
Percutaneous CC screw	9 (36)
GM flap used	4 (16)
No flap	21 (84)

ACS = Acute compartment syndrome, CC=Cannulated cancellous, GM= Gastrocnemius muscle

The mean injury treatment duration was 3.8 days (range 2-7). Mean follow-up duration and length of stay were 11.56 months (range 7-18) and 9.8 days (range 7-14) respectively. The mean union time for all type V and type VI fractures was 15.88 weeks (range 12-24 weeks). The mean union time for type V fracture was 14.33 weeks (SD±1.98) compared to 18.20 (SD±3.04) weeks for type VI fracture. The difference was statistically significant (p=0.01). The mean time of ring removal after the operation was 17.20 weeks (range 14-26).

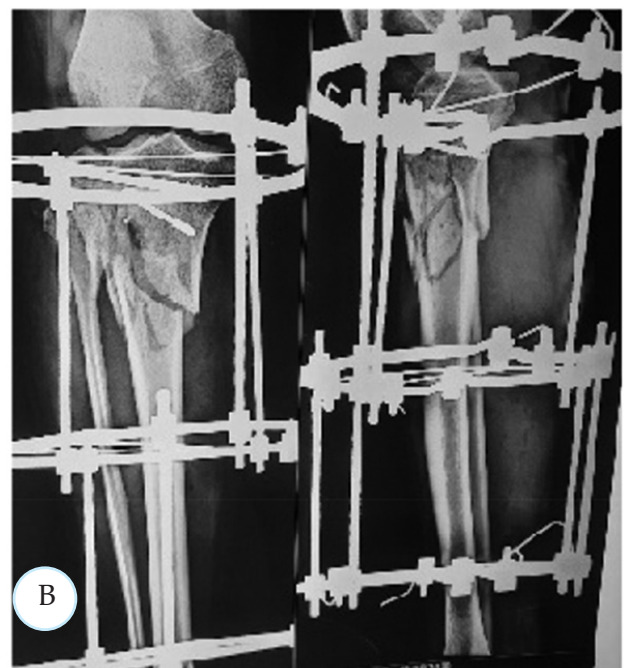
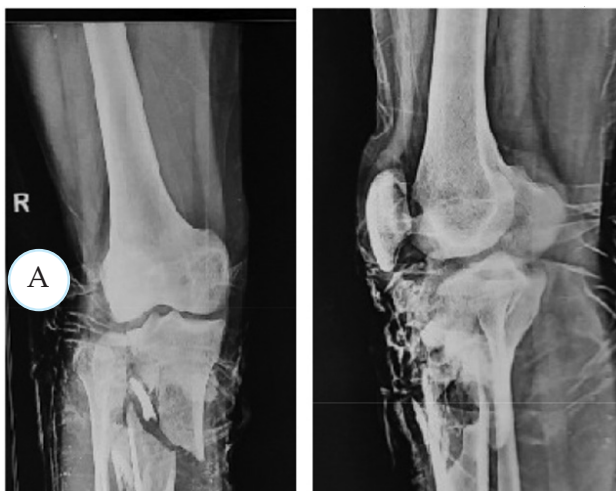The mean range of motion at the knee was 112.4° (range 90-135). Mean American Knee Society Scoring (AKSS) and Rasmussen’s Radiological Scoring (RRS) were 77.8 (range 68-95) and 15.12 (range 10-18) respectively. AKSS grading analysis showed excellent results in 9 cases (36%) good in 7 cases (28%) and fair in 9 cases (36%) whereas RRS grading showed excellent results in 10 cases (40%), good in 12 cases (48%) and fair in 3 cases (12%).

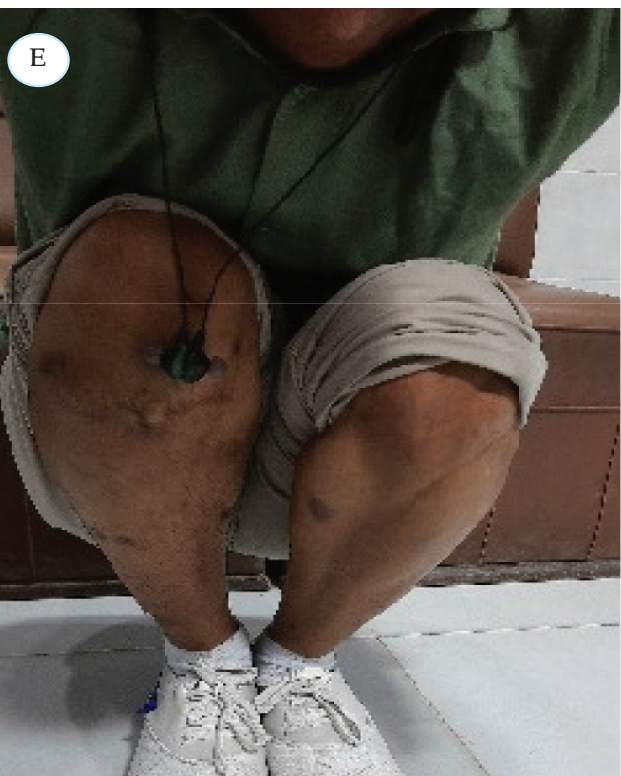
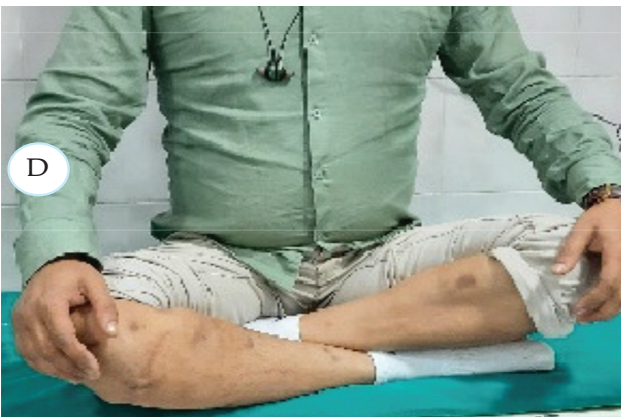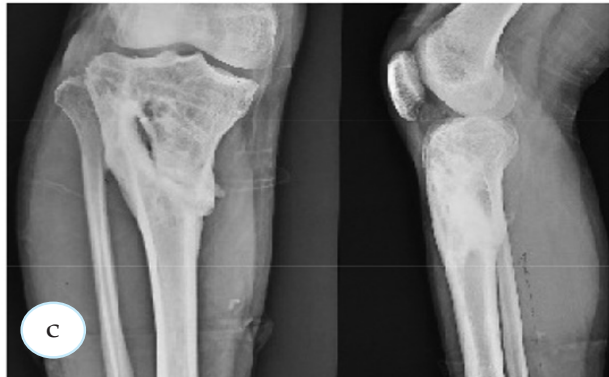On comparison of ROM, AKSS, and RRS between type V and type VI fractures, there was significant difference in ROM and RRS instead of and rest of the outcomes were comparable. There was no significant difference in the ROM, AKSS, RRS between closed and open fractures. A comparison of the result according to type V and type VI and closed and open fractures have been presented in table 2.

**Table 2.** shows a comparison of ROM, AKSS, and RRS between type V and type VI fractures and closed and open fractures.

Variables	ROM	p-value	AKSS	p-value	RRS	p- value
	(Mean ±SD)		(Mean ±SD)		(Mean±SD)	
Schatzker V	116.3±7.89	0.01	79.73±7.83	0.13	16.53±2.06	0.001
VI	106.5±10.55		74.9±7.26		13±2.70	
Closed fracture	112±9.17	0.47	77.91±8.04	0.9	15.36±2.85	0.26
Open fracture	110±13.57		77±7.55		13.33±3.05	

There were 7 cases (28%) of pin site infection. All were superficial and improved with regular dressing and oral antibiotics. No case of pin site infection needed surgery. There was no case of osteomyelitis, repeat surgery due to infection or flap necrosis, hematoma, seroma, and postoperative nerve palsy.





**Figure 1.** Shows open type VI tibial plateau fracture A, postoperative X-ray showing Ilizarov fixation with cannulated cancellous screw (CCS) supplementation B, X-ray after implant removal showing union C and ROM at knee D, E.

## DISCUSSION

The current study showed good to excellent AKSS results in 2/3<sup>rd</sup> of the cases and good to excellent RRS grading in 3/4<sup>th</sup> of the cases of Schatzker type V and VI tibial plateau fracture treated with closed reduction and Ilizarov ring fixation with or without percutaneous screw supplementation. All the fractures united with the restoration of a good range of motion.

The challenge to treating high-velocity tibial plateau fracture is mainly due to the nature of extensive soft tissue injury, difficulty in the restoration of the articular surface, and normal range of motion.<sup>10</sup> The incidence of type V and VI tibial plateau fracture is on the rise due to high-velocity road traffic accidents.<sup>10</sup> The problem is compounded by associated marked soft tissue injury around the knee or even open fracture. Open reduction and internal fixation with dual plate is a popular option in the practice to achieve good reduction and fixation. But, it is associated with a high rate of wound-related complications, infection, stiffness, and secondary loss of reduction.<sup>3,4</sup> Use of Ilizarov ring fixation has the advantage of early fixation with closed reduction, preservation of further soft tissue damage, and early range of motion so that soft tissue-related issues are less frequent and achieving good ROM is relatively easy.<sup>11</sup>

There is a high predilection of such injury in male and younger populations as evidenced in the different studies and this applies to this study also.<sup>12</sup> (This is probably so because of the increased mobility of the young adult men in outdoor activities and the high-velocity driving of the motorbikes. Road traffic accident (RTA) is the commonest mode of injury in this study which is true in most of the other studies as well.<sup>4,10,13</sup>

There were 21 cases of a closed fracture, 4 open

fracture, and 2 acute compartment syndrome (ACS) in the current study. ACS underwent emergency dual incision fasciotomy followed by definitive fixation and closure of the wound within 1 week. There was no major complication. Our study involved the use of no knee spanning ring fixators. The reasons behind so are to reduce the chance of knee stiffness, start early ROM, and reduction was thought to be stable with below-knee rings only. There are studies done by Subramanyam et al<sup>10</sup> where knee spanning ring fixators were used and found no difference in the result between the knee spanning and below knee Ilizarov ring construct.

There were 6 cases with 5/8 proximalmost ring used as per surgeon's choice in obese patients and heavy-built ladies in our study, thinking that ROM would be better. Union time, knee score, and complications were not different from the cases with the full ring.

The mean union time of 15.88 weeks for all type V and VI fractures in the present study was comparable to the findings of the other studies.<sup>8,12,14</sup> On comparing mean union time between type V and VI fractures, type VI fractures had longer union time which can be explained because of higher severity of the injury and diaphyseal extension of the fracture.

Raza A et al<sup>12</sup> in their study of 26 patients with type V and VI fracture treated with closed reduction and Ilizarov fixation showed a mean union time of 12 weeks, mean ROM 120°, and satisfactory results in 22 cases. Katsenis D et al<sup>14</sup> had shown a mean union time of 13 weeks and excellent to a good result in 81% of the cases in a total of 48 cases of high-velocity tibial plateau fracture treated with ring fixator. There was no difference in the outcome between knee spanning and below knee ring fixator.

Catagni et al<sup>15</sup> had shown good to excellent results in almost 95% of his total of 59 patients

with type V and type VI tibial plateau fracture treated with Ilizarov fixation with or without minimally invasive percutaneous screw fixation. He used a knee spanning ring fixator in grossly comminuted and unstable intraarticular fracture. There were 4 cases of peroneal nerve palsy and 4 cases of pin site infection.

Ferreira et al<sup>16</sup> in their study of 54 patients with Bicondylar fracture treated with closed reduction and Ilizarov fixation with percutaneous screw supplementation showed good results in all the cases without soft tissue or bony complication. The mean knee society clinical score was 81.1.

ORIF with dual plating is alternative approach to treat bicondylar fracture especially when soft tissue condition permits. But it can be associated with a higher rate of wound dehiscence and infection. Barei et al<sup>17</sup> in their study of bicondylar fracture in 83 patients treated with ORIF with dual plating showed 8.4% deep infection requiring repeat operation, 5 patients required manipulation of the knee for stiffness, 2 heterotrophic ossification, 1 nonunion, and 16 cases of deep vein thrombosis. Though none of them developed a pulmonary complication.

Unno et al<sup>18</sup> in their study of a total of 102 cases of type V and type VI fracture tibial plateau treated with ORIF with dual plating, found a reoperation rate of 12.7% excluding cases with implant removal.

One meta-analysis done by Li Z et al<sup>13</sup> comparing results of Ilizarov fixation with ORIF with plating, had shown no difference between the union time, ROM, and functional and radiological outcome. But, the ring fixator has the advantage of early ROM, weight-bearing, and early restoration to work.

There was no significant difference in the union time, AKSS score, and RRS between closed and open fractures in our study but there was a significant difference in the ROM and RRS

between type V and type VI fractures (Table2). This signifies the importance of dealing with higher velocity injury and relatively poor outcomes in the higher grade tibial plateau fracture.

The rate of pin site infection was 28% in the current study which was comparable to the findings of Ali et al<sup>19</sup>, Raza A et al<sup>12</sup>, and Raj M et al<sup>20</sup>. But none needed repeat surgical intervention and all healed well with proper pin site care, dressing, and a short course of oral antibiotics. Ilizarov's method of stabilization in the treatment of tibial plateau fracture has got the disadvantage of a relatively higher rate of pin site infection but most of them resolve with proper dressing and antibiotics.

There were no complications in terms of peroneal nerve palsy, repeat operation due to pin site infection, osteomyelitis or septic

arthritis, heterotrophic ossification, and deep vein thrombosis in the present study.

Limitations of the current study are the retrospective nature of the study, relatively less number of cases with shorter duration of follow-up, single-center, and single surgeon study, and lack of comparison group. We did not take into account ligamentous and meniscal injuries.

## CONCLUSIONS

Treatment of high-velocity tibial plateau fractures (Schatzker type V and VI) with closed reduction and Ilizarov ring fixation with or without percutaneous screws give good to excellent functional and radiological outcomes in most of the cases with minimal bone or soft tissue-related complications.

**Conflicts of interest:** All the authors have nothing to declare.

## REFERENCES

- Ozturkmen Y, Caniklioglu M, Karamehmetoglu M, et al. Calcium phosphate cement augmentation in the treatment of depressed tibial plateau fractures with open reduction and internal fixation. *Acta Orthop Traumatol Turc.* 2010;44:262e269. <https://doi.org/10.3944/AOTT.2010.2406>.
- Raza A, Kumar S, Kumar D, Qadir A, Muzzammil M, Lakho MT. Complex Tibial Plateau Fractures: Primary Fixation Using the Ilizarov External Fixator. A Two-year Study at Civil Hospital Karachi, Pakistan. *Cureus.* 2019;11(8):e5375. Published 2019 Aug 13. doi:10.7759/cureus.5375.
- DeCoster TA, Nepola JV, el-Khoury GY. Cast brace treatment of proximal tibia fractures. A ten-year follow-up study. *Clin Orthop Relat Res.* 1988 Jun;(231):196-204. PMID: 3370874.
- Young MJ, Barrack RL. Complications of internal fixation of tibial plateau fractures. *Orthop Rev.* 1994 Feb;23(2):149-54. PMID: 8196973.
- Papagelopoulos PJ, Partsinevelos AA, Themistocleous GS, Mavrogenis AF, Korres DS, Soucacos PN. Complications after tibia plateau fracture surgery. *Injury.* 2006 Jun;37(6):475-84. doi: 10.1016/j.injury.2005.06.035. Epub 2005 Aug 22. PMID: 16118010.
- Khatri K, Sharma V, Goyal D, Farooque K. Complications in the management of closed high-energy proximal tibial



- plateau fractures. *Chin J Traumatol.* 2016 Dec 1;19(6):342-347. doi: 10.1016/j.cjtee.2016.08.002. PMID: 28088939; PMCID: PMC5198935.
7. Ruffolo MR, Gettys FK, Montijo HE, Seymour RB, Karunakar MA. Complications of high-energy bicondylar tibial plateau fractures treated with dual plating through 2 incisions. *J Orthop Trauma.* 2015; 29(2): 85-90. doi: 10.1097/BOT.000000000000203.
  8. Kawoosa AA, Mantoo SA, Ali N, Dar GN. Clinico - Radiological Results of Tibial Bicondylar Fractures Managed with Ilizarov Technique with or without Minimal Internal Fixation. *Malays Orthop J.* 2022 Mar;16(1):18-27. doi: 10.5704/MOJ.2203.004. PMID: 35519521; PMCID: PMC9017920.
  9. Insall JN, Dorr LD, Scott RD, Scott WN. Rationale of the Knee Society clinical rating system. *Clin Orthop Relat Res.* 1989 Nov;(248):13-4. PMID: 2805470.
  10. Subramanyam KN, Tammanaiah M, Mundargi AV, Bhoskar RN, Reddy PS. Outcome of complex tibial plateau fractures with Ilizarov external fixation with or without minimal internal fixation. *Chin J Traumatol.* 2019 Jun;22(3):166-171. doi: 10.1016/j.cjtee.2018.11.003. Epub 2019 Apr 13. PMID: 31072699; PMCID: PMC6543267.
  11. Hall JA, Beuerlein MJ, McKee MD; Canadian Orthopaedic Trauma Society. Open reduction and internal fixation compared with circular fixator application for bicondylar tibial plateau fractures. Surgical technique. *J Bone Joint Surg Am.* 2009 Mar 1;91 Suppl 2 Pt 1:74-88. doi: 10.2106/JBJS.G.01165. PMID: 19255201.
  12. Raza A, Kumar S, Kumar D, Qadir A, Muzzammil M, Lakho MT. Complex Tibial Plateau Fractures: Primary Fixation Using the Ilizarov External Fixator. A Two-year Study at Civil Hospital Karachi, Pakistan. *Cureus.* 2019 Aug 13;11(8):e5375. doi: 10.7759/cureus.5375. PMID: 31616608; PMCID: PMC6786835.
  13. Li Z, Wang P, Li L, Li C, Lu H, Ou C. Comparison between open reduction with internal fixation to circular external fixation for tibial plateau fractures: A systematic review and meta-analysis. *PLoS One.* 2020 Sep 17;15(9):e0232911. doi: 10.1371/journal.pone.0232911. PMID: 32941429; PMCID: PMC7498044.
  14. Katsenis D, Athanasiou V, Megas P, Tyllianakis M, Lambiris E. Minimal internal fixation augmented by small wire transfixion frames for high-energy tibial plateau fractures. *J Orthop Trauma.* 2005 Apr;19(4):241-8. doi: 10.1097/01.bot.0000155309.27757.4c. Erratum in: *J Orthop Trauma.* 2006 Jan;20(1):69. Vasilis, Athanasiou [corrected to Athanasiou, Vasilis]; Panayiotis, Megas [corrected to Megas, Panayiotis]; Minos, Tillianakis [corrected to Tyllianakis, Minos]. PMID: 15795572.
  15. Catagni MA, Ottaviani G, Maggioni M. Treatment strategies for complex fractures of the tibial plateau with external circular fixation and limited internal fixation. *J Trauma.* 2007 Nov;63(5):1043-53. doi: 10.1097/TA.0b013e3181238d88. PMID: 17993949.

16. Ferreira N, Marais LC. Bicondylar tibial plateau fractures treated with fine-wire circular external fixation. *Strategies Trauma Limb Reconstr.* 2014 Apr;9(1):25-32. doi: 10.1007/s11751-014-0185-z. Epub 2014 Feb 9. PMID: 24510395; PMCID: PMC3951617.
17. Barei DP, Nork SE, Mills WJ, Henley MB, Benirschke SK. Complications associated with internal fixation of high-energy bicondylar tibial plateau fractures utilizing a two-incision technique. *J Orthop Trauma.* 2004 Nov-Dec;18(10):649-57. doi: 10.1097/00005131-200411000-00001. PMID: 15507817.
18. Unno F, Lefaivre KA, Osterhoff G, et al. Is early definitive fixation of bicondylar tibial plateau fractures safe? An observational cohort study. *J Orthop Trauma.* 2017;31:151e157. <https://doi.org/10.1097/BOT.0000000000000779>.
19. Ali AM. Outcomes of open bicondylar tibial plateau fractures treated with Ilizarov external fixator with or without minimal internal fixation. *Eur J Orthop Surg Traumatol.* 2013 Apr;23(3):349-55. doi: 10.1007/s00590-012-0989-9. Epub 2012 Apr 10. PMID: 23412295.
20. Raj M, Gill S, Rajput A, Singh KS, Verma KS. Outcome Analysis of Dual Plating in Management of Unstable Bicondylar Tibial Plateau Fracture - A Prospective Study. *Malays Orthop J.* 2021 Nov;15(3):29-35. doi: 10.5704/MOJ.2111.005. PMID: 34966492; PMCID: PMC8667239..

**Citation:** Pandey S, Bidary S. Functional And Radiological Outcome of Schatzker Type V and Vi Tibial Plateau Fracture Treated with Closed Reduction and Ilizarov Fixation with or without Minimally Invasive Screw Supplementation. *JCMS Nepal.* 2022; 18(3); 244-53.