

Prospective Comparative Study of Above Elbow Cast for Six Weeks Versus Above Elbow Converted to Below Elbow Cast After Three Weeks for Pediatrics Distal Forearm Fracture

Saugat KC,¹ Hemant Kumar Gupta,² Raj Kumar Hamal²

¹Department of Orthopedics, Chitwan Medical College Teaching Hospital, Bharatpur, Chitwan, Nepal, ²Department of Orthopedics, College of Medical Sciences, Bharatpur, Chitwan, Nepal.

ABSTRACT

Introduction

Forearm fractures are common injuries and the approach to manage these in children is different than similar injuries in adults. Various methods of cast immobilization are done for the treatment of distal forearm fractures in children. The purpose of this study was to determine if above elbow cast (AEC) converted to below elbow cast (BEC) in three weeks are as effective as above elbow cast (AEC) in the treatment of the distal forearm fracture. Therefore, this study was conducted with the objective of evaluating and comparing the outcome of above elbow cast (AEC) with above elbow converted to below elbow cast (BEC) after three weeks for management of pediatrics distal forearm fracture.

Methods

This study was conducted in Department of Orthopedic Surgery in College of Medical Sciences-TH Bharatpur, Nepal from February 2016 to January 2017. Among sixty cases thirty were selected in AEC group and thirty in above elbow converted to below elbow cast group (AEC/BEC) by simple random sampling. All patients were followed up six months.

Results

Out of sixty patients in two groups, fifty-three made to all follow up. Twenty-eight of cases were AEC group and twenty-five were AEC/BEC group. All the cases had union at six weeks and twelve weeks follow up. There was statistically significant difference in limitation in pronation/supination.

Conclusions

AEC converted to BEC for six weeks is effective as AEC for six weeks in the treatment of distal third forearm fracture in children. AEC/BEC group patients have lesser degree of loss of supination/pronation movement.

Keywords: distal forearm; fractures; pediatrics.

Correspondence: Dr. Saugat KC, Department of Orthopedics, Chitwan Medical College, Bharatpur, Chitwan, Nepal.
Email: saugatkc916@gmail.com, Phone: +977-9842173919.

INTRODUCTION

Forearm fractures are common injuries in childhood and approach to manage these in children differs from adults.¹ Approximately 75–84% of forearm fractures occur in distal third, 15–18% in the middle third, and 1–7% in the proximal third forearm.² There have been few studies comparing the outcome of AEC with AEC for three weeks followed by BEC for three weeks. Current practice in our institute is to apply AEC for 6 weeks. We want to conduct this study in our setup which could change our treatment modality and patient acceptability. Therefore, this study was conducted to evaluate and compare the outcome of AEC with AEC converted to BEC after three weeks for management of pediatrics distal forearm fracture. Our objective is to compare supination/pronation, flexion/extension of elbow, clinical and radiological union, cast comfort, activities of daily living and complication in both groups.

METHODS

A hospital based, interventional, prospective study was conducted in College of Medical Sciences-Teaching Hospital Bharatpur, Nepal from February 2016 to January 2017. All patients with complete distal one-third radius or both radius and ulna without physeal injuries from age group 4 to 14 years and who have given consent for procedure were included in the study whereas patients with physeal injury, torus, incomplete and open fracture, fracture sustained longer than one week, patients who have previous operation of forearm or wrist and poly trauma were excluded from the study. Permission to carry out this study was obtained from College of Medical Sciences - Institutional Review Committee.

Sample size was calculated using the formula,

$$\text{Patients per group} = \frac{f(\alpha, \beta) \times 2 \times SD^2}{(d)^2}$$

Where,

$f(\alpha, \beta)$ = 90% power with 5% significance

Significance (risk of type I error) is set at 5% i.e.

p value set at 0.05

Standard deviation = 1.99³

Difference in mean (d) = 1.91

Therefore,

$$n = \frac{10.5 \times 2 \times 1.96^2}{1.91^2} = 22.84 \approx 23$$

Taking 25% Non-response rate, final sample size was calculated to be 30 per group i.e. 60 in total with 30 in group A (AEC) and 30 in group B (AEC to BEC). Informed consent was obtained for participation from all the parents of the children aged 4 to 14 years. All the patients were assessed prior to cast treatment. Patients were randomly assigned to the two groups. The fractures were manipulated and reduced under appropriate analgesia and sedation. Patients were assessed immediately after cast treatment and check radiographs were done. All cases were counseled regarding precaution and complication like excessive pain, swelling and bluish discoloration of digits, numbness and paralysis and recommended for overnight observation. Those noncompliant cases were sent home with medication; strict hand elevation and other advices and followed up next day in OPD. All cases were carefully assessed on the next day for swelling of fingers, hand, and distal neurovascular status. Radiographs were analyzed for displacement; angulations and overriding at the time of presentation, after reduction, and subsequent follow up intervals. Loss of reduction and criteria for re-manipulation was defined as an increase of 10% angulations and 20% of displacement compared with the post reduction values. Fracture union is defined clinically as the presence of bridging callus at three out of four cortices in anterior posterior and lateral radiographs and clinically the presence of transmitted movement across the fracture site in follow up. Plaster of Paris was used as the cast material in our study. For AEC, we first applied the below-elbow component, mold it, and then extended it to above the elbow.

Later AEC was converted to BEC after three weeks in those children who were kept in below elbow conversion group. The primary outcome measure was the limitation of pronation and supination at 12 weeks after the fracture. The secondary outcome measures were cast comfort, limitation of flexion and extension of elbow, clinical and radiological union, radiological parameters for re displacement, activities of living and complication. Loss of reduction was defined as an increase of $>10^\circ$ of angulation or deviation and $>20\%$ displacement compared with the post reduction values. Loss of pronation and supination movement was graded as per Daruwalla Grading System (Beaty)⁴

Table 1. Grading of limitation of pronation/supination (Daruwalla).

Grade	Loss of pronation/supination in percentage (%)
Excellent	0-10
Good	20-Nov
Fair	21-30
Poor	>30

RESULTS

A total of 60 children eligible to participate in the study were included in the study and kept into two groups (30 each). At final follow up 53 cases were available for analysis. The age group of the study participants ranged from 4 years to 14 years old. The mean age of the participants was found to be 8.62 years. Out of the total participants, 37(69.8%) were males and 16(30.2%) were females. Among the study participants, 46(86.8%) were right hand dominant and remaining 7(13.2%) were left hand dominant. However, right handed injury was found among 47.2% and left handed injury was found among 52.8%. Of the total study participants, 32(60.4%) had only radius fracture while 21(39.6%) had both radius and ulna fracture. Out of the total cases, 86.8% were manipulated under regional anesthesia while 13.2% were manipulated under general anesthesia. Out of total reduction

attempted 88.7% were successful to achieve acceptable reduction. Remaining 11.3% of the cases were re-manipulated once again. Regarding radiological union (callus) at three weeks, among the total cases callus was seen in 7(13.2%) and callus was not seen in 46(86.8%). In AEC group callus was seen in 1 and in AEC/BEC group callus was seen in 6 cases. This was statistically significant with p value of 0.028 (via chi square test).

For cast comfort, mean VAS score were 5.07 and 6.24 in AEC and AEC/BEC group respectively.

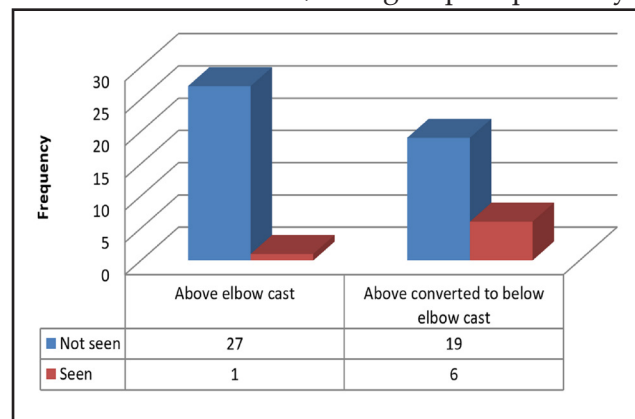


Figure 1. Radiological union at three weeks of both AEC and AEC/BEC groups.

Independent sample t test was done and cast comfort was found to be statistically significant in two groups (p: 0.001). All the cases have clinical and radiological union at six weeks follow up. Mean loss of flexion in AEC group was 13.10 degrees (S.D: 5.50). Mean loss of flexion in AEC/BEC group is 10.24 degrees (S.D: 5.41). There was no statistically significant relation in two groups (p: 0.062). For limitation of supination / pronation, since the data distribution of loss of pronation/supination was skewed log transformation of the data was done and independent sample t-test was carried out. There was statistically significant difference between 2 groups (p value: 0.009). Mean loss of pronation/supination was 22.32 degrees (S.D: 7.13) in AEC group and 17.24 degrees (S.D: 6.45) in AEC/BEC group. There was no statistically difference in the number of days of school missed mean loss of days is 20.21 (S.D: 6.34) in AEC and days 19.96 (S.D: 4.47)

Table 2. Daruwalla classification among participants of AEC group.

Grade	Frequency (%)
Excellent	3 (10.7)
Good	10 (35.7)
Fair	14 (50.0)
Poor	1 (3.6)
Total	28 (100.0)

Table 3. Daruwalla classification among participants of AEC/BEC group.

Grade	Frequency (%)
Excellent	4 (16.0)
Good	14 (56.0)
Fair	7 (28.0)
Poor	0 (0.0)
Total	25 (100.0)

in AEC/BEC group (p value: 0.865), there was no significant difference with regards to help in dressing (p value: 0.78), shower (p value: 0.80), need help in school (p value:0.823), need help to write (p value: 0.707), eat (p value: 0.239) and in toilet (p value: 0.260) among two groups.

Table 4. Complication among AEC and AEC/BEC group.

Complication	AEC	AEC/BEC	p value
Loss of reduction	6	0	-
Mal union	3	4	0.694
Re fracture	0	0	NA
Tight cast	2	1	0.597
Non union	0	0	NA
Elbow Excoriation	2	1	0.621

NA: Not Applicable

There was no significant difference in the complications in the two groups. There was no loss of reduction noted after conversion to below elbow cast. All loss of reduction occurred within three weeks of cast application so association of two groups was not established. No children presented in follow up with re fracture. Children complaining of tight cast had their cast

removed and cast reapplied at a later time. Mal union, which was measured as the deviation from acceptable criteria of reduction used in the study, was also not statistically significant. They were treated with appropriate physical therapy and counseled properly. The functional outcome observed was less severe as compared to the radiological observation. No non-union was encountered in this study.

DISCUSSION

There were no significant differences between the two groups with respect to age (p value: 0.493), sex (p value: 0.550), fracture limb (p value: 0.785), mode of injury (p value: 0.084), anesthesia used (p value: 0.426). In the previous study by Colaris et al.⁵ despite randomization there was a substantial difference in age at the time of fracture and fracture limb and hence the statistical analyses were corrected for these baselines variables. Boys were affected more than girls in both groups. The most common mode of injury was fall on ground. All these findings are consistent with literature by Johari et al.⁶. There was significant difference in the two groups in limitation of pronation/supination (p value: 0.009). Using Daruwalla grading system for limitation of pronation and supination, excellent result was seen in 10.7 %, good in 35.7%, fair in 50.0% and poor in 3.6% in the AEC group while in the AEC/BEC group excellent result was seen in 16%, good in 56%, fair in 28% and poor result in 0% of cases. In the previous study by Friberg et al.⁷ the results in the AEC-alone group were excellent in 21%, good in 38%, fair in 26%, and poor in 15%. In the group treated with AEC and BEC, the results were excellent in 33%, good in 37%, fair in 27%, and poor in 3%. In the previous study by Colaris et al.⁵ limitation of pronation and supination of ≥ 30 degrees at final follow-up were seen in 15 of 127 children, eight of whom also suffered a radiographic mal union. Six children with a radiographic mal union at final follow-up showed no

limitation of pronation and supination. Similarly, seven cases suffered radiological mal union in 53 patients at 12 weeks follow up in this study but 5 cases showed limitation of pronation and supination at normal mean loss range and did not hamper his/her daily activities at final follow up. There was no significant difference in limitation of elbow flexion in 2 groups with mean limitation of flexion being 13.10 degrees (S.D: 5.50) in AEC and 10.24 degrees (S.D: 5.41) in AEC/BEC group (p value: 0.062). In the study by Colaris et al.⁵ the limitation of flexion and extension of the elbow was 1.2 (4.4) degrees in AEC and 0.5 (1.9) degrees in AEC/BEC group. The cause of limitation in our study could be the fact our assessment was done at three months while in the previous study final assessment was done at six months. The range of loss of reduction is 7% – 27% in various studies⁸⁻¹⁰, in our study it was found to be 11.3 % (6/53). The total loss of reduction in our study was 11.3% (6/53). All the cases belong to AEC group and occurred in the first week. This is mere coincidental finding and could not compare within group because we apply above elbow cast for both groups in initial three weeks. The authors have suggested this high rate in their study to be due to strict mal union criteria, the prospective follow-up with scheduled radiographs and the type of cast used (non-circumferential cast applied directly after reduction followed by circumferential cast one week later). The other reason could be that they had applied all the cast in neutral position for all level of fractures without consideration for the deforming forces. There was no statistically difference in the number of days of school missed mean loss of days is 20.21 (S.D: 6.34) in AEC and days 19.96 (S.D: 4.47) in

AEC/BEC group. (p value: 0.865), help in dressing (p value: 0.78), shower (p value:0.80), need help in school (p value:0.823), need help to write (p value: 0.707), eat (p value:0.239) and in toilet (p value: 0.260) among two groups. The findings are similar with the previous study.⁵ In another study by Jupiter et al.¹¹ below elbow cast group needed less help in dressing than in above elbow cast group. There is no statistically significant difference in complications i.e. mal union (p value: 0.694), tight cast (p value: 0.597) and elbow excoriation (p value: 0.621). The previous study⁵ showed no statistical significance in complications as well. There were few limitations in this study. All reduction was not done by a single surgeon. Similarly larger sample size could have been covered for better generalization of result.

CONCLUSIONS

Above elbow cast for three weeks followed by below elbow cast for three weeks is as effective as above elbow cast for six weeks in the treatment of distal third forearm fracture in children with significant difference seen in loss of supination/pronation movement whereas no significant difference in other movements, union, complications, and activities of living. AEC/BEC group patients have lesser degree of loss of supination/pronation movement.

ACKNOWLEDGEMENT

We would like to thank Dr Sagun Dongol, Dr Gyanendra K Jha, Dr Anil Raj Regmi and Residents and OPD staffs of College of Medical Sciences Teaching Hospital for their support. We would also like to acknowledge all the patients and their parents who participated in the study.

REFERENCES

1. Noonan KJ, Price CT. Forearm and Distal Radius Fractures in Children. *J Am Acad Orthop Surg.* 1998;6(3):146–56.[Pubmed |

DOI]

2. Armstrong PF, Joughlin VE, Clarke HM, Willis RB. Pediatric fractures of the forearm, wrist, and hand. In: *Skeletal Trauma in*

- Children Philadelphia: WB Saunders. 1998. p. 161–257.
3. Paneru SR, Rijal R, Shrestha BP, Khanal GP, Karn NK, Singh MP, et al. Randomized controlled trial comparing above- and below-elbow plaster casts for distal forearm fractures in children. 2010;4:233–7. [Pubmed | DOI]
 4. Beaty JH, Kasser JR. Rockwood and Wilkins' fractures in children. *J Bone Jt Surgery-british* Vol. 2010;92(10):1480.
 5. Colaris JW, Allema JH, Biter LU, Reijman M, Ven CP Van De, Vries MR De, et al. Conversion to below-elbow cast after 3 weeks is safe for diaphyseal both-bone forearm fractures in children A multicenter randomized controlled trial involving 127 children. *Inj Br J Accid Surg*. 2013;84(5):489–94. [Full text | DOI]
 6. Johari AN, Orth D, Sinha M. Remodeling of forearm fractures in children. *J Pediatr Orthop B*. 1999;8(2):84–7. [Pubmed]
 7. Friberg KSI. Remodelling after distal forearm fractures in children II: the final orientation of the distal and proximal epiphyseal plates of the radius. *Acta Orthop Scand*. 1979;50(6):731–9. [Full text | DOI]
 8. Voto SJ, Weiner DS, Leighley B. Redisplacement after closed reduction of forearm fractures in children. *J Pediatr Orthop*. 1990;10(1):79–84. [Full text]
 9. Monga P, Raghupathy A, Courtman NH. Factors affecting remanipulation in paediatric forearm fractures. *J Pediatr Orthop B*. 2010;19(2):181–7. [Pubmed | DOI]
 10. Chan CF, Meads BM, Nicol RO. Remanipulation of forearm fractures in children. *N Z Med J*. 1997;110(1047):249–50. [Pubmed]
 11. Colaris JW, Allema JH, Biter LU, de Vries MR, van de Ven CP, Bloem RM, et al. Redisplacement of stable distal both-bone forearm fractures in children: a randomised controlled multicentre trial. *Inj Br J Accid Surg*. 2013;44(4):498–503. [Full text | DOI]

Citation: KC S, Gupta HK, Hamal R K. Prospective Comparative Study of Above Elbow Cast for Six Weeks Versus Above Elbow Converted to Below Elbow Cast After Three Weeks for Pediatrics Distal Forearm Fracture. *JCMS Nepal*. 2023; 19(4): 447-52