

Amoxicillin Induced Behavioral Neurotoxicity and Histopathological Changes in Organs of Albino Rats

Sabita Paudel,¹ Bijay Aryal,² Sunita Ranabhat³

¹Department of Pharmacology, Gandaki Medical College, Pokhara, Nepal, ²Department of Pharmacology Karnali Academy of Health Sciences, Jumla, Nepal, ³Department of Pathology Gandaki Medical College, Pokhara, Nepal.

ABSTRACT

Background: There are various adverse drug reactions of penicillin. Neurotoxicity is attracting the attention of researchers all over the world. It also affects other organs like liver, kidney, heart and testes.

Methods: The study was conducted at pharmacy and pharmacology department of Gandaki Medical College (GMC) from January till April, 2018. Albino rats were divided six each in test and control group. Tests were administered amoxicillin 90mg/kg/d and control with distilled water for 10 days. After 10 days, rats were tested for neurotoxicity with Rota-rod (RR) and modified forced swim test (MFST). They were then sacrificed under anesthesia, organs were dissected and sent for histopathological investigation.

Results: The latency to fall from RR apparatus decreased (150.9s) in test rats than control (8.2). In MFST, immobility time was increased than control. Swimming time (ST) was decreased and climbing time (CT) was not significantly altered in test rats than control. Brain of test rats (TR) showed shrunken neurons surrounded by perineuronal vacuolations, liver and kidney showed degenerative changes. Vacuolations and pyknotic cells were seen in spermatogenic cells.

Conclusions: Neurotoxic effects were seen in TR which recommends regulation of the administration of high dose of penicillin.

Keywords: Amoxicillin; histopathology; Modified Forced Swim Test; Rotarod test.

INTRODUCTION

Antibiotics are lifesaving drugs in infections. They are categorized broadly into cell wall inhibitors, protein synthesis inhibitors and enzyme inhibitors. Amoxicillin belongs to cell wall inhibitors group of antibiotics. It is one of the widely prescribed antibiotics. It has adverse effects like diarrhea, hepatotoxicity and hypersensitivity. Along with these, recent findings have presented various effects in brain, heart, kidney and testes.¹⁻³ Neurotoxic effects like depression, confusion, disorientation, somnolence, twitching, myoclonus, generalized tonic clonic seizures, status epilepticus were evidenced in different studies.⁴⁻⁸ The first three are well known adverse events whereas neurotoxicity is the recent finding.⁹⁻¹¹

Histopathologically, brain cells show pyknotic nuclei with perineuronal vacuolations, hepatocytes depict hemorrhages and renal tubules show degeneration. In the testes, there is the reduction in spermatogenesis. On administration of the drug for 10 to 14 days in high dose, these adverse effects are more prominent.¹² This study evaluates the neurotoxic adverse effects of amoxicillin like epilepsy and depression in albino rats. The

histopathological changes in the organs after the administration of the drug were studied.

METHODS

This study was conducted at the pharmacy, pharmacology and pathology department of GMC in the period of four months from January till April, 2018. Six test and six control albino rats of 200 to 220gm weight were the subjects of study. They were purchased from Department of Plant Resources, Kathmandu, Nepal. They were kept under 12h day and 12h night cycle. Temperature was (25 ± 3) °C with relative humidity of 50% ± 15%. Amoxicillin was administered at the dose of 90mg/kg/d. It was administered once daily through oral gavage at 10 am for 10 days. Food and water were provided ad libitum.

Rotarod test was done to observe the neuromuscular control. This apparatus was manufactured by Indosati, Scientific Lab Equipment. Laboratory animals, like rat grasp the rod firmly with their paws. As rod rotates, latency to fall from rotating rod was noted. Revolutions were set at 5rev/m.¹³

Correspondence: Dr. Sabita Paudel, Department of Pharmacology, Gandaki Medical College, Pokhara, Nepal. **Email:** drsabita@pauddel@gmail.com. **Phone:** +977-9846521128. **Article received:** 2019-08-18. **Article accepted:** 2020-02-16.

MFST apparatus was purchased from Indosati, Scientific Lab Equipments. This test was first described by Porsolt. It was conducted to observe depression in laboratory animals like rat, mice. It consisted of plexiglass measuring 50 cm in height and a diameter of 20 cm. Water at room temperature is kept till 45mm depth. Pre-training trial was conducted for 24 hours before test trial. Rat was allowed to swim for five minutes each in both trials. Climbing, swimming and immobility times were noted in a five minutes' time. Climbing means state where quick movements of the forelimbs are observed such that the front paws break the surface of the water.

Swimming means if movement of forelimbs or hind limbs in a paddling fashion is observed. Immobility means the floating with the absence of any movement except for those necessary for keeping the nose above water.¹⁴ After 24 hours of last administration of AMX, training sessions were conducted for RR and MFST. Then, rats were sacrificed under diazepam and ketamine anesthesia. Dissection was done with universal precautions. Samples of brain, two kidneys, two testes and all lobes of liver were collected and kept in phosphate buffer to transport to histopathology lab. The samples were then fixed with 10% formalin solution. They were cut into 4–5 µm thick sections and slides prepared with hematoxylin and eosin stain. Microscopic studies were done under high power field.

RESULTS

The test rats suffered from chronic diarrhea after 2nd day of administration of medication till sacrifice. The latency to fall from RR apparatus decreased significantly in test rats than control. In MFST, immobility time was significantly increased than control. Swimming time was decreased significantly and CT was not significantly altered in test rats than control (Table 1).

Table 1. Neuromuscular parameters of control and test rats.

Variable	Study group	Mean (seconds)	SD	df	P value
Fall time	Control	150.84	8.01	10	0.0001*
	Test	8.17	2.56		
Swimming test	Control	180	8.36	10	0.0001*
	Test	81.67	9.31		
Climbing test	Control	70	9.48	10	0.352
	Test	64.17	11.1		
Immobility time	Control	40	4.47	10	0.0001*
	Test	155.67	5.16		

The liver function test showed significant elevation of liver enzymes, AST and ALT. Urea and creatinine were higher in test rats than the control but there was no statistically significant increment

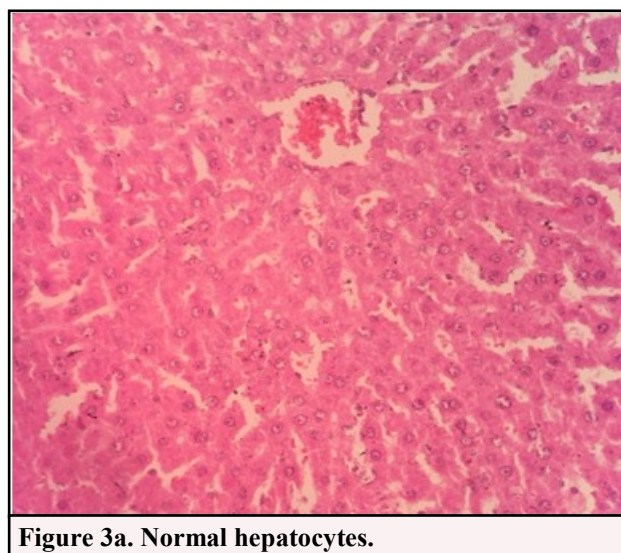
(Table 2).

Table 2. Laboratory parameters of the control and test rats.

Variable	Study group	Mean value (U)	SD	df	P value
AST	Control	186.17	15.5	10	0.049*
	Test	207.5	17.5		
ALT	Control	63	6.81	10	0.001*
	Test	103.27	5.14		
Urea	Control	32	4.69	10	0.092
	Test	37	4.6		
Creatinine	Control	0.58	0.07	10	0.072
	Test	0.76	0.21		

Histopathological changes

Histopathological investigation of liver of control rats showed normal picture. Test rats showed degenerated hepatocytes and extravasation of RBC. Brain of CR showed cortical arrangement of neurons and that of TR showed shrunken neurons surrounded by perineuronal vacuolations. Testes of CRs pictured normal spermatocytes and spermatogenesis. TRs were having mild degenerative changes in the spermatogenic cells. There were vacuolations and pyknotic cells. The glomerulus, urinary space, Bowman's capsule, proximal and distal convoluted tubules were normal in histopathology of control rats. In test rats, there were severe degenerative changes in glomerulus and widening of urinary space with hemorrhage between tubules. The histopathological changes are shown in pictures from Figure no. 3 to 6. The figures 3a, 4a, 5a and 6a are from the control rats and those of 3b, 4b, 5b and 6b are from the test rats.



DISCUSSION

Amoxicillin brought several changes in various organs of albino rats in our study. This suggested the careful usage of the antibiotic and the monitoring of dosage and limitation of prescription

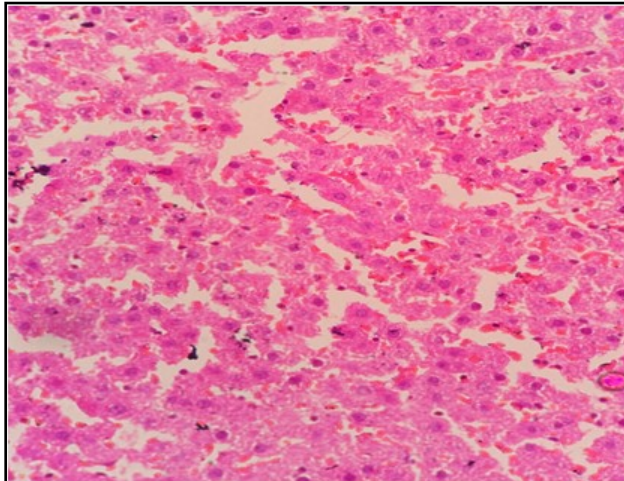


Figure 3b. Degenerated hepatocytes with extravasation of RBCs.

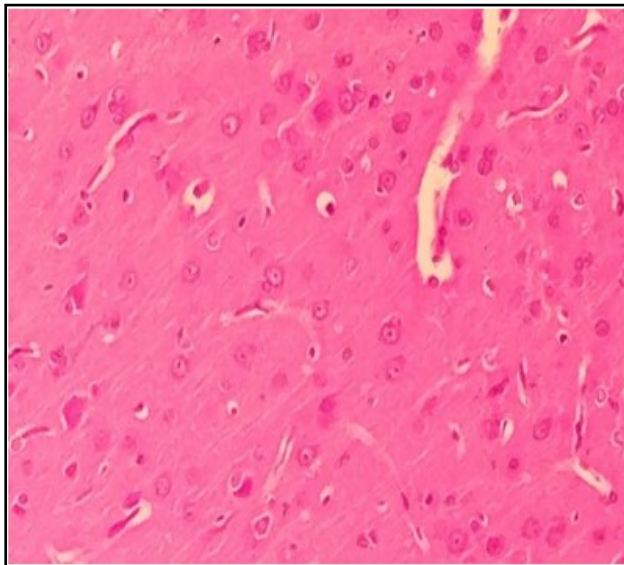


Figure 4a. Normal neurons and nuclei.

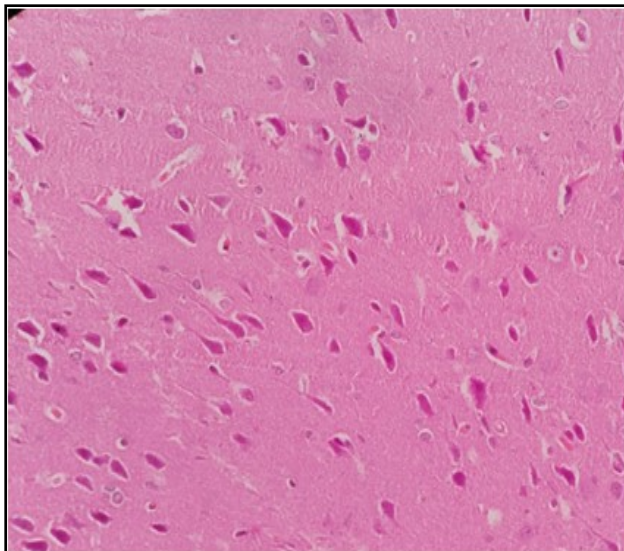


Figure 4b. Shrunken nuclei and perineuronal vacuolation.

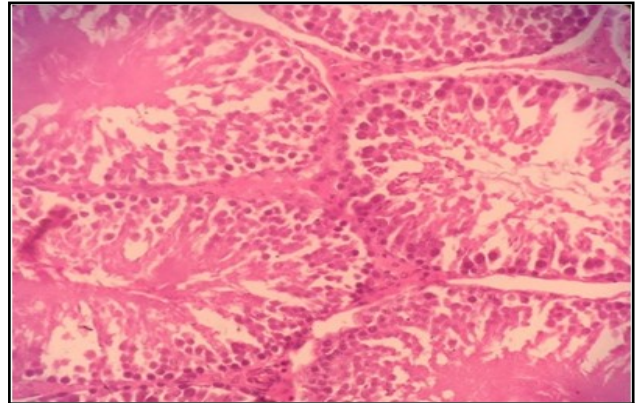


Figure 5a. Normal spermatogenic cells.

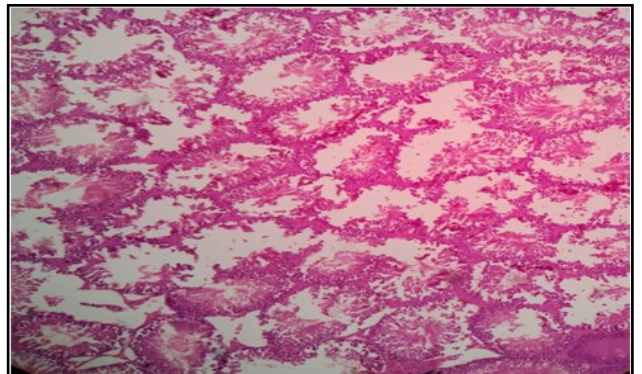


Figure 5b. Mild degenerative changes in the spermatogenic cells, vacuolation and pyknotic cells.

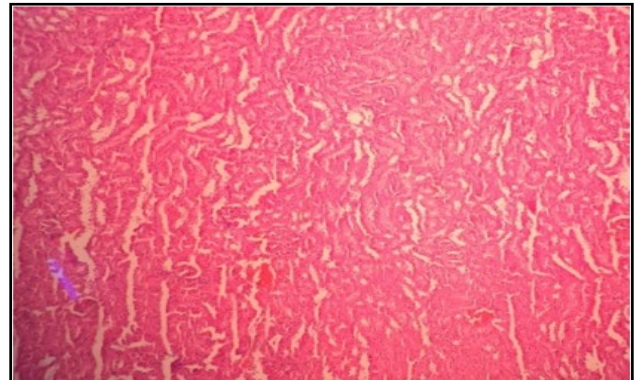


Figure 6a. Normal tubules with urinary space.

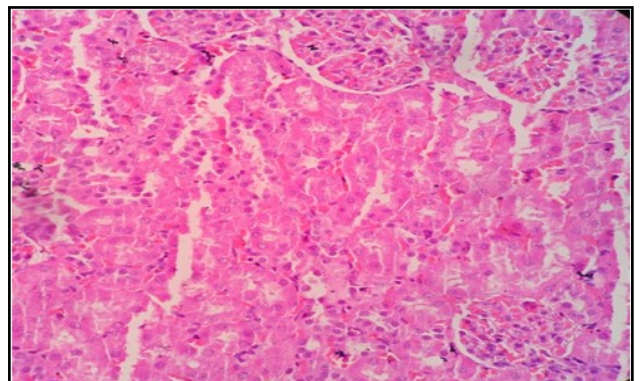


Figure 6b. Degenerative changes in glomerulus and widening of urinary space with hemorrhage between tubules.

for long duration. Diarrhea is one of the adverse effects of amoxicillin. It is due to suppression of normal flora of gut.¹ Rotarod test was discovered to check motor coordination in laboratory animals.¹³ The falling time from RR apparatus was decreased in test rats due to motor incoordination in test rats. In epileptic rats, motor coordination was weak. This decreased grasp of rats to rod and decreased fall time. In our study, falling off time was decreased in test rats than control similar to other studies.¹²

The β -lactam ring structure shares structural similarities with GABA. AMX interferes with GABA action and reduces GABA mediated inhibition of inward chloride current. This results in enhanced excitatory neurotransmission which predisposes to epileptiform discharges.^{10,15} Epileptogenic properties of AMX was first described by Johnson and Walker in 1945 AD.¹⁶⁻²⁰

Increase in IT and decrease in ST indicated depressive behavior in test rats. Depressive rats had decreased fear of drowning. So, they didn't swim and remained immobile in water for longer time. CT was not significantly altered in both groups. Finding of study done by Atli et al.²¹ suggested that serotonin level was decreased in AMX treated rats.

Serotonergic system was responsible for swimming behavior. Whereas, climbing time was same as dopamine and noradrenaline level wasn't significantly altered.

Liver enzymes were increased due to pathologic changes in liver.²² TRs showed degenerated hepatocytes due to drug injury. Drug induced liver injury is one of the major problems with antibiotics.²³ AMX forms hepatocellular lesions. These lesions progresses to cirrhosis in its severe form.²⁴ There was extravasation of RBCs. The brain showed shrunken neurons surrounded by perineuronal vacuolations. Testes were having mild degenerative changes in the spermatogenic cells. There were vacuolations and pyknotic cells. There were severe degenerative changes in glomerulus and widening of urinary space with hemorrhage between tubules. These findings were similar to finding obtained by Fahmy et al. in Egypt.¹¹

CONCLUSIONS

Amoxicillin had shown neurotoxic effects like convulsion and depression in albino rats. The effects in testes as well as other organs were also seen. Therefore, it needs special precautions when prescribing.

REFERENCES

- Brinton L, Chabner B, Knollman B. Goodman and Gilman's The Pharmacological Basis of Therapeutics. 12th ed. New York: Mc Graw-Hill Education; 2011.
- Katzing BG, Trevor AJ. Basic and Clinical Pharmacology. 13th ed. New York: McGraw-Hill Education; 2015.
- Tripathi KD. Essentials of Medical Pharmacology. 8th ed. New Delhi: Jaypee Brothers; 2018.
- Smith H, Lerner PI, Weinstein L. Neurotoxicity and "massive" intravenous therapy with penicillin: a study of possible predisposing factors. *Arch Intern Med.* 1967;120:47-53. <https://doi.org/10.1001/archinte.120.1.47>
- Lerner PI, Smith H, Weinstein L. Penicillin neurotoxicity. *Ann N Y Acad Sci.* 1967;145:310-8. <https://doi.org/10.1111/j.1749-6632.1967.tb50228.x>
- Schliamsner SE, Cars O, Norrby SR. Neurotoxicity of beta-lactam antibiotics: predisposing factors and pathogenesis. *J Antimicrob Chemother.* 1991;27:405-25. <https://doi.org/10.1093/jac/27.4.405>
- Anonymous. Penicillin, ceftazidime, and the epilepsies. *Lancet.* 1992;340:400-1. [https://doi.org/10.1016/0140-6736\(92\)91476-O](https://doi.org/10.1016/0140-6736(92)91476-O)
- Mattappalil A, Mergenhagen KA. Neurotoxicity with Antimicrobials in the Elderly : A Review. *Clinical Therapeutics.* 2014;36(11):1489-511. <https://doi.org/10.1016/j.clinthera.2014.09.020>
- Chow KM, Hui AC, Szeto CC. Neurotoxicity induced by beta-lactam antibiotics: from bench to bedside. *Eur J Clin Microbiol Infect Dis.* 2005;24:649-53. <https://doi.org/10.1007/s10096-005-0021-y>
- Bhattacharyya S, Darby R, Berkowitz AL. Antibiotic-Induced Neurotoxicity. *Curr Infect Dis Rep.* 2014;16:448. <https://doi.org/10.1007/s11908-014-0448-3>
- Grill MF, Maganti RK. Neurotoxic effects associated with antibiotic use: management considerations. *Br J Clin Pharmacol.* 2011;72(3):381-93. <https://doi.org/10.1111/j.1365-2125.2011.03991.x>
- Fahmy MA, Farghaly AA, Omara EA, Hassan ZM, Aly FAE, Donya SM, et al. Amoxicillin-clavulanic acid induced sperm abnormalities and histopathological changes in mice. *Asian Pac J Trop Biomed.* 2017;7(9):809-16. <https://doi.org/10.1016/j.apjtb.2017.08.002>
- K Pritchett, GB Mulder. The Rotarod. *Journal of the American Association for Laboratory Animal Science.* 2003;42(6):49
- Yankelevitch-Yahav, R., Franko, M., Huly, A., Doron, R. The Forced Swim Test as a Model of Depressive-like Behavior. *J Vis Exp.* 2015; (97):1-7 e52587. <https://doi.org/10.3791/52587>
- DeLorey TM, Olsen RW. γ -aminobutyric acidA receptor structure and function. *J Biol Chem.* 1992;267:16747-50.
- Walker AE, Johnson HC, Kollros JJ. Penicillin convulsions: the convulsive effects of penicillin

- applied to the cerebral cortex of monkey and man. *Surg Gynecol Obstet.* 1945;81:692–701.
17. Johnson HC, Walker AE. Intraventricular penicillin. *JAMA.* 1945;27:217–9. <https://doi.org/10.1001/jama.1945.92860040001007>
18. Walker AE, Johnson HC. Convulsive factor in commercial penicillin. *Arch Surg.* 1945;50:69–73. <https://doi.org/10.1001/archsurg.1945.01230030074003>
19. Niedermeyer EA, Walker E. Neurosurgeon, neuroscientist, and epileptologist. *Epilepsia.* 1995;36:516-21. <https://doi.org/10.1111/j.1528-1157.1995.tb00495.x>
20. Sarro AD, Ammendola D, Zappala M, Grasso S, Sarro GBD. Relationship between Structure and Convulsant Properties of Some b-Lactam Antibiotics following Intracerebroventricular Micro injection in Rats. *Antimicrobial agents and Chemotherapy.* 1995;39(1):232–7. <https://doi.org/10.1128/AAC.39.1.232>
21. Atli O, Demir-Ozkay U, Ilgin S, Aydin TH, Akbulut EN, Sener E. Evidence for neurotoxicity associated with amoxicillin in juvenile rats. *Human and Experimental Toxicology.* 2015;1–11. <https://doi.org/10.1016/j.toxlet.2015.08.784>
22. Bhaskar RK, Kurup GM. Biochemical marker studies of acute drug induced liver injury in rat. *Journal of Technological Advances & Scientific Research.* 2015;1(4):332-7
24. Gayam V, Khalid M, Shrestha B, Hossain MR, Dahal S, Garlapati P, et al. Drug-Induced Liver Injury: An Institutional Case Series and Review of Literature. *Journal of Investigative Medicine High Impact Case Reports.* 2018;(6): 1–7. <https://doi.org/10.1177/2324709618761754>
25. Jordan T, Gonzalez M, Casado M, Suarez JF. Amoxicillin clavulanic acid induced hepatotoxicity with progression to cirrhosis. *Gastroenterol Hepatol.* 2002;25(4):240-3.

Citation: Paudel S, Aryal B, Ranabhat A. Amoxicillin Induced Behavioral Neurotoxicity and Histopathological Changes in The Organs of Albino Rats. *JCMS Nepal.* 2020; 16(1):12-6.