

Cellular Alterations of Oral Mucosa in Tobacco Smokers Undergoing Fixed Orthodontic Treatment: A Cytomorphometric Study

Vinay Marla,¹ Dharanidhar Baral,² Prabhat Ranjan Pokharel,³ Ashish Shrestha,⁴ Rajesh Gyawali,³ Jamal Giri,³

¹Department of Oral Pathology, Penang International Dental College, Penang, Malaysia, ²Department of Community Medicine, BP Koirala Institute of Health Sciences, Dharan, Nepal, ³Department of Orthodontics, BP Koirala Institute of Health Sciences, Dharan, Nepal, ⁴Department of Oral Pathology, BP Koirala Institute of Health Sciences, Dharan, Nepal.

ABSTRACT

Background: Fixed orthodontic treatment causes chronic low grade irritation on the oral mucosa. Tobacco smoking is considered to be a risk factor in the development of oral cancer. This study involves a cytomorphometric analysis on the buccal mucosal cells in patients undergoing fixed orthodontic treatment who are tobacco smokers. **Methods:** Exfoliated buccal mucosal cells were obtained from orthodontic patients (smokers [n=30] and non-smokers [n=30]) as well as smokers [n=30] and non-smokers [n=30] who are not undergoing any orthodontic treatment. Smears were stained with rapid PAP stain and digital images of 50 consecutive cells were analysed using the Image J software. **Results:** Statistical analysis revealed that there was significant increase in the values of nuclear and cell diameter between non-smokers undergoing orthodontic treatment and smokers ($p<0.001$ and $p=0.014$ respectively), and between non-smokers undergoing orthodontic treatment and smokers undergoing orthodontic treatment ($p<0.001$ and $p=0.015$ respectively). Also, nuclear area showed significant differences between healthy non-smokers and orthodontic patients who are non-smokers [$p<0.001$]; healthy non-smokers and smokers [$p=0.002$]; orthodontic patients who are non-smokers and healthy smokers [$p<0.001$]; orthodontic patients who are non-smokers and orthodontic patients who are smokers [$p<0.001$]. The cell area also showed significant differences between healthy non-smokers and orthodontic patients who are non-smokers [$p<0.001$]; orthodontic patients who are non-smokers and healthy smokers [$p=0.001$]; orthodontic patients who are non-smokers and orthodontic patients who are smokers [$p=0.001$]. **Conclusions:** There are nuclear and cellular alterations in patients undergoing fixed orthodontic treatment who are smokers.

Keywords: cytomorphometry; fixed orthodontic treatment; tobacco smoking.

INTRODUCTION

A large number of individuals undergo orthodontic treatment these days with the aim of improving their facial appearance. The treatment includes correction of malocclusion using different types of brackets and wires which are attached onto the tooth surfaces.¹ Fixed orthodontic treatment is a time consuming procedure and lasts for over a year or so in most cases.² The bands and brackets which are bonded on to the tooth surface cause consistent friction with the buccal and labial mucosa resulting in ulcerations and pain.³ There are only few studies in the available literature which describes the effects of these orthodontic appliances on the oral mucosal cells.⁴⁻⁷ Chronic irritation has been considered as a predisposing factor for premalignant and malignant conditions.⁸ Current literature suggests the association of chronic irritation mainly from faulty dentures in causation of malignancy.⁹ Chronic irritation has been considered to be a promoter of carcinogenesis according to the multistage model wherein tobacco and alcohol can be considered as initiators.^{8,10} Few articles have also indicated the effects of sharp

tooth, edentulousness and para-functional habits in causing deleterious effects on the oral mucosa.^{8,9,11} The irritation of oral mucosa during orthodontic treatment needs attention in this regard. Worldwide, tobacco use is a leading cause of deaths amounting to above five million per year, and based on the current scenario it can be assumed that tobacco usage would cause around ten million cases of mortality annually by the year 2030.¹² Cigarettes contain numerous carcinogenic substances, which have toxic effects on the DNA. It is common knowledge that these substances have the potential to cause mutations in genes, abnormalities of the chromosome and even formation of micro-nuclei.¹³ Tobacco smoking can cause carcinoma in different parts of the oral cavity, including the labial mucosa, tongue, palatal mucosa, gingiva, and the buccal mucosa.¹⁴ The habit of smoking is generally picked up at a younger age mainly due to peer pressure and as a result of stress encountered due to social or professional life pressures.¹⁵ The effect of smoking in patients undergoing fixed orthodontic treatment

Correspondence: Dr. Vinay Marla, Department of Oral Pathology, Penang International Dental College, NB Tower, Jalan Bagan Luar, Butterworth, Penang-12100, Malaysia. **Email:** vinaymarla85@hotmail.com. **Phone:** +60-17-4157599. **Article received:** 2019-02-05. **Article accepted:** 2019-07-04.

has not been described in existing literature. Persistent irritation of the oral mucosa due to the brackets and wires used for orthodontic correction combined with the already known effects of tobacco smoke could have grave consequences. There are no studies in the indexed literature evaluating the effects of tobacco smoking on the cells of the buccal mucosa in patients undergoing fixed orthodontic treatment. This study was hence conducted to evaluate the cytomorphometric alterations in oral buccal mucosal cells in tobacco smokers who are undergoing fixed orthodontic treatment.

METHODS

This study was conducted after obtaining ethical approval from the Nepal Health Research Council (NHRC) and was designed in accordance to the guidelines laid down by the Helsinki Declaration.¹⁶ The study included 4 groups namely: Group 1 (Negative control) – Healthy individuals not undergoing any orthodontic treatment and who are not smokers (Patients seeking orthodontic consultation/ oral prophylaxis were selected); Group 2 (Positive control) – Healthy adults undergoing orthodontic treatment who are non-smokers; Group 3 - (Healthy adult smokers who are not undergoing orthodontic treatment) and Group 4 (Study group) – Healthy adults undergoing orthodontic treatment and who have smoking habit for at least 6 months. In group 2 and group 4, patients who underwent at least 6 months of orthodontic treatment were included. Stainless steel brackets were used in both the groups, elastomeric rings as well as stainless steel ligature wires were used for bracket ligation. Nickel-Titanium (Niti) arch wires were used initially followed by stainless steel wires. Convenience sampling technique was applied and 30 individuals who were between the age group of 18-30 years were selected for each of the groups. Individuals who were alcoholics, denture wearers, tobacco chewers; with any systemic or debilitating diseases and with premalignant or malignant lesions were excluded from the study. The oral buccal mucosal cells were obtained after taking written informed consent from the participants. The slides were coded by one of the investigators who did not participate for slide analysis to ensure blinding of the study samples. The participant was instructed to rinse his/her mouth with water following which the mucosal cells were scraped from the right buccal mucosa using a sterile wooden tongue depressor. Smears were prepared on a clean microscopic glass slide and immediately fixed using a spray fixative. The slides were then stained with Rapid

Papanicolaou stain following the guidelines of the manufacturer. The slides were then analysed for adequacy of the smear and staining characteristics using a binocular light microscope. For cytomorphometric analysis, digital images of 50 cells per smear were obtained using a digital camera at 400x magnification. Digital image of the graduated markings of a stage micro-meter were also obtained. The images were then transferred to a computer and were analysed using the Image J software (National Institute of Health, USA). The parameters that were evaluated included: nuclear diameter (ND), cell diameter (CD), nuclear diameter to cell diameter ratio (ND:CD), nuclear area (NA), cell area (CA) and nuclear area to cell area ratio (NA:CA). The data were entered in Microsoft excel sheet (2003) and then statistical analysis was done using SPSS software version 11. A 95% confidence interval was used to interpret the findings of this study. For all the test findings, a p value ≤ 0.05 was considered to be significant.

RESULTS

The study was done on four different groups which included a total of 67 males and 53 females. The

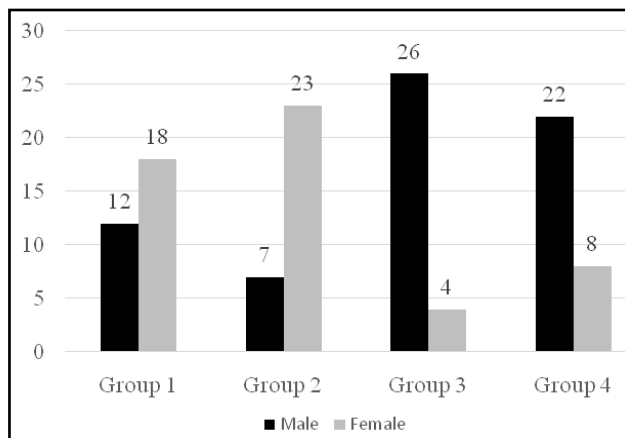


Figure 1. Distribution of males and females in different study groups.

gender breakdown within each group (Figure 1). The data within the four groups were analysed for Normality of distribution using the Kolmogorov-Smirnov test. It was observed that the values of ND, CD and ND:CD ratio showed normal distribution whereas the values of nuclear area, cell area and NA:CA ratio did not. So, One-way analysis of variance followed by Tukey test was done to compare ND, CD and ND:CD ratio among the groups. It was observed that there was a significant difference in the values of ND and CD among the four study groups (Table 1).

Table 1. Comparison of ND, CD and ND:CD among all groups using ANOVA.

Group	Mean ND(μ)	Std. Dev.	p	Mean CD(μ)	Std. Dev.	p	Mean ND:CD	Std dev.	p
1	8.9031	0.9213	<0.001	55.9316	5.1715	0.008	0.1628	0.0179	0.428
2	8.1227	1.2982		50.3939	8.5791		0.1659	0.0133	
3	9.4529	0.8961		58.0064	11.573		0.1689	0.0199	
4	9.48	1.649		57.9288	11.5588		0.1695	0.0179	

The values of ratio of nuclear diameter to cell diameter did not show any statistically significant difference. Further, Tukey test was used for comparing the values of ND, CD and ND:CD among the various groups. Group-wise comparison of the values of ND, CD and ND:CD ratio (Table 2).

tobacco related habits caused an increase in the nuclear diameter and the nuclear-cytoplasmic ratio which showed successive progression from normal mucosa to oral squamous cell carcinoma. Similarly, Goregen et. al.¹⁸ also observed an increase in the nuclear diameter and suggested that these could be dysplastic changes. According to Acharya S et al.,¹⁹

Table 2. Tukey test for comparison of ND,CD and ND:CD between individual groups.

Groups Compared	Nuclear Diameter		Cell Diameter		ND:CD ratio		
	Mean Diff(m)	p value	Mean Diff(m)	p value	Mean Diff	p value	
Group 1	Group 2	0.7803	0.072	5.5378	0.12	-0.0031	0.901
	Group 3	-0.5498	0.313	-2.0747	0.836	-0.006	0.536
	Group 4	-0.5769	0.271	-1.9971	0.851	-0.0066	0.448
Group 2	Group3	-1.3302	<0.001	-7.6125	0.014	-0.0029	0.914
	Group 4	-1.3572	<0.001	-7.5349	0.015	-0.0035	0.855
Group 3	Group 4	-0.027	1	0.0776	1	-0.0006	0.999

Values of NA, CA and NA:CA ratio were compared among the groups by using Kruskal-Walis test (Table 3).

Table 3. Comparison of NA, CA and NA:CA among all groups using Kruskal-Walis test.

Variable	Group 1	Group 2	Group 3	Group 4	p Value
NA(m ²)	68.21	56.822	77.798	71.644	<0.001
CA (m ²)	2565.002	2064.41	2502.27	2731.17	<0.001
NA:CA	0.029	0.029	0.032	0.03	0.072

Statistically significant differences were observed for values of nuclear area and cell area among the various study groups (p<0.001). For comparison of the above variables in between each group, Mann Whitney U test was performed. Differences were observed in the NA:CA ratio between group 1 and 3; and between group 1 and 4. Group-wise comparison of these parameters (Table 4).

who observed the cytomorphometric changes in tobacco chewers and oral squamous cell carcinoma patients, chewers showed an increase in nuclear diameter as compared to normal but were less than those observed in oral squamous cell carcinoma patients. There are only limited studies in the literature which have evaluated the effects of orthodontic treatment on oral mucosa and none of these studies have evaluated the nuclear diameter. So direct comparison of the findings of this study with existing studies is not possible. The increase in cell diameter could be suggestive of increase in the cellular organelles which could in turn reflect the increased keratinization observed as an adaptation of the mucosa in such individuals. No significant differences were observed between smokers-only group [Group 3]and orthodontic smokers [Group 4]. This could due to the fact that both these groups

Table 4. Mann Whitney U test for comparison on NA, CA, NA:CA between each groups.

Groups Compared	Nuclear Area [NA] (m ²)		Cell Area [CA] (m2)		NA:CA Ratio		
	Z value	p value	Z value	p value	Z value	p value	
Group 1	Group 2	-3.8	<0.001	-3.844	<0.001	-0.813	0.416
	Group 3	-3.149	0.002	-0.089	0.929	-2.099	0.036
	Group 4	-0.976	0.329	-0.813	0.416	-2.144	0.032
Group 2	Group 3	-5.263	<0.001	-3.341	0.001	-1.493	0.135
	Group 4	-3.563	<0.001	-3.312	0.001	-1.315	0.188
Group 3	Group 4	-1.375	0.169	-0.651	0.515	-0.636	0.525

DISCUSSION

The nuclear diameter was compared among the four groups and it was observed that there was a significant difference [p<0.01] in the values of the average ND among the groups. Group-wise comparison revealed that even though the nuclear and cell diameter decreased from normal individuals [group 1] to orthodontic patients without any smoking habit [group 2] and increased from normal individuals to only smokers [group 3], and between normal individuals and orthodontic patients who are smokers [group 4]; these differences were not significant. According to a study done by Hande et. al.,¹⁷ it was observed that

[i.e. Group 3 and Group 4] included smokers and the results obtained were similar. With regards to the comparison of nuclear area, cell area and NA:CA ratio, it was observed that both the values of nuclear area and cell area showed significant differences [p<0.001 for both NA and CA] among the four study groups [Table 3]. The values of NA:CA ratio did not show any significant differences. The nuclear area was further compared [Table 4] for differences between each of the groups and it was observed that there was a significant reduction in the value of nuclear area from normal individuals to individuals who are undergoing orthodontic treatment [p<0.001] and

significant increase from normal to smokers-only group [p=0.002]. The cellular area [Table 4] showed significant reduction between normal and orthodontic patients but unlike nuclear area, no significant differences were observed between normal individuals and the two groups constituting tobacco smokers. The reduction of nuclear area in orthodontic patients is suggestive of atrophic changes in the oral mucosal cells. These findings showed correlation with the findings of the study conducted by de Arruda et al. and Rafighi et al. who also observed a reduction in the nuclear area in individuals undergoing orthodontic treatment.^{4,5} The findings in relation to smokers were similar to the studies conducted by Ahmed and Babiker,²⁰ who observed increased nuclear area in toombak users. Goregen et. al.¹⁸ suggested that the increase in nuclear area could be indicative of dysplasia. Ableadaziz and Osman,²¹ suggested that smokers showed increased frequency of atypical cytological changes and should be considered to be risk factors for oral carcinoma. In the present study, there was an increase in nuclear area between normal individuals and orthodontic smokers, however these were not significant. Comparison [Table 4] between orthodontic patients [group 2] and the two smoker groups [group 3 and 4] suggested that there was a significant increase in nuclear area between group 2 and group 3 [p<0.001]; and between group 2 and group 4 [p<0.001]. Finally, no significant differences were observed between group 3 and group 4 for the values of nuclear area. No previous data were available for comparison of combined effects of smoking and fixed orthodontic treatment. In terms of cell area, contrasting results were obtained by Mei et. al.,⁶ who suggested that the cytoplasmic area showed an increase in oral mucosal cells adjacent to orthodontic brackets. However, this was suggested to be an adaptive

response of the oral buccal mucosal cells to orthodontic brackets since the sample were collected one month after placement of brackets and showed a return to baseline values after removal of brackets. Similarly, Pereira et. al.⁷ also observed an increase in cell area two months after placement of orthodontic brackets. Both the above mentioned studies involved experimental application of few brackets in normal individuals over a short period of time. The present study involved collection of samples from actual orthodontic patients, at least 6 months after initiation of the treatment. Based on the above observations, it can be suggested that there are nuclear and cellular alterations in smokers undergoing fixed orthodontic treatment.

CONCLUSIONS

Based on the findings of this study, it can be concluded that there are nuclear and cellular alterations in oral buccal mucosal cells due to tobacco smoking. However, these changes are not significantly altered by the presence of orthodontic appliances among smokers. The changes occurring due to the presence of orthodontic appliances only can be considered as adaptive responses.

ACKNOWLEDGEMENTS

The authors would like to thank the participants for their co-operation in this study. We would also like to add a note and thank Dr. Varun Pratap Singh (MDS, Orthodontics; PhD) for his constant guidance and support throughout the course of this study.

Conflict of interest: The authors declare that they have no conflict of interest in the publication of this manuscript.

REFERENCES

1. Chen Q, Zheng X, Chen W, Ni Z, Zhou Y. Influence of orthodontic treatment with fixed appliances on enamel color: a systematic review. *BMC Oral Health*, 2015; 15:31.
2. Fink DF, Smith RJ. The duration of orthodontic treatment. *Am J Orthod Dentofacial Orthop.*, 1992; 102(1): 45-51.
3. Impellizzeri A, Palaia G, Carpenteri F, Mohsen M, Romeo U, Galluccio G. Secondary problems of oral mucosa during orthodontic treatment. *Prevention and Research*, 2014; Online 28 Feb: 65.
4. de Arruda EP, Trevilatto PC, Camargo ES, Woyceichoski IEC, Machado MAN, Vieira I, de Lima AAS. Preclinical alterations of oral epithelial cells in contact with orthodontic appliances. *Biomed Pap Med Fac Univ Palacký Olomouc Czech Repub.* 2011; 155(3): 299-303.
5. Rafighi A, Sohrabi A, Moghaddam SF, Moslemzadeh SH. Effect of orthodontic fixed appliances on epithelial cells of lower lip oral mucosa during orthodontic treatment. *Iranian Journal of Orthodontics*, 2012; 7: 44-48.
6. Mei SM, Soares de Lima AA, Filho JB, Tanaka OM, Filho OG, Camargo ES. A cytological analysis of the oral mucosa adjacent to orthodontic devices. *European J Gen Dent.*, 2013; 2(2): 119-123.
7. Pereira BR, Tanaka OM, Lima AAS, Filho OG, Maruo H, Camargo ES. Metal and ceramic bracket effects on human buccal mucosa epithelial cells. *Angle Orthod.*, 2008; 79(2): 373-379.
8. Piemonte ED, Lazos JP, Brunotto M. Relationship between chronic trauma of the oral mucosa, oral potentially malignant disorders and oral cancer. *J Oral Pathol Med.*, 2010; 39: 513-517.

9. Patil S, Doni B, Maheshwari S. Prevalence and Distribution of Oral Mucosal Lesions in a Geriatric Indian Population. *Can Geriatr J.*, 2015; 18(1):11-14.
10. Park BJ, Chiosea SI, Grandis JR. Molecular changes in the multistage pathogenesis of head and neck cancer. *Cancer biomark.* 2010; 9(1-6): 325-339.
11. Fan H, Yoon K-Y, Kim S-M, Myoung H, Lee J-H, Kim M-J. Relationship between squamous cell carcinoma of the tongue and the position of dental prosthesis. *J Adv Prosthodont.*, 2015;7(2):129-137. doi:10.4047/jap.2015.7.2.129.
12. Jha P, Chaloupka FJ, Moore J, et al. Tobacco Addiction. In: Jamison DT, Breman JG, Measham AR, et al., editors. *Disease Control Priorities in Developing Countries*. 2nd edition. Washington (DC): The International Bank for Reconstruction and Development / The World Bank; 2006. Chapter 46.
13. Nefic H, Musanovic J, Kurteshi K, Prutina E, Turcalo E. The effect of sex, age and cigarette smoking on micro-nucleus and degenerative nuclear alteration frequencies in human buccal cells of healthy Bosnian subjects. *Journal of Health Sciences*, 2013; 3(3): 196-204.
14. Kamath VV, Anigol P, Setlur K. Micronuclei as prognostic indicators in oral cytological smears: A comparison between smokers and non smokers. *Clin Cancer Investig J.*, 2014; 3(1):49-54.
15. Hashmi S. Adolescence: An age of storm and stress. *Review of Arts and Humanities*, 2013;2(1): 19-33.
16. World Medical Association. Declaration of Helsinki—ethical principles for medical research involving human subjects. 2008.
17. Hande AH, Chaudhary MS. Cytomorphometric analysis of buccal mucosa of tobacco chewers. *Rom J Morphol Embryol.*, 2010; 51(3): 527-532.
18. Goregen M, Akgul HM, Gundogdu C. The cytomorphological analysis of buccal mucosa cells in smokers. *Turk J Med Sci.*, 2011; 41(2): 205-210.
19. Acharya S, Tayaar AS, Khwaja T. Cytomorphometric analysis of the keratinocytes obtained from clinically normal buccal mucosa in chronic gutkha chewers. *Journal of Cranio-Maxillary Diseases*, 2013; 2(2): 134-141.
20. Ahmed HG, Babiker A-EA. Assessment of cytological atypia, AgNOR and nuclear area in epithelial cells of normal oral mucosa exposed to toombak and smoking. *Rare Tumors*. 2009; 1(1)
21. Abledaziz MS and Osman TE. Detection of cytomorphological changes in oral mucosa among alcoholics and cigarette smokers. *Oman Med J.*, 2011; 26(5): 349-52.

Citation: Marala V, Baral D, Pokharel PR, Shrestha A, Gyawali R, Giri J. Cellular Alterations of the Oral Mucosa in Tobacco Smokers Undergoing Fixed Orthodontic Treatment: A Cytomorphometric Study. *JCMS Nepal*. 2019; 15(3):206-10.