

Choledochal Cyst: Their clinical presentation, diagnosis and treatment in central Nepal: a retrospective study

Sujit Kumar, Aditya Jalan, Bhupendra Nath Patowary

Department of General surgery and Gastroenterology, College of Medical Sciences, Bharatpur, Nepal

Correspondence

Dr. Sujit Kumar
Department of General surgery
and Gastroenterology, College of
Medical Sciences, Bharatpur,
Nepal

Email: drsujit1755@gmail.com

DOI: <http://dx.doi.org/10.3126/jcmsn.v13i1.16667>

Article received: Dec⁵th 2016

Article accepted: Jan 22nd 2017

ABSTRACT

Background & Objectives: Choledochal cyst is a rare congenital malformation involving the cystic dilatation of intrahepatic and/ or extra-hepatic bile duct. The estimated incidence is one in 1000 live birth in Asian population with female to male ratio 3:1. The objective of the study was to study the presentation, diagnosis, treatment and outcome of choledochal cyst in College of Medical Sciences, Bharatpur, Nepal

Materials & Methods: A retrospective review of the records of all the patients who were diagnosed as choledochal cyst and underwent medical or operative intervention in our hospital from January 2013-January 2015. **Results:** We analyzed ten cases of choledochal cyst. The condition commonly affected the age group of six to ten years with female preponderance (70%). Most common presenting symptom was pain abdomen (100%) and jaundice (50%). However classical triad of abdominal pain, jaundice, and an abdominal mass was not seen in any of the cases. Ultrasonography was diagnostic in all cases. Todani type I cyst was the most common type. Nine out of ten cases underwent complete cyst excision with cholecystectomy and Roux-en-Y hepaticojejunostomy without any major complication. **Conclusion:** Choledochal cyst is a clinical condition that is conveniently diagnosed on ultrasound and has a rewarding outcome if operated

Key words: Choledochal cyst; Ultrasonography; Roux-en-y hepaticojejunostomy

Citation: Kumar S, Jalan A, Patowary BN. Choledochal Cyst: Their clinical presentation, diagnosis and treatment in central Nepal: a retrospective study. *JCMS Nepal*. 2017;13(1):207-11.

INTRODUCTION

Choledochal cyst is a cystic dilatation of the extra hepatic and/or intrahepatic bile duct¹ with an incidence of 1:1000 in Asian population.²⁻⁴ It has female preponderance and female: male ratio is 3:1.⁵ Todani Type I cysts are the most common type and account for approximately 75% of patients.⁶ The most accepted theory in pathogenesis of choledochal cyst is Babbitt's theory is associated with anomalous pancreaticobiliary duct junction (APBDJ).^{7,8} Patients may present at any age with pain abdomen, jaundice and a right upper quadrant mass, however, 60% of cases are diagnosed before the age of ten years.⁶ The main diagnostic tool for detection of a choledochal cyst, in childhood, is

ultrasonography.^{9, 10} Ultrasonography will confirm the presence of an abnormal cyst and magnetic resonance cholangiopancreatography (MRCP) will reveal the anatomy.⁶ Complete cyst excision with cholecystectomy followed by biliary reconstruction using Roux-en-Y hepaticojejunostomy is the treatment of choice for the extra hepatic component of the disease (type I and type IV Choledochal cyst). In type V choledochal cyst (Caroli's disease), liver resection or liver transplantation is indicated.^{11, 12} In this article we mentioned about our experience with choledochal cyst disease and discuss about its clinical presentation, diagnosis and treatment. The study was conducted with objective of analysing the presentation, diagnosis and treatment of

choledochal cyst in central Nepal; a tertiary care center, College of Medical Sciences, Bharatpur, Nepal.

MATERIALS AND METHODS

This was a retrospective review of all the records of the patients who were diagnosed as choledochal cyst and underwent medical and operative intervention at College of Medical Sciences, Bharatpur, Nepal from January 2013 to January 2015. Baseline investigations which include complete hemogram, urine examination, liver function tests, renal function tests and coagulation profile were recorded. Data regarding the clinical presentation, investigation, surgery, and follow-up were retrieved and analyzed. The type of cyst was classified according to the Todani classification. The cases are in follow up every three months in the first year, then every six months for next two years and yearly thereafter. Statistical analysis was done by SPSS 20. Numerical data were presented as mean \pm standard deviation.

RESULTS

From January 2013 to January 2015, a total number of ten patients were treated for choledochal cyst. Female: male ratio was 2.33:1. The mean age of presentation was 10.10 ± 8.04 years. The most common age group was between six to ten years.

Pain abdomen was the most common presenting symptom (n=10,100%) followed by jaundice (n=5, 50 %) and cholangitis (n=5, 50%). Nine patients had pain only in upper abdomen while one female child (three years of age) that presented with features of biliary peritonitis due to spontaneous rupture of the choledochal cyst. None of the case in this series presented with the classical triad of pain abdomen, jaundice and mass per abdomen. Features of weight loss and anorexia were only present in one patient of Caroli's disease.

Serum alkaline phosphatase (ALP) was more than 300 U/L in all ten (100%) cases, raised serum bilirubin ($>2\text{gm/dl}$) was seen in five (50%) cases and leukocytosis was seen in six (60%) cases. We found Todani type I cyst in nine (90%) cases and type V cyst (Caroli's disease) in one (10%) case. Ultrasonography of abdomen followed by contrast enhanced computed tomography (CECT) abdomen was used to make diagnosis of the cyst.

Eight patients were operated through right sub-costal incision with complete excision of cyst with cholecystectomy followed by biliary reconstruction using Roux-en-Y hepaticojejunostomy (Figure 1

and Figure 2). One child (three year old female) was operated through upper midline incision with biliary drainage in addition to complete cyst excision with cholecystectomy followed by biliary reconstruction using Roux-en-Y hepaticojejunostomy (Figure 3). The patient with Caroli's disease was managed conservatively and was referred to higher center for liver resection or liver transplantation. The early postoperative outcome was uneventful in all of operated patients except superficial surgical site infection in two out of nine operated cases. None of them developed pancreatitis, anastomotic leak or recurrent cholangitis. The mean duration of hospital stay was 7.7 ± 1.2 days. There was no perioperative mortality. The histopathology of excised cyst was reported as choledochal cyst in all operated cases. Evidence of anastomotic strictures or malignant transformation was not found in any of the patients in follow-up till now. All the patients are still in follow up as per the protocol.

DISCUSSION

Choledochal malformation is characterized by dilatation of the biliary tract in the absence of acute obstruction to the bile flow. Those of these malformations with cystic dilatation constitute the choledochal cyst.^{11,13} It was first described by Vater and Ezler in 1723.¹⁴ According to Kumar and Rajagopalan (2012)¹⁵ 85% cases are diagnosed before puberty. Similarly in our series also, 90% of the cases presented below the 15 years of age. Various authors mentioned the female: male ratio ranging from 3: 1 to 4:1.^{2,5} In our series also female preponderance was seen and female: male ratio was 2.33:1.

Lipsett et al.¹⁶ reported the classic triad of pain abdomen, jaundice and palpable abdominal mass is seen in less than 20% of the cases. However, in our study none of the patients presented with classical triad of choledochal cystic disease. Lipsett et al.¹⁶ and Jesudason SR¹⁷ mentioned abdominal pain is most common symptom among pediatric and adult patients. According to Singham¹⁸, abdominal pain in pediatric and adult patients has an incidence ranging from 78% to 90%, jaundice and cholangitis being in 40 to 50%. Similarly, in our study abdominal pain was present in all 100% of the cases, jaundice was seen in 50 % and cholangitis in 50 % of the cases. Treem¹⁹ mentioned the incidence of spontaneous rupture of choledochal cyst was 1.8 to 2.8% whereas in our study it was 10%. This high incidence seen in our study may be due to small study sample.

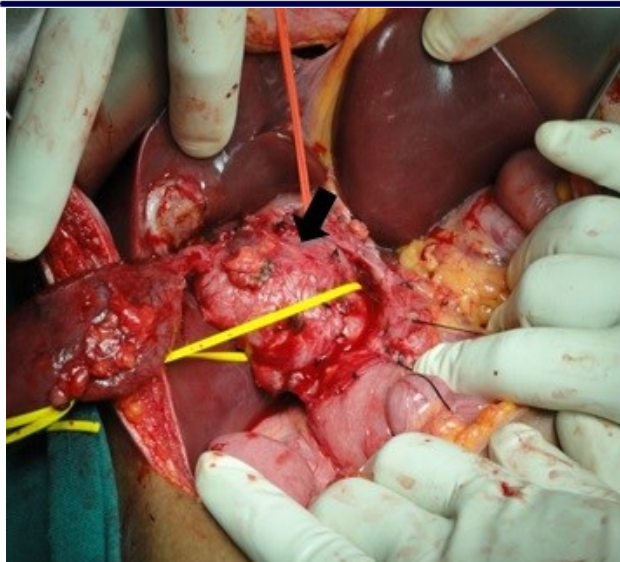


Figure 1: The arrow head shows the fusiform dilatation of common bile duct choledochal cyst type I

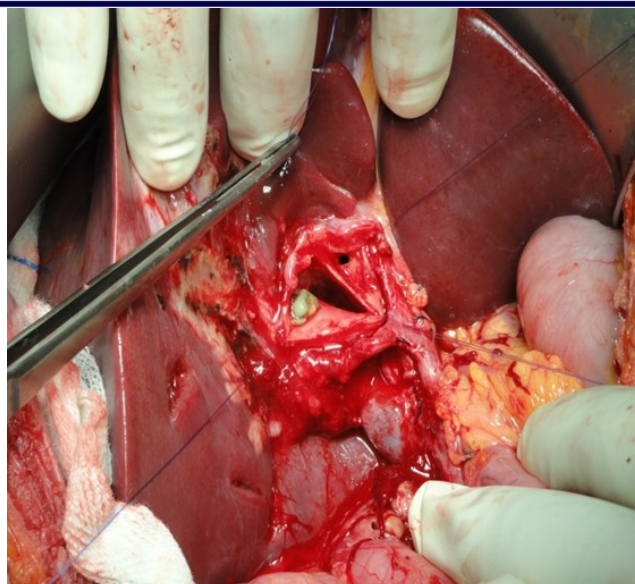

Figure 3: Perforated choledochal cyst in 3yr female child who presented with biliary peritonitis

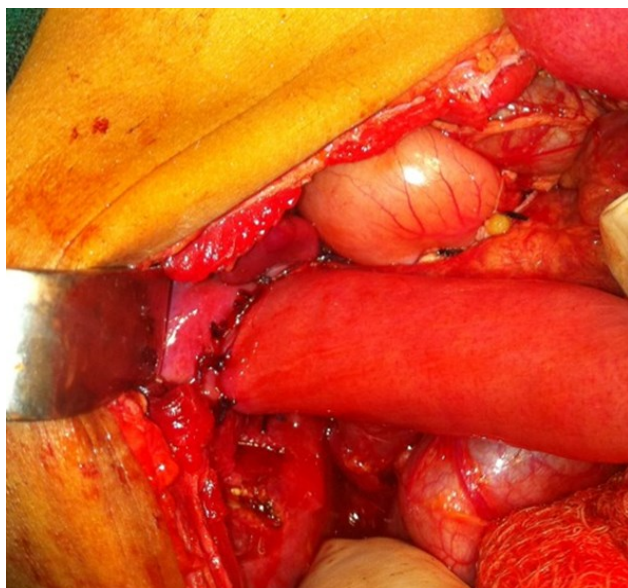


Figure 2: Hepaticojejunostomy after excision of choledochal cyst

According to Kumar and Rajagopalan¹⁵ 15% of the patients may have features of hepatic changes of cirrhosis, pancreatitis or choledocholithiasis while in the present study none of the patients presented with cirrhosis, pancreatitis or choledocholithiasis. Ultrasonography (USG) is usually the first examination and is a very sensitive (71 to 97%) in the detection of choledochal cyst.^{9,18} A properly performed high resolution USG is the best screening test.²⁰ Le et al²¹ described 38 cases of choledochal cyst where in all cases USG was the only diagnostic modality. Similarly, in our study

USG is main diagnostic tool. Though CECT abdomen was done in all cases, findings were similar to USG. So we found USG as sensitive as CECT abdomen for the diagnosis of choledochal cyst. Studies showed CECT abdomen are useful in showing continuity of the cyst with the biliary tree, its relation to surrounding structures and the presence of associated malignancy. It is superior to USG in imaging the intrahepatic bile ducts, distal bile duct and pancreatic head. In patients with type-IVA cysts and Caroli's disease; it is useful to delineate the intrahepatic dilations and the extent of disease such as diffuse hepatic involvement versus localized segmental involvement. Some authors recommend spiral computed tomography to differentiate malignant cyst wall changes from reactive inflammation.²²

Other imaging modalities like Endoscopic Retrograde Cholangiopancreatography (ERCP) or MRCP can precisely visualize the extra hepatic bile duct.⁹ MRCP has been advocated as the ideal and non-invasive complete diagnostic modality for choledochal cyst as it ensures accurate visualization of the entire pancreatobiliary system.^{21,23} These investigations could not be done in any of the patients due to lack of these facilities at our center at that time.

Alonso-Lej et al.²⁴ described Choledochal cysts into Type I to type III. Later Todani et al.⁷ modified it by adding type IV and V. Type I choledochal cysts make up about 50 to 80% of all choledochal cysts, type II 2%, type III 1.4 to 4.5%, type IV 15 to 35%,

and type V 20%. Whereas in our series we detected only two types of choledochal cyst, Type I in 90% of cases and type V in 10% of the cases. Type I cysts consist of saccular or fusiform dilatation of the extrahepatic bile duct. Type II choledochal cysts are saccular diverticulum of the common bile duct (CBD). Type III choledochal cysts also termed choledochoceles, represents cystic dilation of intramural portion of distal CBD with bulge into the duodenum. Type IV choledochal cysts are further sub classified into type IVA and type IVB. Type IVA is the second most common choledochal cysts and is described by both intrahepatic and extra hepatic dilation of biliary ducts. Type IVB represents multiple dilation of extra hepatic biliary tree only. Type V choledochal cysts, also known as Caroli's disease represents multiple dilation of intrahepatic biliary ducts.⁷

Lipsett et al.²⁵ and Cho et al.²⁶ mentioned complete excision of extrahepatic component of choledochal cyst combined with cholecystectomy, followed by Roux-en-Y biliary reconstruction as the treatment of choice for type I and IV choledochal cyst^{14, 25, 5, 35, 36, 46} And depending on cyst type (Todani type IV, V), further intervention may be necessary.²⁷⁻²⁹ Cholecystectomy is carried out due to the high risk of associated gall bladder malignancy.^{30, 31} Likewise among all patients we operated complete cyst excision with cholecystectomy followed by biliary reconstruction using Roux-en-Y hepaticojejunostomy was performed. We recommend the same as the main stay of treatment for choledochal cyst Type I and Type IV. However, in case of extensive intrahepatic dilation with complications, such as stones, cholangitis, or biliary cirrhosis in type IV A, other options, such as hepatic resection in case of unilobar disease and liver transplantation in bilobar disease should be considered.³²

The reported incidence rate of anastomotic stricture following Roux-en-Y hepaticojejunostomy is 4.1%.³³ However, a wide anastomosis between the hepatic hilum and intestine may prevent anastomotic stricture.³⁴ Tao et al.³⁵ suggested minimum diameter of stoma to be three cm and observed 92% success rate with biliary reconstruction. Choledochal cyst associated cholangiocarcinoma following complete cyst excision with cholecystectomy followed by biliary drainage are generally found in 11% of cases.³⁶⁻³⁸ It was not found in any of our patients. This may be due to the fact that the risk of associated

cholangiocarcinoma increases with age, and the average age of our patients was 10 years. However, it is likely that with increased number of patients, the rate of cholangiocarcinoma will meet what is found in the larger population. Similarly, due to the short follow up in this study, patients recently diagnosed and treated for choledochal cyst, it is not possible to evaluate the long term outcomes.

Type II cysts should be excised entirely and in the presence of an APBDJ, biliary enteric diversion by Roux-en-Y hepaticojejunostomy is appropriate. Type III cysts which may not involve APBDJ can be treated with endoscopic drainage, transduodenal excision or sphincteroplasty. Surgical treatment of Caroli's disease type V ranges from resection if the disease is unilobar to liver transplantation when diffuse disease is detected.³⁹

CONCLUSION

Choledochal cysts are congenital anomalies bile duct leading to cystic dilatation of extrahepatic and /or intrahepatic biliary radicles. Most of the cases presented before puberty. Pain abdomen is the most common clinical presentation. However the classical triad of pain abdomen, jaundice and mass per abdomen may not be found. Ultrasonography of abdomen can be used as a single modality for diagnosis of choledochal cyst. Complete cyst excision with cholecystectomy followed by biliary reconstruction using Roux-en-Y hepaticojejunostomy is treatment of choice for type I and Type IV cyst.

REFERENCES

1. Park SW, Koh H, Oh JT, Han SJ, Kim S. Relationship between anomalous pancreaticobiliary ductal union and pathologic inflammation of bile duct in choledochal cyst. *Pediatr Gastroenterol Hepatol Nutr.* 2014;17(3):170-7. DOI: 10.5223/pghn.2014.17.3.170. PMID: 25349833.
2. Bhavsar MS, Vora HB, Giriappa VH. Choledochal cysts : a review of literature. *Saudi J Gastroenterol.* 2012;18(4):230-6. DOI: 10.4103/1319-3767.98425. PMID: 22824764.
3. O'Neill JA, Jr. Choledochal cyst. *Curr Probl Surg.* 1992;29(6):361-410. DOI: 10.1016/0011-3840(92)90025-X.
4. Yamataka A, Kato Y. Operative treatment for choledochal cysts. In: Fisher JE, Jones DB, Pomposelli RG, Upchurch GR, editors. *Fischer's Mastery of Surgery.* 1. New Delhi: Wolters Kluwer India Pvt Ltd; 2012. p. 1336-43. PMID: PMC353793.
5. Liu CL, Fan ST, Lo CM, Lam CM, Poon RT, Wong J. Choledochal cysts in adults. *Arch Surg.* 2002;137(4):465-8. DOI: 10.1001/archsurg.137.4.465. PMID: 11926955.
6. Conlon K. The gallbladder and bile ducts. In: Williams NS, Bulstrode CJK, O'Connell PR, editors. *Bailey and Love's short practice of surgery.* 26th ed. London: Hodder Arnold; 2013. p. 1097-117.
7. Todani T, Watanabe Y, Narusue M, Tabuchi K, Okajima K. Congenital bile duct cysts: classification, operative procedures, and review of thirty-seven cases including

- cancer arising from choledochal cyst. *Am J Surg.* 1977;134(2):263-9. DOI: 10.1016/0002-9610(77)90359-2.
8. Dandpat SK, Prajapati R, Khajanchi M, Satoskar RR. Retrospective study of choledochal cyst: clinical presentation, diagnosis and treatment. *International Journal of Science and Research.* 2014;3(11).
 9. Waidner U, Henne-Bruns D, Buttenschon K. Choledochal cyst as a diagnostic pitfall: a case report. *J Med Case Rep.* 2008;2:5. DOI: 10.1186/1752-1947-2-5. PMID: 18194562.
 10. Kim MJ, Han SJ, Yoon CS, Kim JH, Oh JT, Chung KS, et al. Using MR cholangiopancreatography to reveal anomalous pancreaticobiliary ductal union in infants and children with choledochal cysts. *Am J Roentgenol.* 2002;179(1):209-14. DOI: 10.2214/ajr.179.1.1790209. PMID: 12076938.
 11. Machado NO, Chopra PJ, Al-Zadjali A, Younas S. Choledochal cyst in adults: etiopathogenesis, presentation, management, and outcome-case series and review. *Gastroenterol Res Pract.* 2015;2015:602591. DOI: 10.1155/2015/602591. PMID: 26257778.
 12. Woon CY, Tan YM, Oei CL, Chung AY, Chow PK, Ooi LL. Adult choledochal cysts: an audit of surgical management. *ANZ J Surg.* 2006;76(11):981-6. DOI: 10.1111/j.1445-2197.2006.03915.x. PMID: 17054547.
 13. Turowski C, Knisely AS, Davenport M. Role of pressure and pancreatic reflux in the aetiology of choledochal malformation. *Br J Surg.* 2011;98(9):1319-26. DOI: 10.1002/bjs.7588. PMID:21725969.
 14. Vater A, CS. E. *Dissertatio de Scirrhis viscerum oc-casione sectionis viri tympanite defunte.* Wittenburgae. 881. 1723;22.
 15. Kumar M, Rajagopalan S. Choledochal cyst. *Med J Armed Forces India.* 2012;68(3):296-8. DOI: 10.1016/j.mjafi.2012.04.011. PMID: 2453289.
 16. Lipsett PA, Pitt HA. Surgical treatment of choledochal cysts. *J Hepatobiliary Pancreat Surg.* 2003;10:352-9. DOI: 10.1007/s00534-002-0797-4. PMID: 14598135.
 17. Jesudason SR, Jesudason MR, Mukha RP, Vyas FL, Govil S, Muthusami JC. Management of adult choledochal cysts--a 15-year experience. *HPB (Oxford).* 2006;8(4):299-305. DOI: 10.1080/13651820500466715. PMID: 18333140.
 18. Singham J, Yoshida EM, Scudamore CH. Choledochal cysts: part 1 of 3: classification and pathogenesis. *Can J Surg.* 2009;52(5):434-40. PMID: 19865581.
 19. Treem WR, Hyams JS, McGowan GS, Sziklas J. Spontaneous rupture of a choledochal cyst: clues to diagnosis and etiology. *J Pediatr Gastroenterol Nutr.* 1991;13(3):301-6. DOI: 10.1097/00005176-199110000-00012. PMID: 1791509.
 20. Mishra A, Pant N, Chadha R, Choudhury SR. Choledochal cysts in infancy and childhood. *Indian J Pediatr.* 2007;74(10):937-43. DOI: 10.1007/s12098-007-0173-0. PMID: 17978454.
 21. Le L, Pham AV, Dessanti A. Congenital dilatation of extrahepatic bile ducts in children: experience in the central hospital of Hue, Vietnam. *Eur J Pediatr Surg.* 2006;16(1):24-7. DOI: 10.1055/s-2005-873071. PMID: 16544222.
 22. Lam WW, Lam TP, Saing H, Chan FL, Chan KL. MR cholangiography and CT cholangiography of pediatric patients with choledochal cysts. *AJR Am J Roentgenol.* 1999;173(2):401-5. DOI: 10.2214/ajr.173.2.10430145. PMID: 10430145.
 23. Suzuki M, Shimizu T, Kudo T, Suzuki R, Ohtsuka Y, Yamashiro Y, et al. Usefulness of nonbreath-hold 1-shot magnetic resonance cholangiopancreatography for the evaluation of choledochal cyst in children. *J Pediatr Gastroenterol Nutr.* 2006;42(5):539-44. DOI: 10.1097/01.mpg.0000221894.44124.8e. PMID: 16707978.
 24. Alonso-Lej F, Rever WB, Jr., Pessagno DJ. Congenital choledochal cyst, with a report of 2, and an analysis of 94, cases. *Int Abstr Surg.* 1959;108(1):1-30. PMID: 13625059.
 25. Lipsett PA, Pitt HA, Colombani PM, Boitnott JK, Cameron JL. Choledochal cyst disease: a changing pattern of presentation. *Ann Surg.* 1994;220(5):644-52. DOI: 10.1097/0000658-199411000-00007. PMID: 7979612.
 26. Cho MJ, Hwang S, Lee YJ, Kim KH, Ahn CS, Moon DB, et al. Surgical experience of 204 cases of adult choledochal cyst disease over 14 years. *World J Surg.* 2011;35(5):1094-102. DOI: 10.1007/s00268-011-1009-7. PMID: 21360306.
 27. Tan SS, Tan NC, Ibrahim S, Tay KH. Management of adult choledochal cyst. *Singapore Med J.* 2007;48(6):524-7. PMID: 17538750.
 28. Wiseman K, Buczkowski AK, Chung SW, Francoeur J, Schaeffer D, Scudamore CH. Epidemiology, presentation, diagnosis, and outcomes of choledochal cysts in adults in an urban environment. *Am J Surg.* 2005;189(5):527-31. DOI: 10.1016/j.amjsurg.2005.01.025. PMID: 15862490.
 29. Dhupar R, Gulack B, Geller DA, Marsh JW, Gamblin TC. The changing presentation of choledochal cyst disease: an incidental diagnosis. *HPB Surg.* 2009;2009:103739. DOI: 10.1155/2009/103739. PMID: 19841688.
 30. Babbitt DP. Congenital choledochal cysts: new etiological concept based on anomalous relationships of the common bile duct and pancreatic bulb. *Ann Radiol (Paris).* 1969;12(3):231-40.
 31. Komi N, Tamura T, Miyoshi Y, Kunitomo K, Udaka H, Takehara H. Nationwide survey of cases of choledochal cyst: analysis of coexistent anomalies, complications and surgical treatment in 645 cases. *Surg Gastroenterol.* 1984;3(2):69-73. PMID: 6085899.
 32. Visser BC, Suh I, Way LW, Kang SM. Congenital choledochal cysts in adults. *Arch Surg.* 2004;139(8):855-60; discussion 60-2. DOI: 10.1001/archsurg.139.8.855. PMID: 15302695.
 33. Hata Y, Sasaki F, Takahashi H, Tamura M, Ohkawa Y, Saji Y, et al. Surgical treatment of congenital biliary dilatation associated with pancreaticobiliary maljunction. *Surg Gynecol Obstet.* 1993;176(6):581-7. PMID: 8322133.
 34. Tadokoro HaT, M. . Recent advances in choledochal cysts. *Open Journal of Gastroenterology.* 2012; 2: 145-54. DOI: 10.4236/ojgas.2012.24029.
 35. Tao KS, Lu YG, Wang T, Dou KF. Procedures for congenital choledochal cysts and curative effect analysis in adults. *Hepatobiliary Pancreat Dis Int.* 2002;1(3):442-5. PMID: 14607724.
 36. Stain SC, Guthrie CR, Yellin AE, Donovan AJ. Choledochal cyst in the adult. *Ann Surg.* 1995;222(2):128-33. DOI: 10.1097/0000658-199508000-00004. PMID: 7639580.
 37. de Vries JS, de Vries S, Aronson DC, Bosman DK, Rauws EA, Bosma A, et al. Choledochal cysts: age of presentation, symptoms, and late complications related to Todani's classification. *J Pediatr Surg.* 2002;37(11):1568-73. DOI: 10.1053/jpsu.2002.36186. PMID: 12407541.
 38. Watanabe Y, Toki A, Todani T. Bile duct cancer developed after cyst excision for choledochal cyst. *J Hepatobiliary Pancreat Surg.* 1999;6(3):207-12. DOI: 10.1007/s005340050108. PMID: 1052605.
 39. Patrick G, Jackson S, Evan RT. Biliary system. In: Townsend CM, Beauchamp RD, Evers BM, Mattox KL, editors. *Sabiston's text book of surgery the biological basis of modern surgical practice.* 2. 19 ed. Philadelphia: Elsevier Saunders; 2012. p. 1476-514.